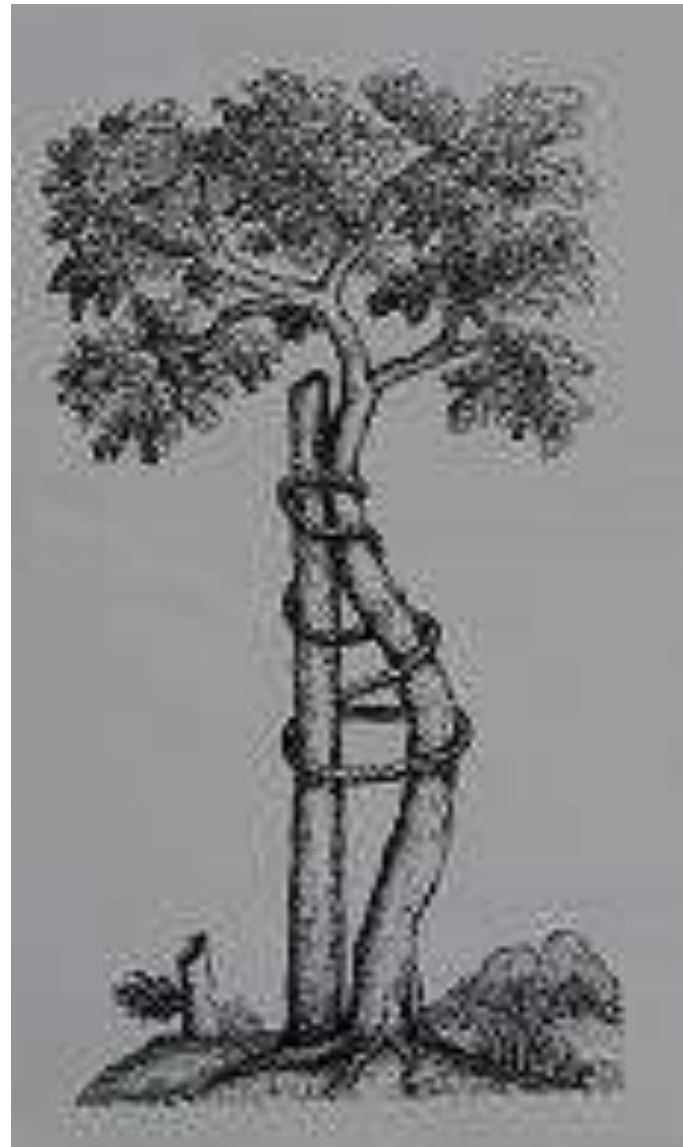

Hrbtenica



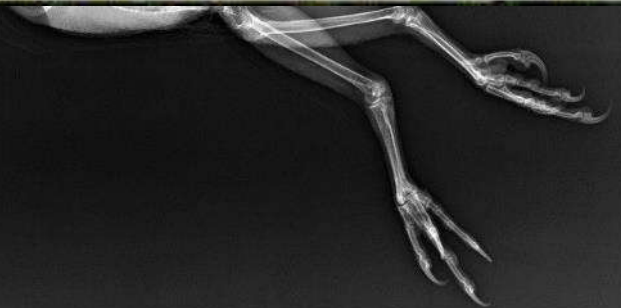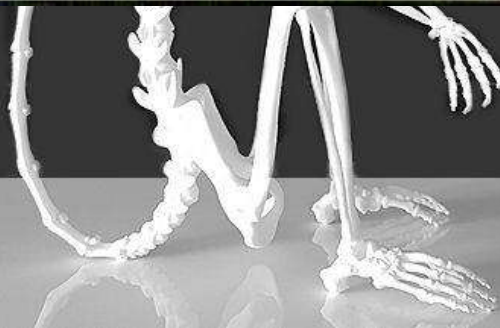

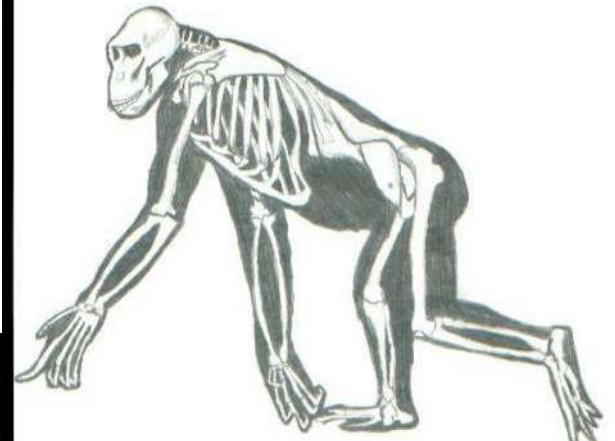
doc. dr. Miha Vodičar, dr. med.

Plan predstavitve

- **Osnovni pregled področja (10 min)**
- Pacient s težavo s hrbtenico (10 min)
- Bolezni hrbtenice (10 min)
- Kirurgija hrbtenice (kaj počnemo?) (10 min)
- V&O (5 min)

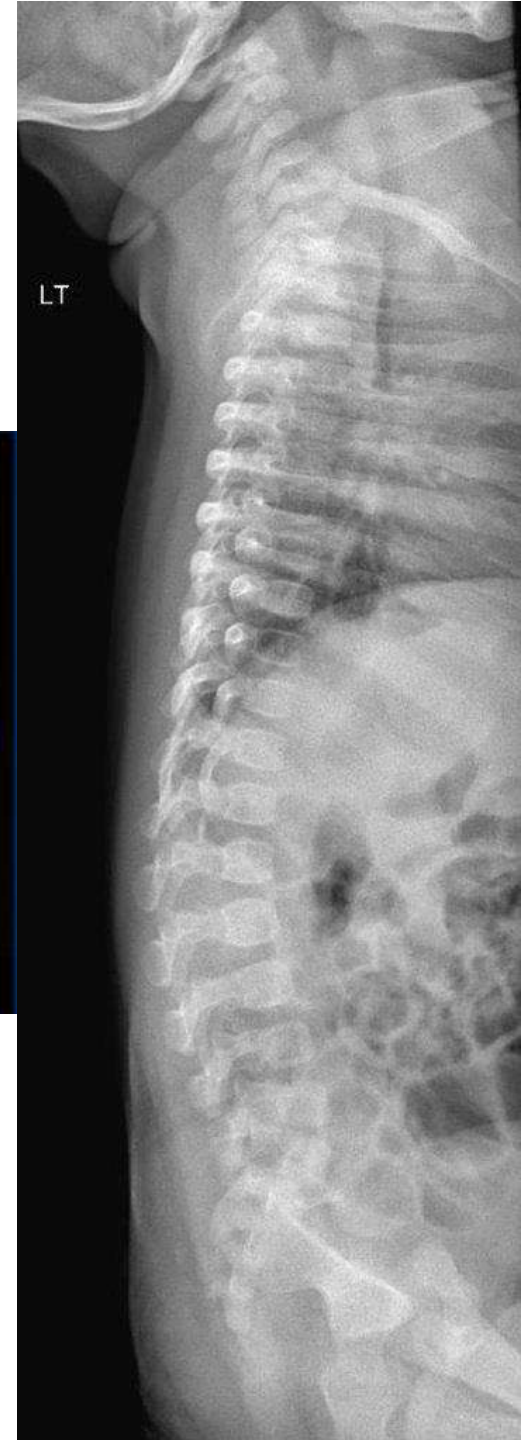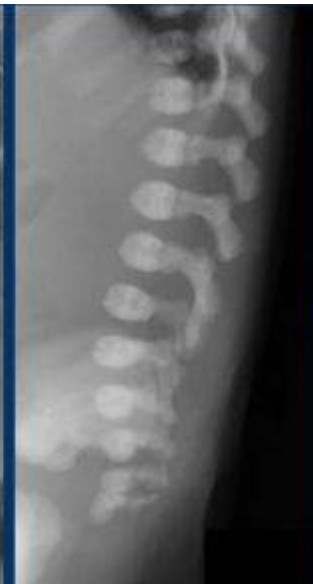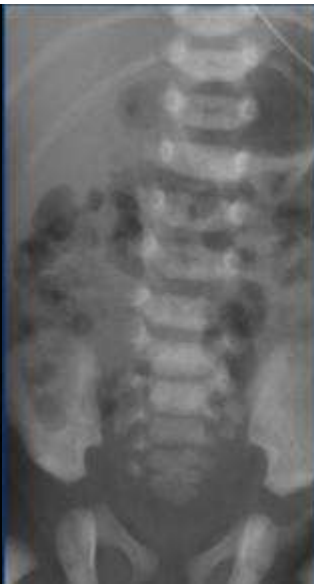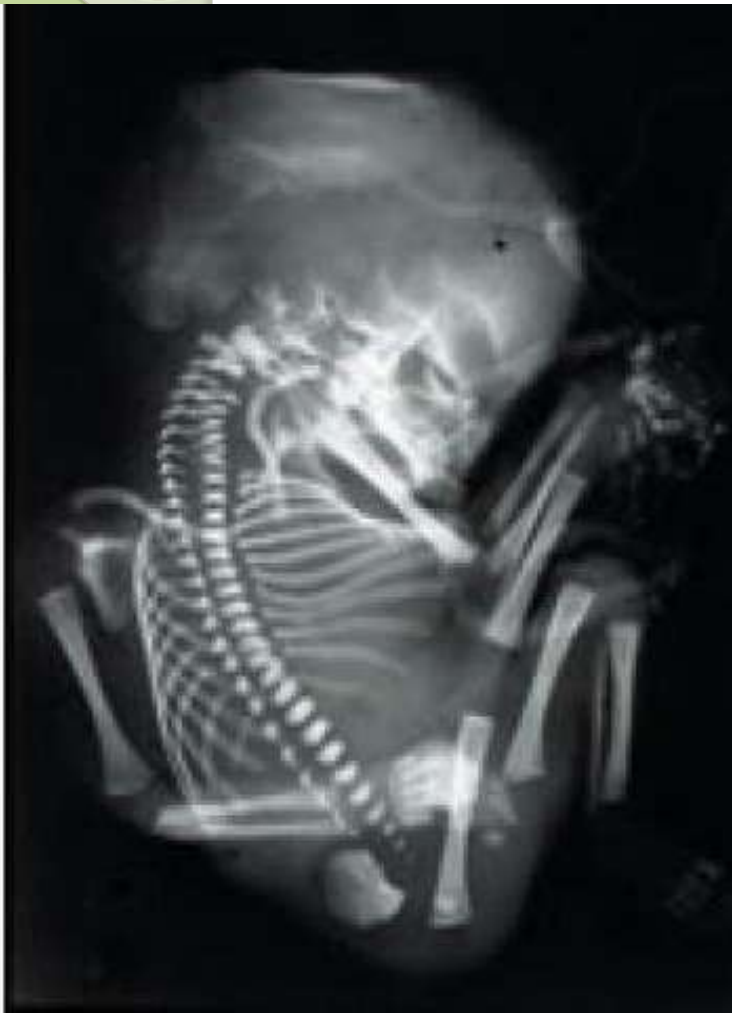Osnovni pregled poročja

- Bipedalnost

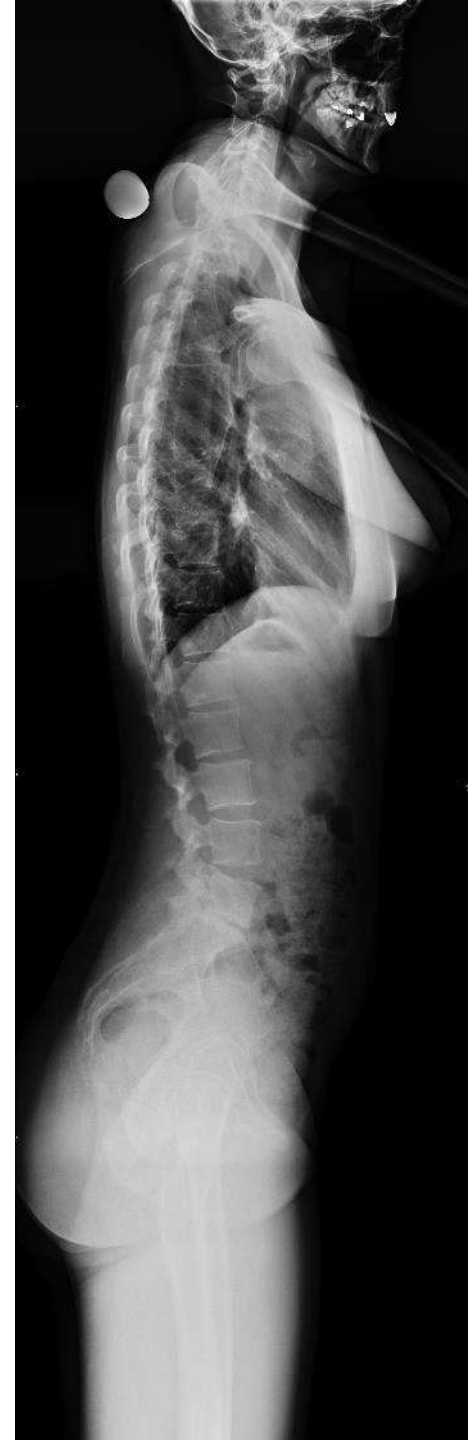
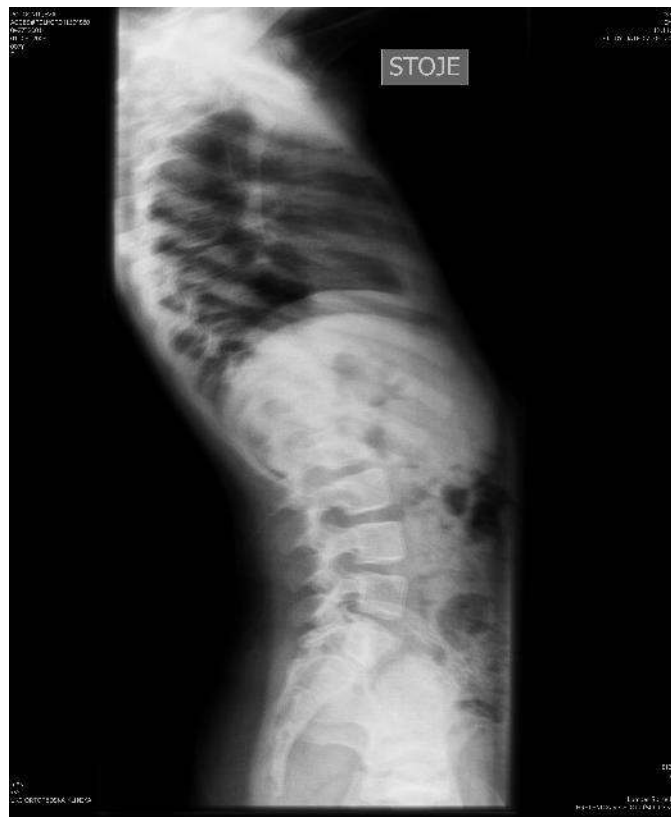
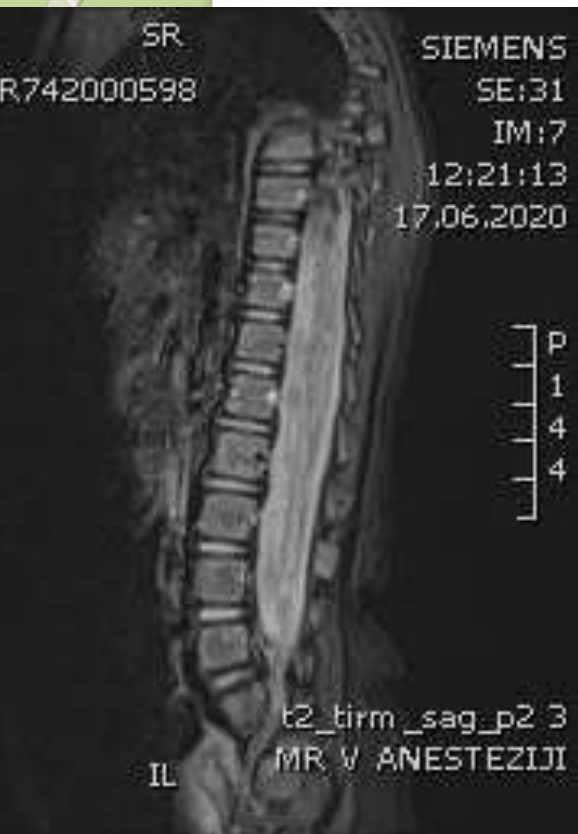Osnovni pregled poročja

- Človeška hrbtenica - evolucija



Osnovni pregled poročja



Osnovni pregled poročja

- Kje nastanejo težave?
- Degeneracija – Staranje
- Sagitalno ravnovesje

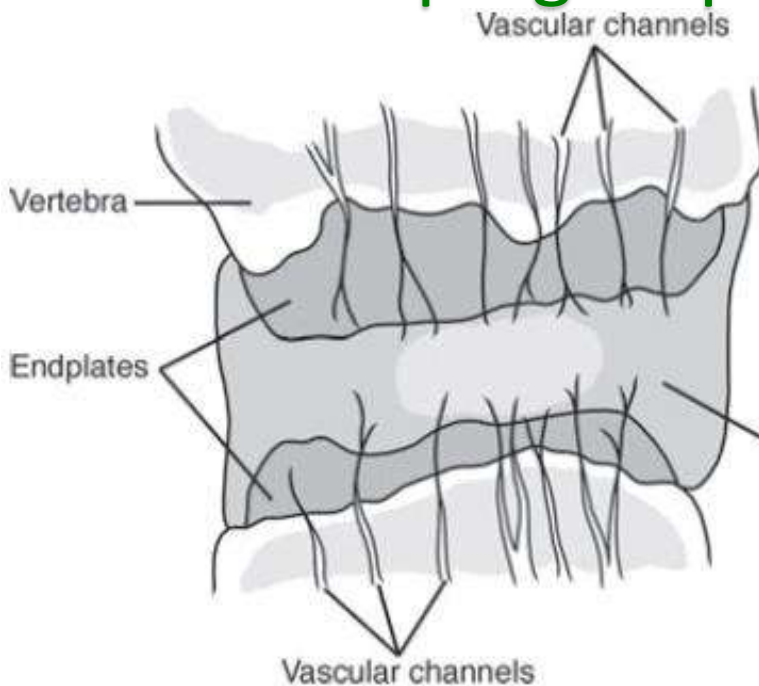
REVIEW ARTICLE

Intervertebral Disc: Anatomy-Physiology- Pathophysiology-Treatment

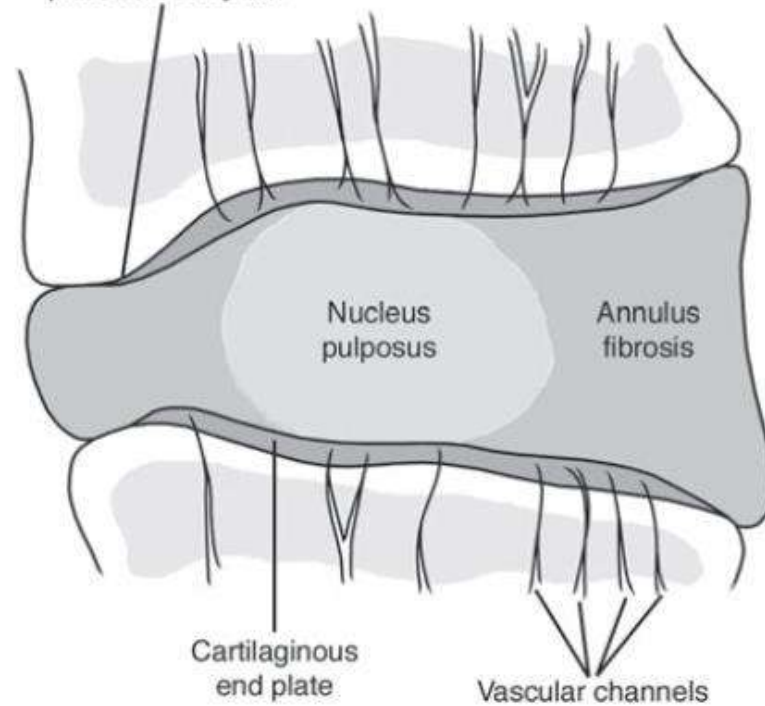
P. Prithvi Raj, MD, FIPP, ABIPP

*Department of Anesthesiology and Pain Management, Texas Tech University, Lubbock,
Texas, U.S.A.*

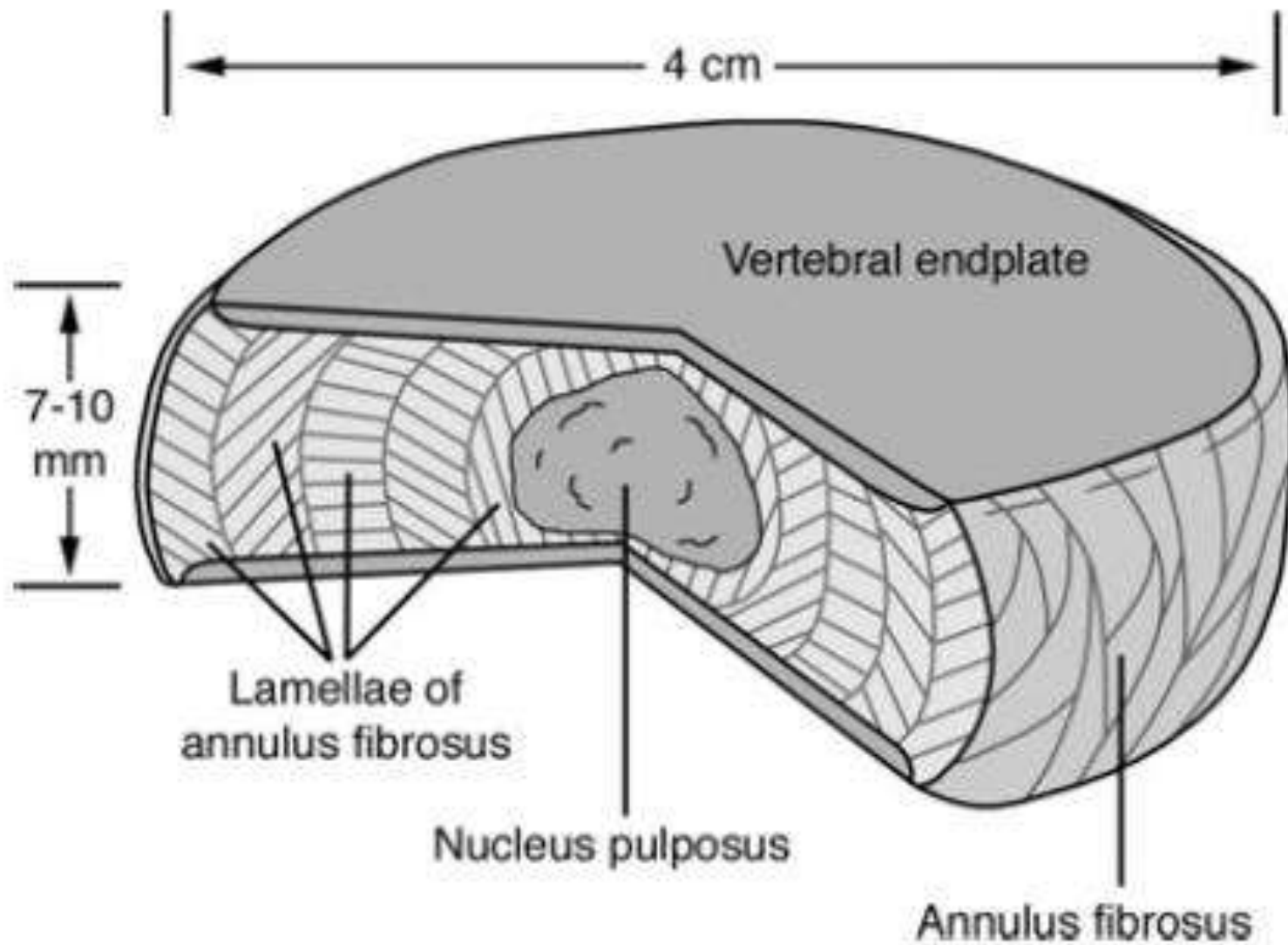
Osnovni pregled poročja



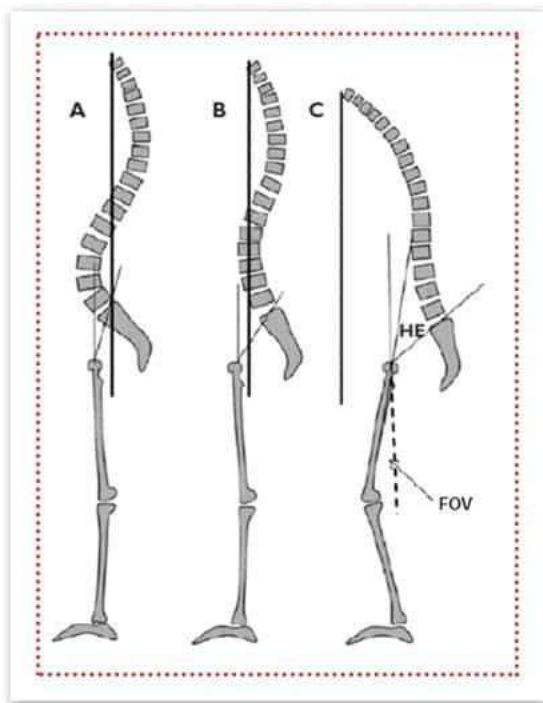
Annulus fibrosis
Junction of cartilaginous plate and bony rim



Osnovni pregled poročja

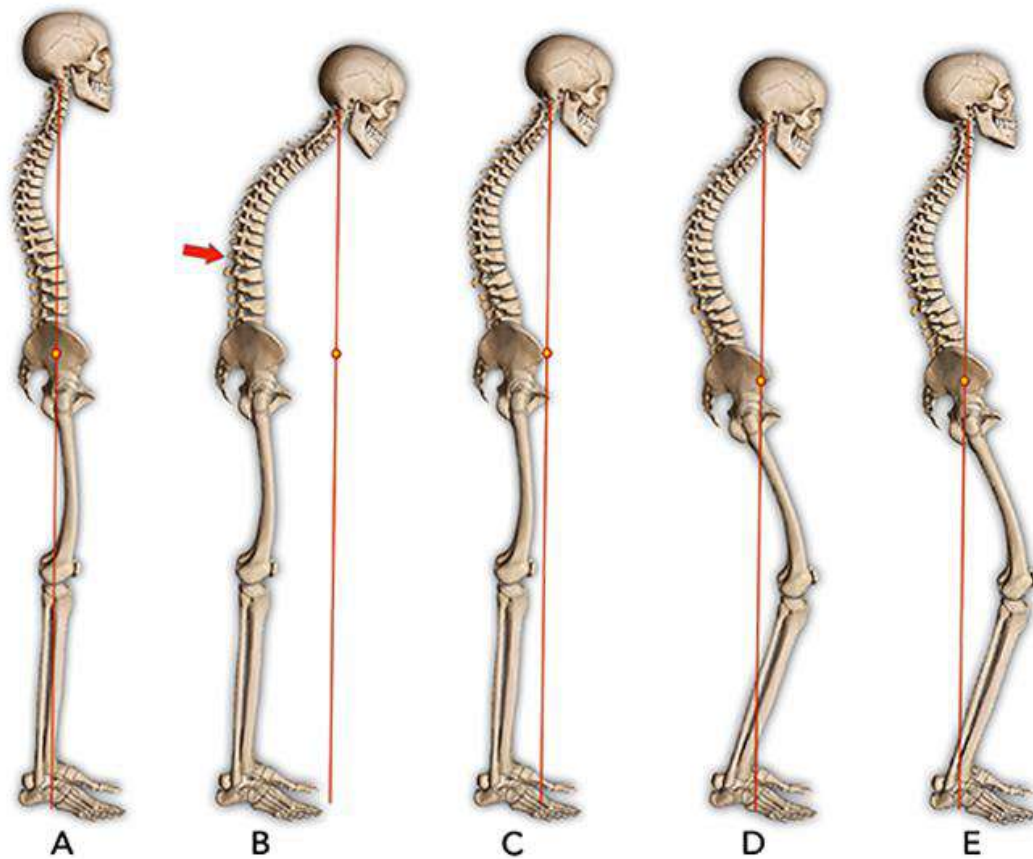


Osnovni pregled poročja

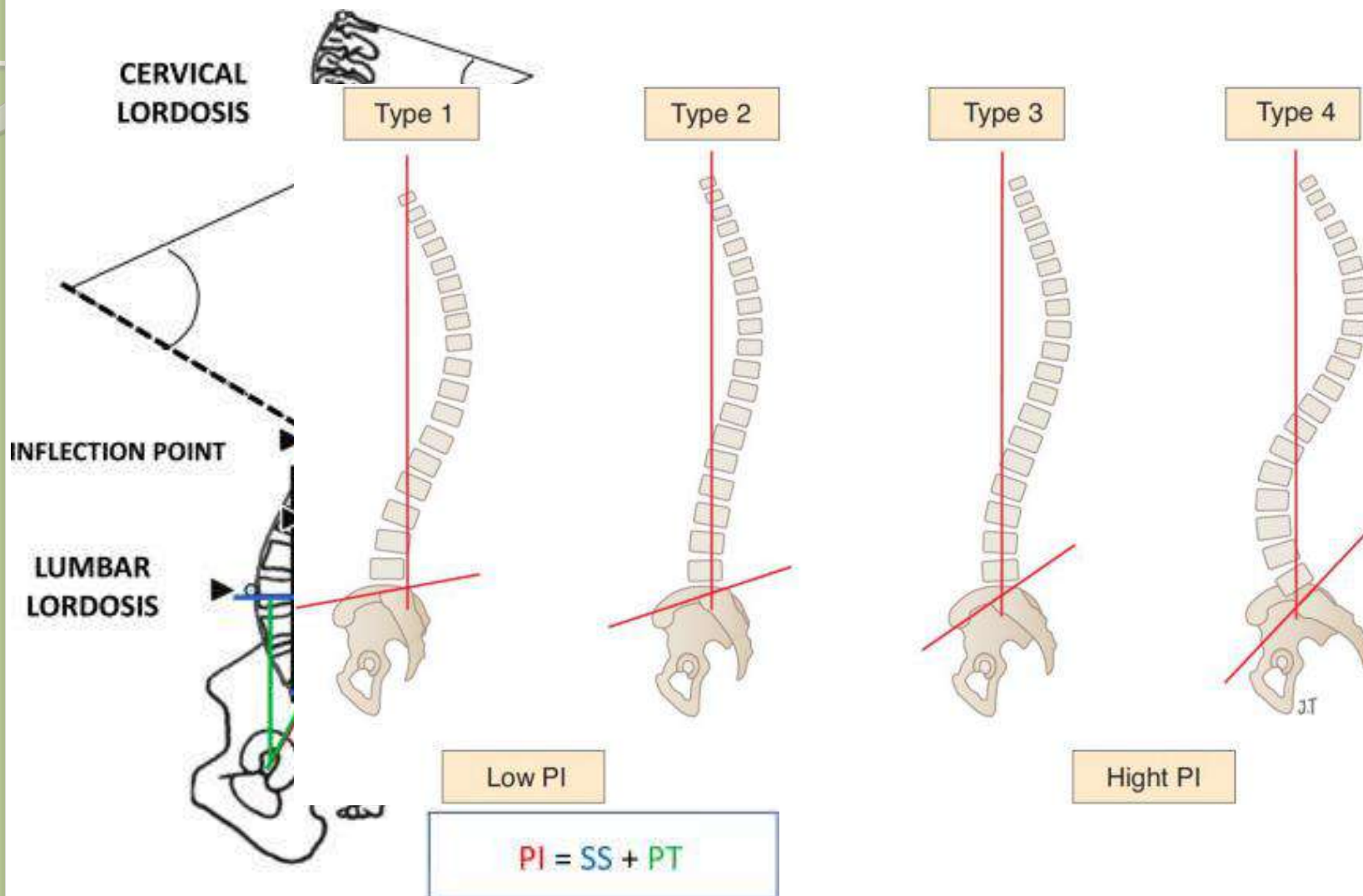


www.spinesurgeon.in

 Spine Surgeon



Osnovni pregled poročja

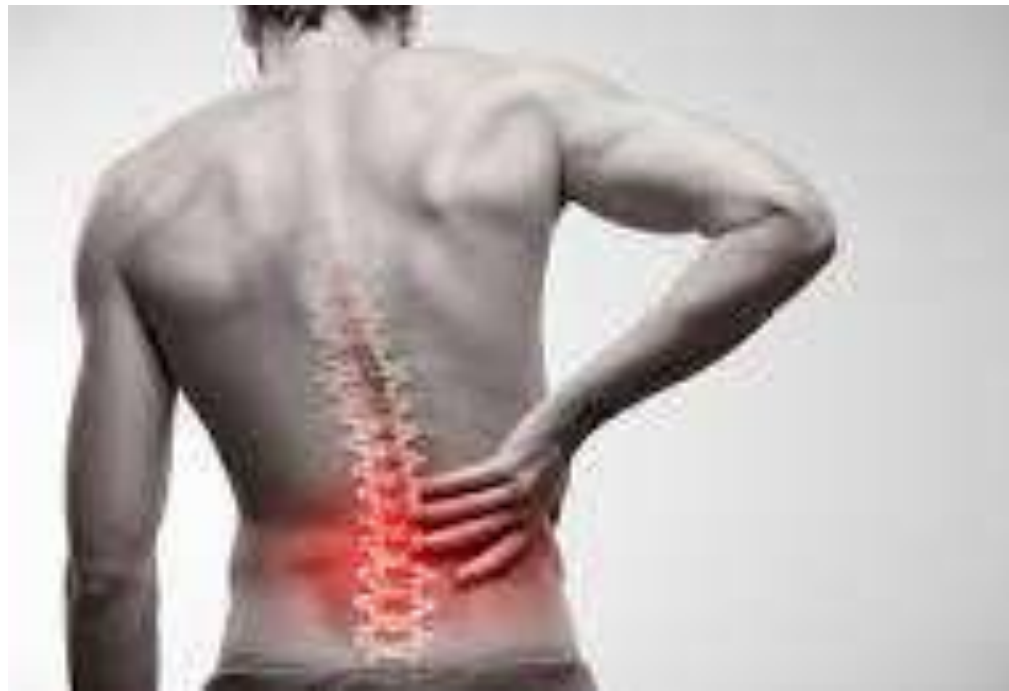

Plan predstavitve

- Osnovni pregled področja (10 min)
- **Pacient s težavo s hrbtenico (10 min)**
- Bolezni hrbtenice (10 min)
- Kirurgija hrbtenice (kaj počnemo?) (10 min)
- V&O (5 min)

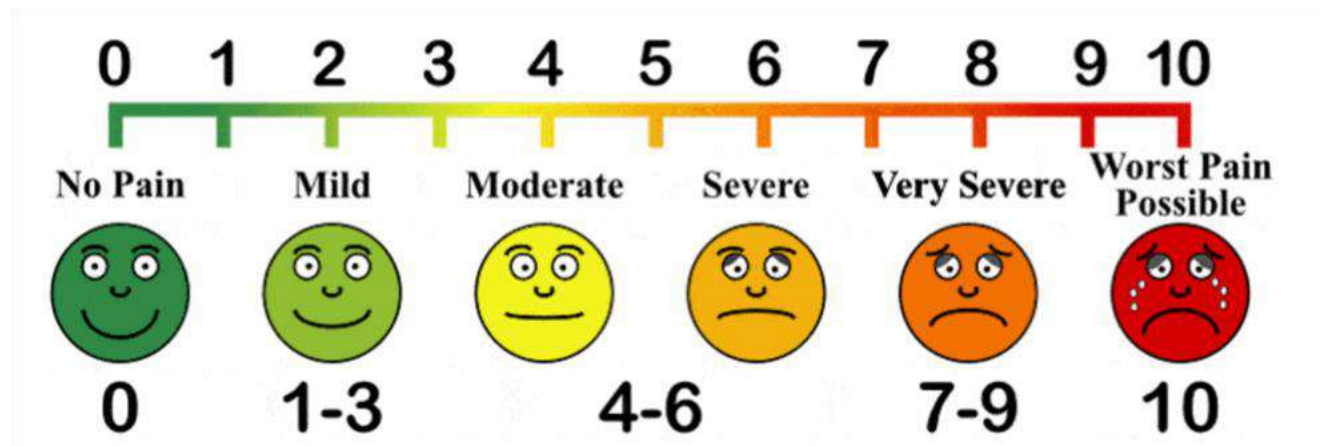
Pacient s težavo s hrbtenico

- Glavni simptomi
 - Bolečina
 - Nezmožnost
 - Nevrološki izpadi



Pacient s težavo s hrbtenico

- Bolečina
 - Aksialna (vrat, hrbet, ritnice)
 - Periferna (roke, noge)
- VAS



Pacient s težavo s hrbtenico

- Nezmožnost – ne more opraviti naloge
 - ODI

SECTION 1 - PAIN INTENSITY

- I have no pain at the moment.
- The pain is very mild at the moment.
- The pain is moderate at the moment.
- The pain is fairly severe at the moment.
- The pain is very severe at the moment.
- The pain is the worst imaginable at the moment.

SECTION 2 - PERSONAL CARE (washing, dressing etc.)

- I can look after myself normally, without causing extra pain.
- I can look after myself normally, but it is very painful.
- It is painful to look after myself and I am slow and careful.
- I need some help, but manage most of my personal care.
- I need help every day in most aspects of self-care.
- I do not get dressed, wash with difficulty and stay in bed.

SECTION 3 - LIFTING

- I can lift heavy weights without extra pain.
- I can lift heavy weights, but it gives extra pain.
- Pain prevents me from lifting heavy weights off the floor, but I can manage if they are conveniently positioned (e.g., on a table).
- Pain prevents me from lifting heavy weights but I can manage light to medium weights if they are conveniently positioned.
- I can lift only very light weights.
- I cannot lift or carry anything at all.

SECTION 4 - WALKING

- Pain does not prevent me walking any distance.
- Pain prevents me walking more than 1 mile.
- Pain prevents me walking more than ½ of mile.
- Pain prevents me walking more than 100 yards.
- I can only walk using a stick or crutches.
- I am in bed most of the time and have to crawl to the toilet.

SECTION 5 - SITTING

- I can sit in any chair as long as I like.
- I can sit in my favourite chair as long as I like.
- Pain prevents me from sitting for more than 1 hour.
- Pain prevents me from sitting more than ½ an hour.
- Pain prevents me from sitting more than 10 minutes.
- Pain prevents me from sitting at all.

SECTION 6 - STANDING

- I can stand as long as I want without extra pain.
- I can stand as long as I want but it gives me extra pain.
- Pain prevents me from standing for more than 1 hour.
- Pain prevents me from standing for more than ½ an hour.
- Pain prevents me from standing for more than 10 minutes.
- Pain prevents me from standing at all.

SECTION 7 - SLEEPING

- My sleep is never disturbed by pain.
- My sleep is occasionally disturbed by pain.
- Because of pain, I have less than 6 hours of sleep.
- Because of pain, I have less than 4 hours of sleep.
- Because of pain, I have less than 2 hours of sleep.
- Pain prevents me from sleeping at all.

SECTION 8 - SEX LIFE (if applicable)

- My sex life is normal and causes no extra pain.
- My sex life is normal but causes some extra pain.
- My sex life is nearly normal but is very painful.
- My sex life is severely restricted by pain.
- My sex life is nearly absent because of pain.
- Pain prevents any sex life at all.

SECTION 9 - SOCIAL LIFE

- My social life is normal and causes me no extra pain.
- My social life is normal, but increases the degree of pain.
- Pain has no significant effect on my social life apart from limiting my more energetic interests, e.g., sports, etc.
- Pain has restricted my social life and I do not go out as often.
- Pain has restricted my social life to my home.
- I have no social life because of pain.

SECTION 10-TRAVELLING

- I can travel anywhere without pain.
- I can travel anywhere but it gives extra pain.
- Pain is bad but I manage journeys over 2 hours.
- Pain restricts me to journeys of less than 1 hour.
- Pain restricts me to short necessary journeys under 30 minutes.
- Pain prevents me from travelling except to receive treatment.

Pacient s težavo s hrbtenico

**Modified
ODI
score (%)**

Level of disability

0–20	Minimal disability
21–40	Moderate disability
41–60	Severe disability
61–80	Cripple, pain impinges on all aspects of patient's life
81–100	Patients are bed-bound or exaggerating their symptoms



Pacient s težavo s hrbtenico

- Nevrološki izpadi
 - Klinični pregled
- Inspekcija
- Palpacija
- Gibljivost (ROM)
- Nevrološki pregled
- Specifični testi

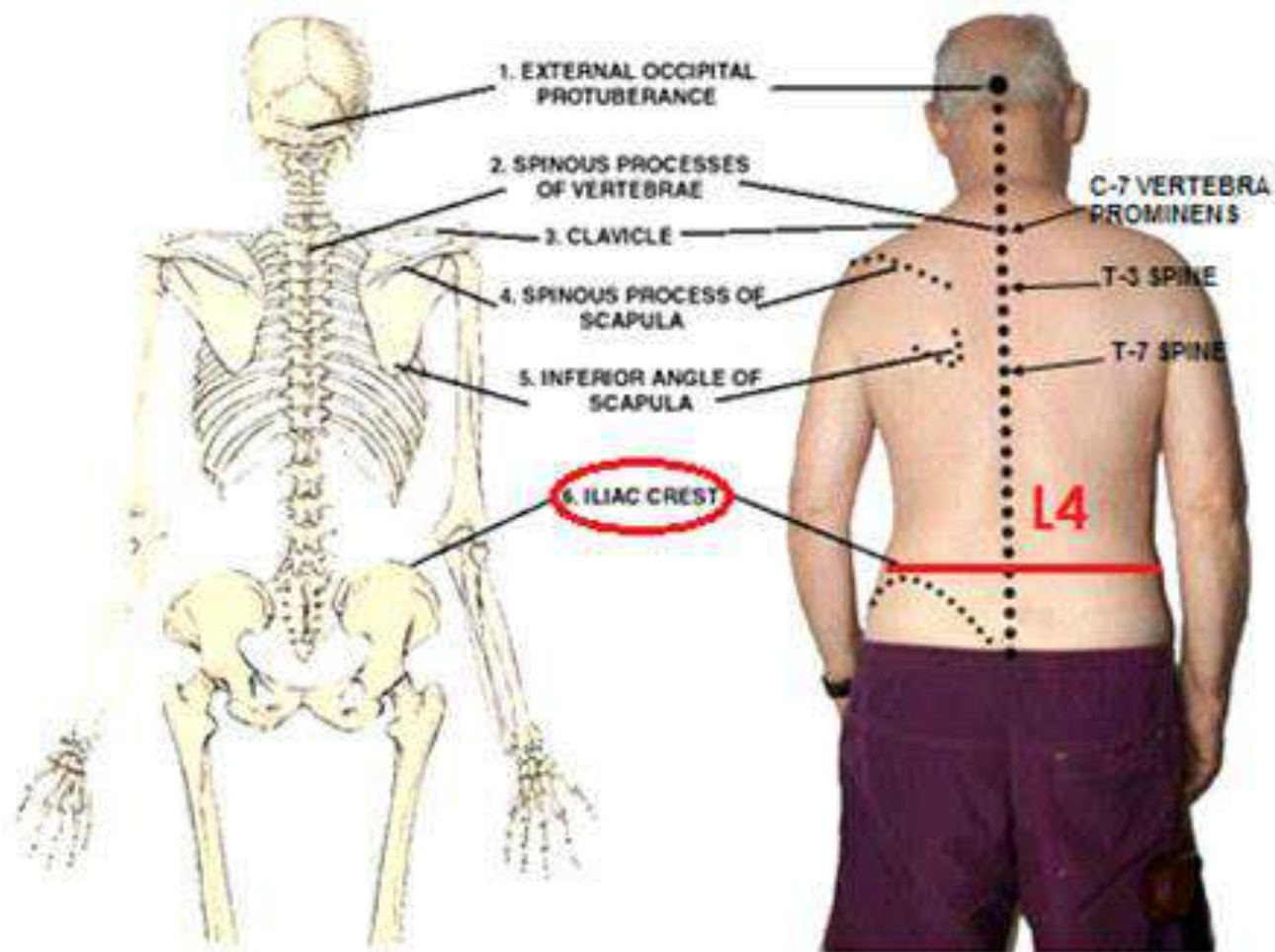
Pacient s težavo s hrbtenico

- Inspekcija (glava, vrat, položaj trupa, vzorec hoje, obraz)




Pacient s težavo s hrbtenico

- Palpacija



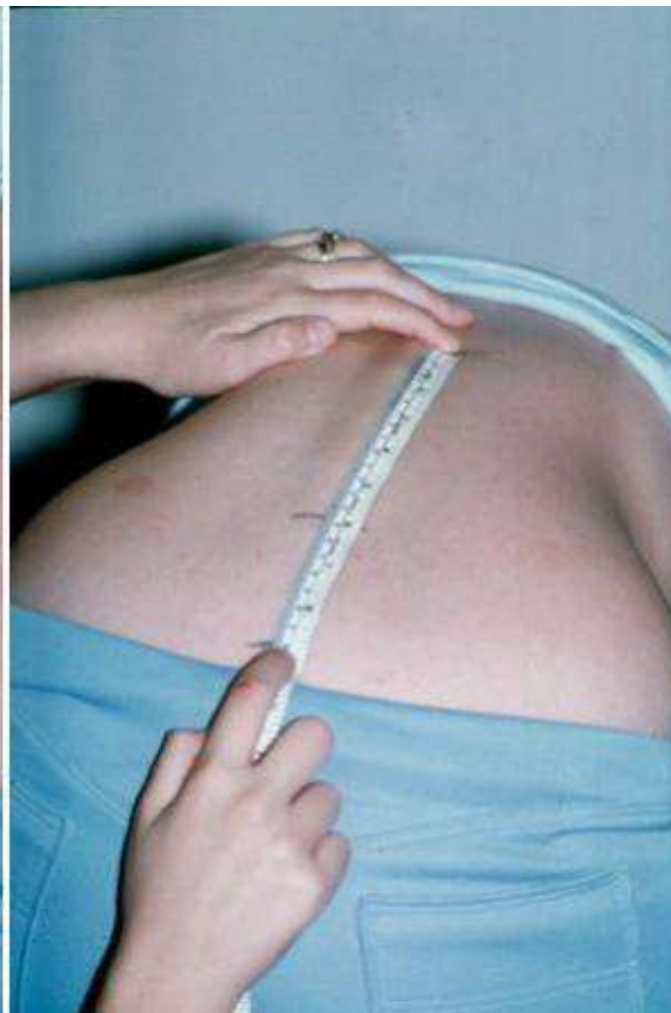
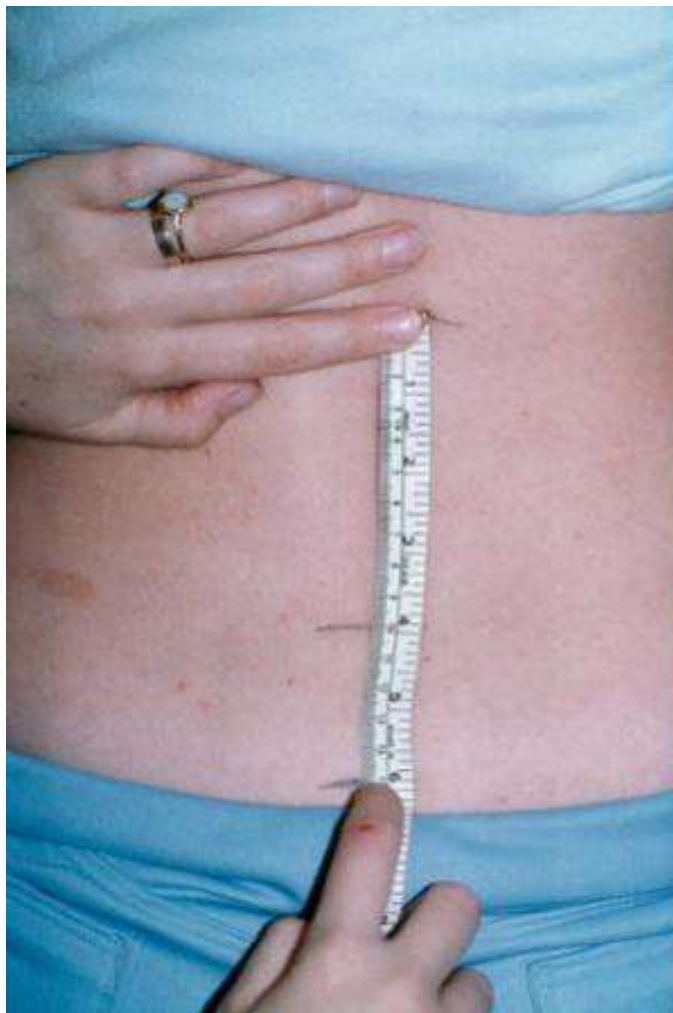
Pacient s težavo s hrbtenico

- Gibljivost (ROM)



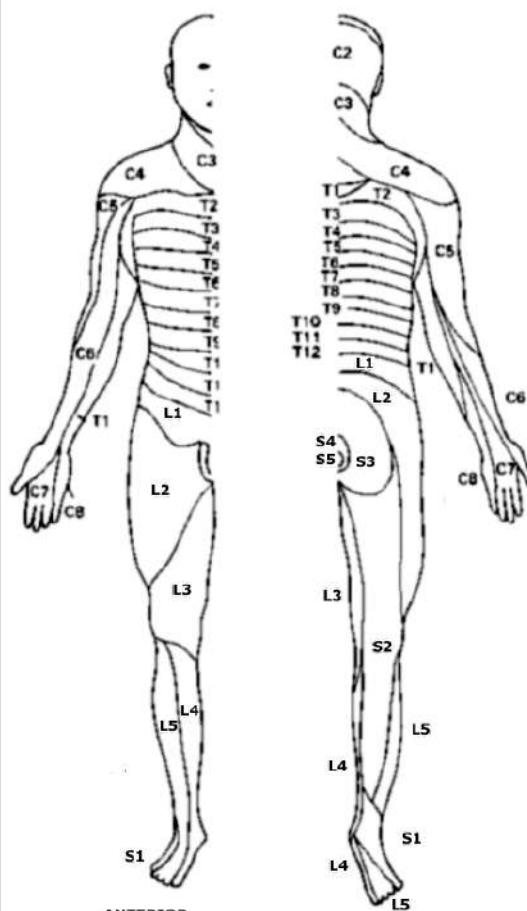
Pacient s težavo s hrbtenico

- Test po Schobru

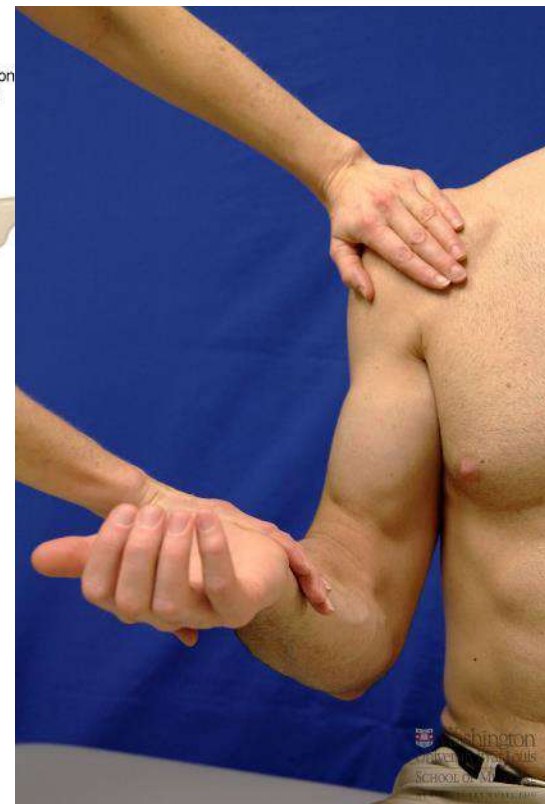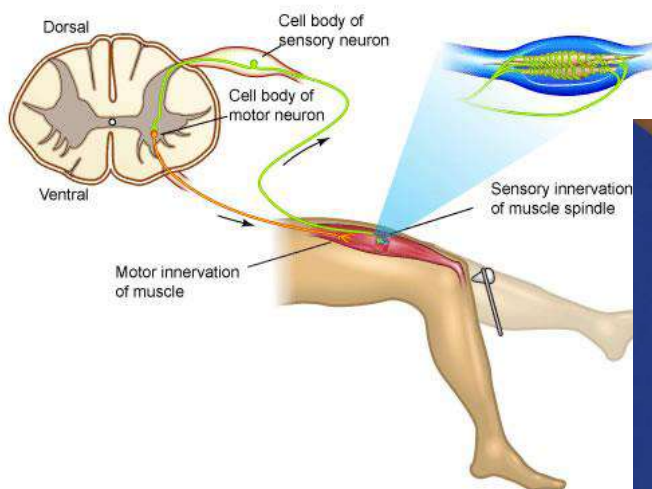


Pacient s težavo s hrbtenico

- Nevrološki pregled

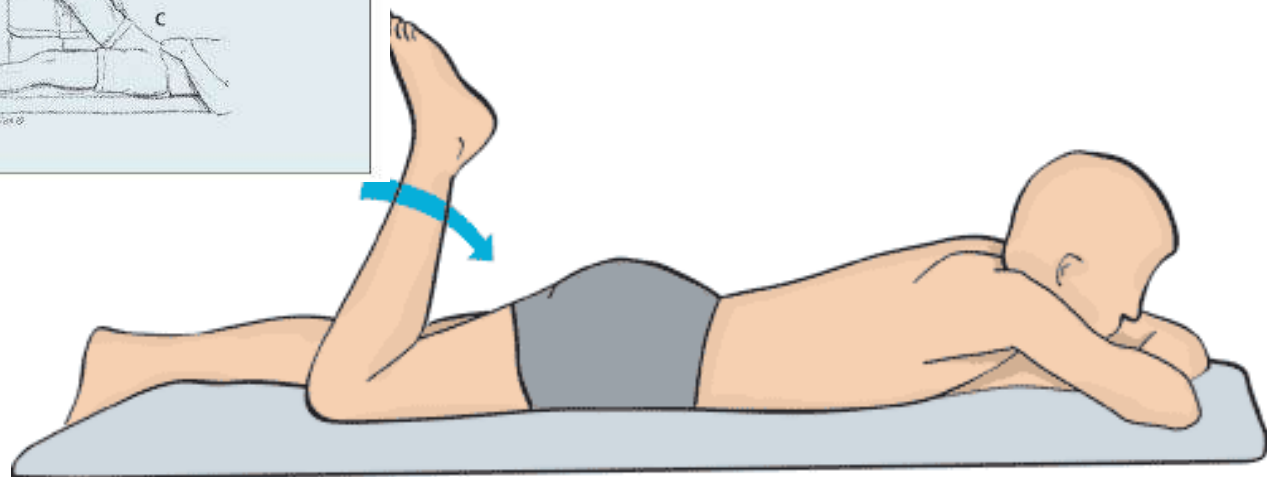
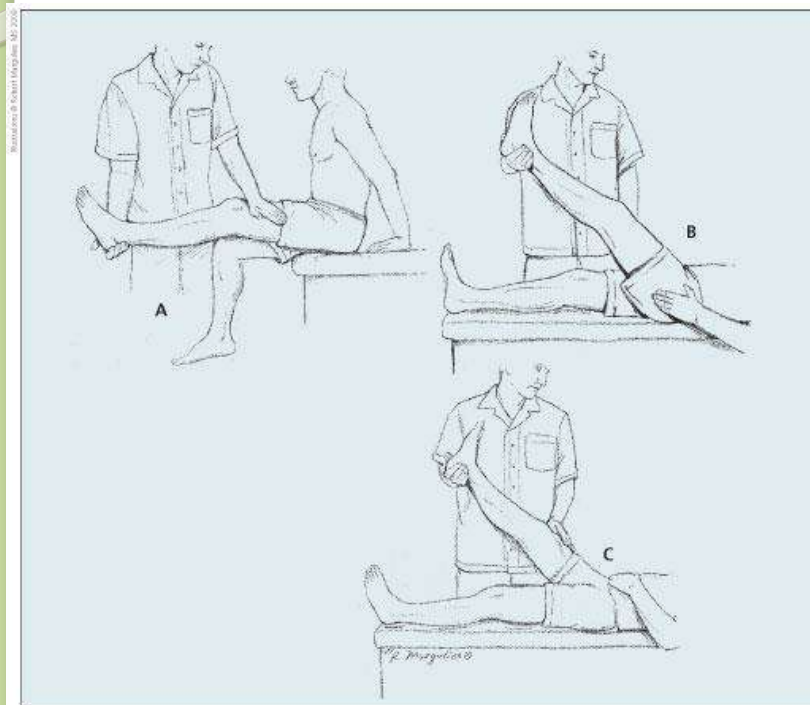


ANTERIOR
POSTERIOR
Distribution of spinal nerve roots on the skin.
Territories of the roots (dermatomes) overlap.



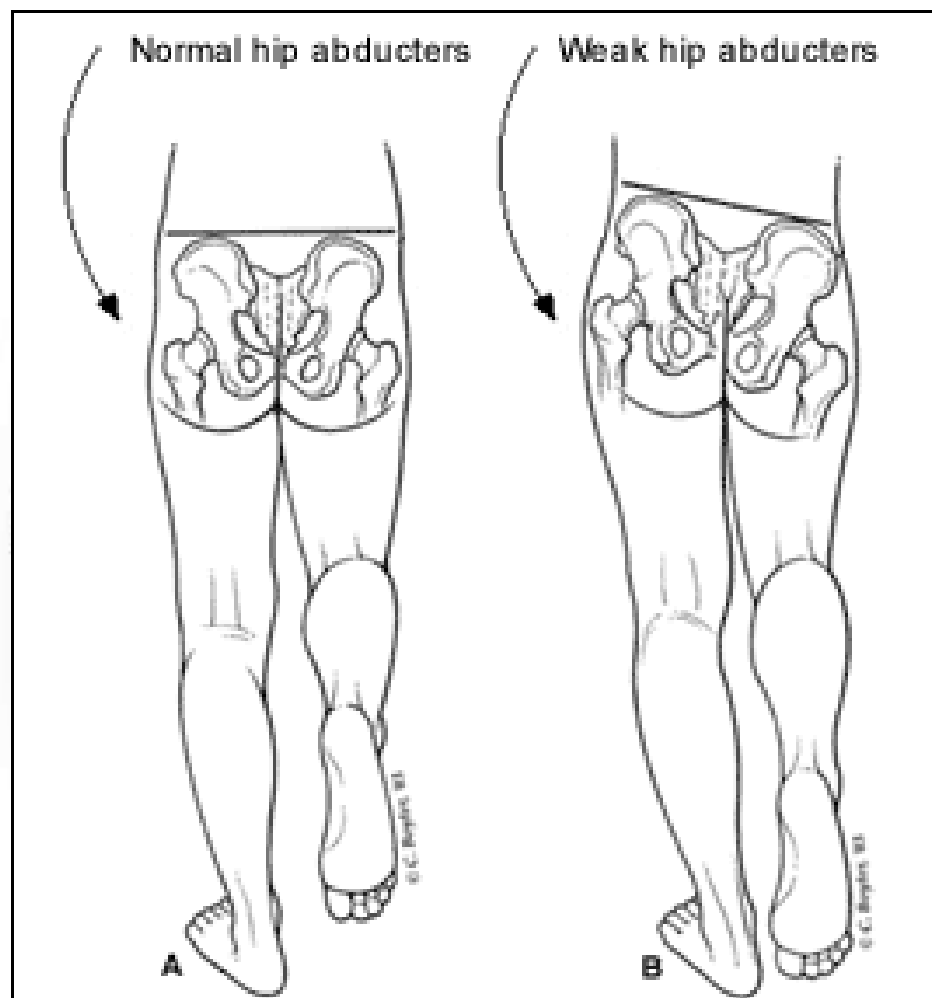
Pacient s težavo s hrbtenico

- Nevrološki pregled



Pacient s težavo s hrbtenico

- Specifični testi



Pacient s težavo s hrbtenico

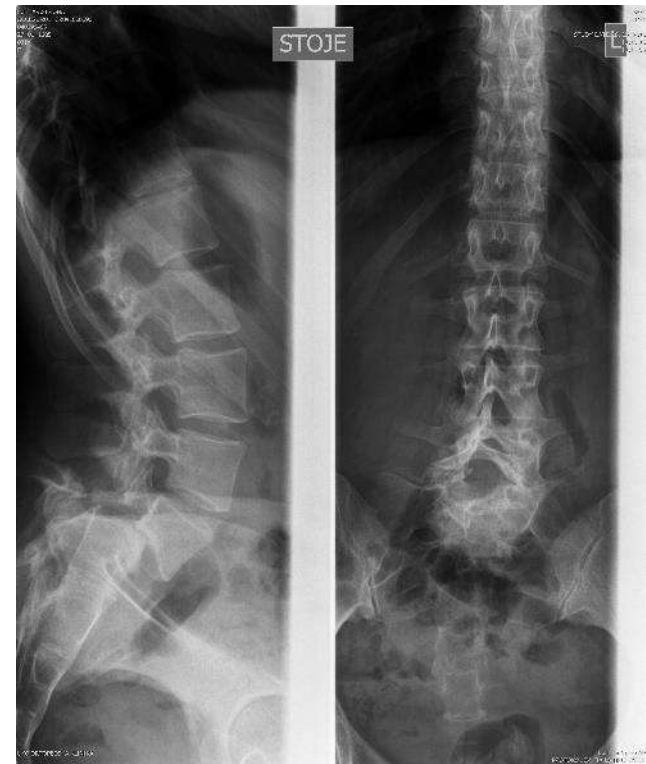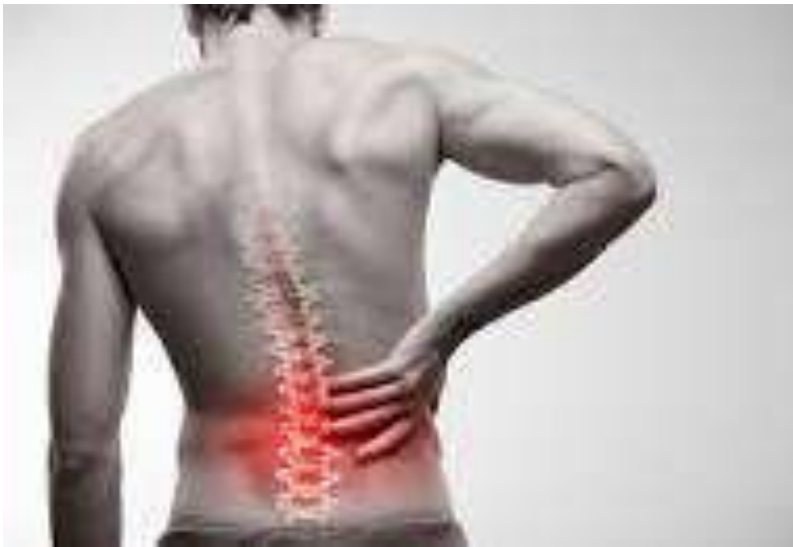- Diagnostika
 - RTG (AP, lat, funkcionalno, polstransko, celotna hrbtenica, ...)
 - MRI (zlati standard)
 - CT (struktura kosti)
 - Scintigrafija, SPECT-CT, PET-CT (metabolna)
 - EMG, MEP, SEP (electricna)
 - Infiltration, Discography (provokacijska)

Plan predstavitve

- Osnovni pregled področja (10 min)
- Pacient s težavo s hrbtenico (10 min)
- **Bolezni hrbtenice** (10 min)
- Kirurgija hrbtenice (kaj počnemo?) (10 min)
- V&O (5 min)

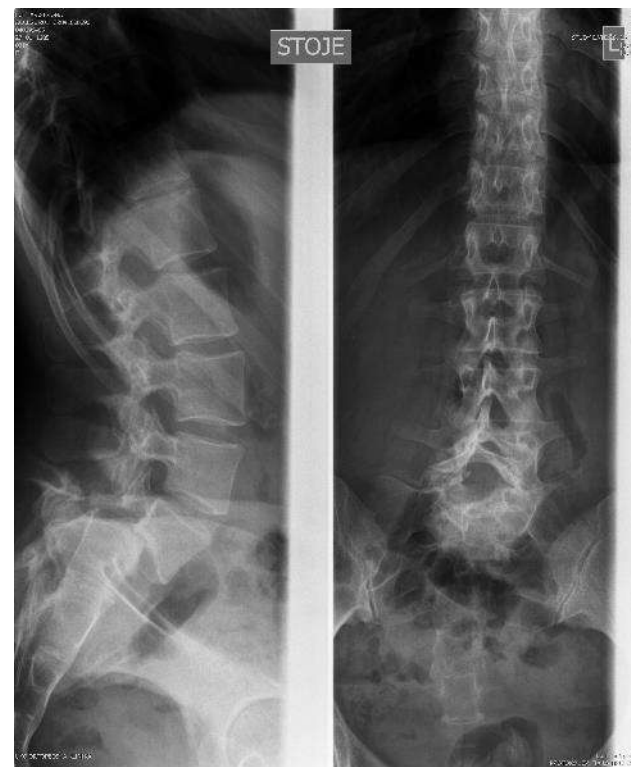
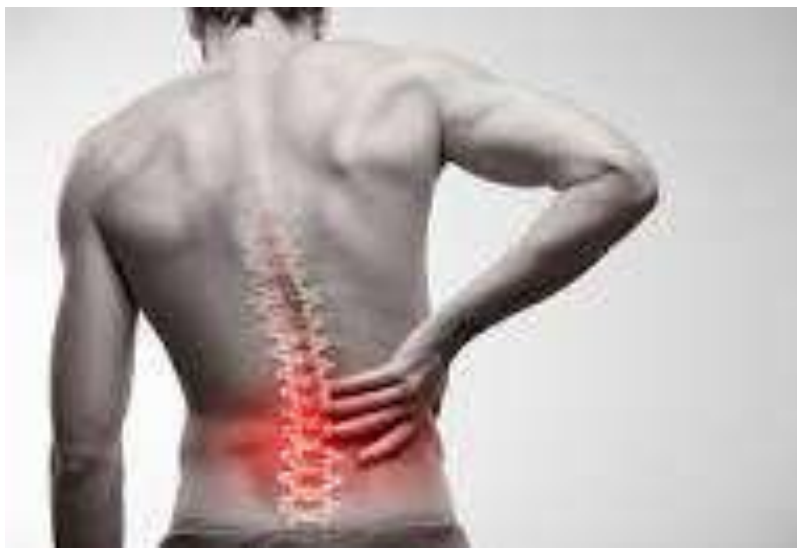Bolezni hrbtenice

- Funkcionalne bolezni (mišično-fascialne)
- Strukturne (mehanske) bolezni



Bolezni hrbtenice

- Funkcionalne bolezni (mišično-fascialne)
- **Strukturne (mehanske) bolezni**



Specification of Main Pathology Only answer questions related to Main Pathology (Main Pathology "other" requires no specification).

Deg. disease

Type of degeneration primary

- disc herniation
- central stenosis
- lateral stenosis
- foraminal stenosis
- degen. disc disease
- degen. deformity
- degen. spondylolisthesis
- other instability
- myelopathy
- facet joint arthrosis
- synovial cyst
- SI joint
- other

Spec. type of deformity
Spec. grade of spondylolisthesis

secondary

- none
- disc herniation
- central stenosis
- lateral stenosis
- foraminal stenosis
- degen. disc disease
- degen. deformity
- degen. spondyl.
- other instability
- myelopathy
- facet joint arthrosis
- synovial cyst
- SI joint
- other

Spec. type of deformity
Spec. grade of spondylolisthesis

(Pathological) Fracture/Trauma

Type of (pathological) fracture/trauma

- condylar (C0)
- C0/1 dissociation
- C1 fracture
- C1/2 instability
- C2 dens fracture
- C2 other fracture
- soft tissue injury neck
- fracture C3-C7
- fracture Th1-L5/S1
- sacrum fracture
- other

AO Classification applies to the most severely affected VB

C3-L5/S1 AO Fracture type

- A0 A3 B2
- A1 A4 B3
- A2 B1 C

AO Neurologic injury

- N0 N2 N4
- N1 N3 NX

AO Modifiers

- no modifiers
- Th1-L5/S1** **C3-C7**
- M1 M3 F2 BL
- M2 M4 F3
- F1 F4

Fracture age

- fresh fracture
- old fracture

Dens fracture type

- I II III

Osteoporotic vertebral fractures classification¹

- OF1 OF2 OF3 OF4 OF5
- Additional fractures w/different treatments require separate forms*

Pathological fracture due to

- osteoporosis
 - tumor →
 - other
- For tumor, answer questions "Type of tumor" and "Localization".*

Spondylolisthesis

Type of spondylolisthesis

- Type I (congenital, dysplastic)
- Type II (isthmic)
- Type III see type of degeneration
- Type IV (traumatic)
- Type V (pathologic)
- Type VI (postsurgical)

Grade of spondylolisthesis

- Grade 0
- Grade I
- Grade II
- Grade III
- Grade IV
- Spondyloptosis (V)

Deformity

Type of deformity also for degenerative deformity

- scoliosis
- kyphosis
- frontal imbalance
- sagittal imbalance
- other

Predominant etiology

- idiopathic
- congenital
- neuromuscular
- posttraumatic
- M. Scheuermann
- syndromic
- other

Infection

Infection specification

- pyogenic
- tuberculous
- multi-resistant
- other
- unknown

Affected structure(s)

- spondylitis
- discitis
- epidural space
- paravertebral
- other

Tumor

Localization

- extraosseous soft tissues
- intraosseous
- extrasosseous (extradural)
- intradural intramedullary
- intradural extramedullary
- other

Type of tumor

- primary malignant
- primary benign
- secondary malignant
- tumor like lesion
- other

Specify type of tumor

.....

Repeat surgery

Reason for repeat surgery

- | | | |
|---|---|---|
| <input type="checkbox"/> hardware removal | <input type="checkbox"/> postop. infection | <input type="checkbox"/> adjac. segment pathology |
| <input type="checkbox"/> non-union | <input type="checkbox"/> superficial | <input type="checkbox"/> other |
| <input type="checkbox"/> instability | <input type="checkbox"/> postop. infect. deep | |
| <input type="checkbox"/> failure to reach therapeutic goals | <input type="checkbox"/> implant malposition | |
| <input type="checkbox"/> neurocompression | <input type="checkbox"/> implant failure | |
| | <input type="checkbox"/> sagittal imbalance | |

Bolezni hrbtenice

ANTONIJA BAVEC (F)
21.02.1952 (069Y)

R

ODD ZA MAGNETNO REZONAN
Department
MRC35198

RESNIK, JOZE
ACCES#F01HMR032103500
028915718
11.05.1948
073Y
M

A
R
I

UKC LJ KIR Nevroradiologija

SAL

IPR

MR CERVICALNE HRBTENICE

SE:501
IM:9
12:35:22
12:19:53
12:33:57

STUDY DATE:18.05.2021

P
L
S

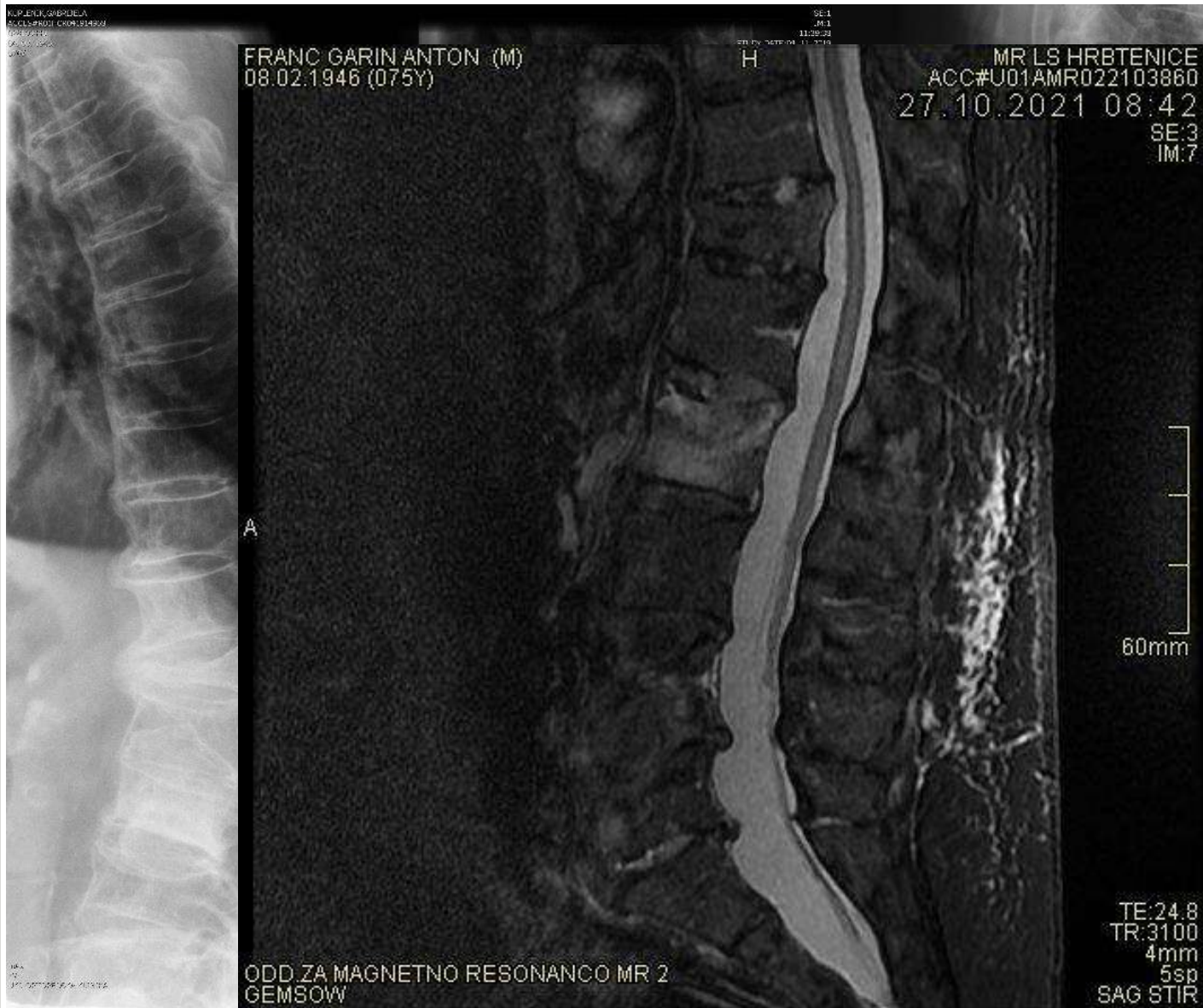MR LS HRBTENICE SKS
ACC#ZU01AMR012106716
18.11.2021 10:36
SE:4
IM:9

UVOZ BOLNIKA V IMPAX
ACC#R01ASC912100292
19.02.2020 13:32
SE:2
IM:11

80mm

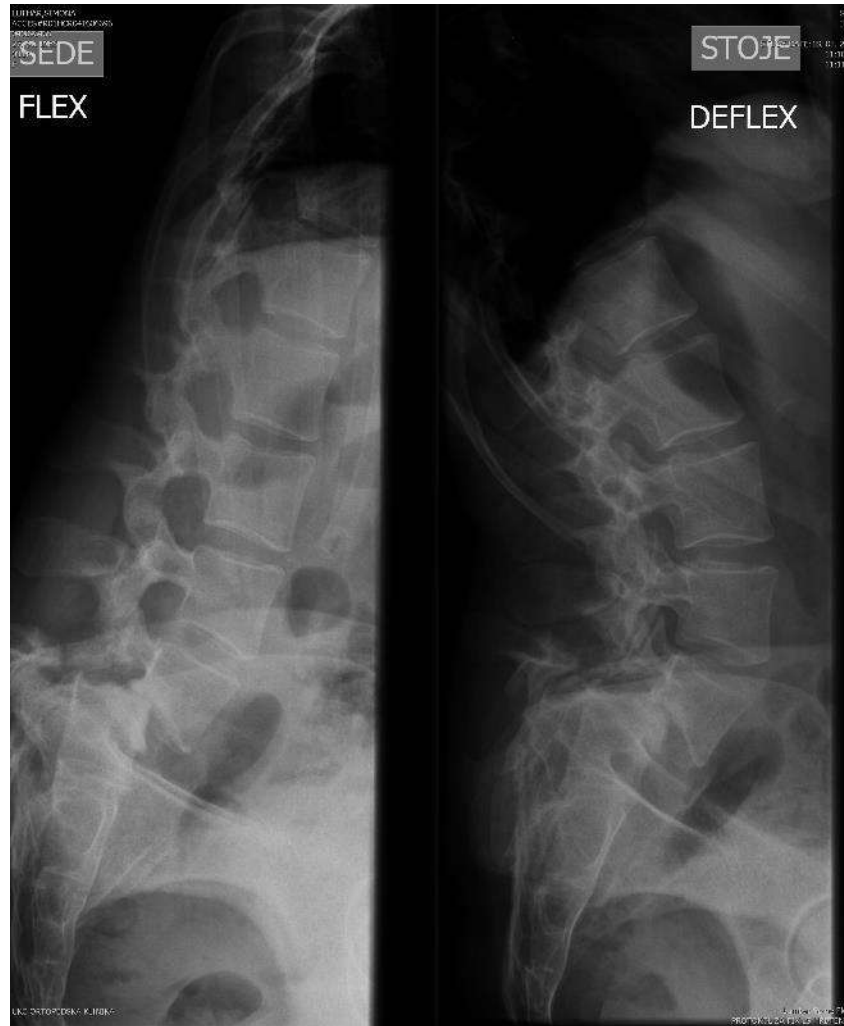TE:98
TR:4010
3mm
3.6sp
42_jse_sag_p2_384

Bolezni hrbtenice



Bolezni hrbtenice

- Displastična spondilolisteza



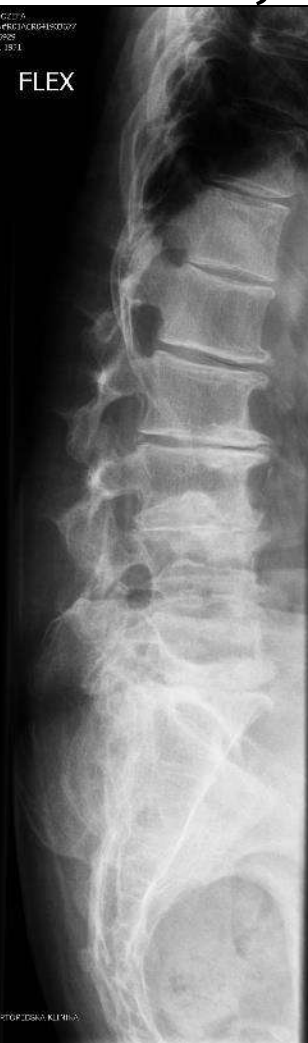Bolezni hrbtenice

- Deformacije

ODDOLJARSK
RADIOLOGIJA
IZ OBLASTI
RUK
K

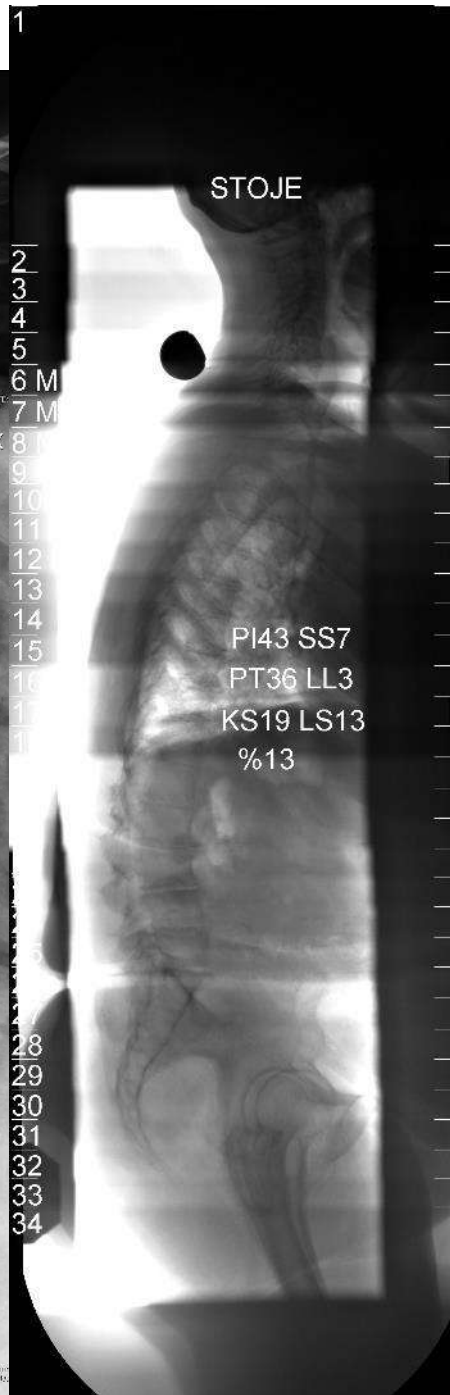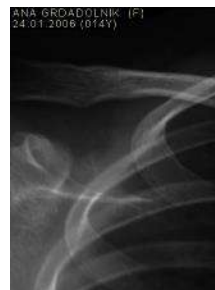ZAV. GOTO
ACCESORNI
ZEMANJE
12.10.2011
XEN
T

FLEX

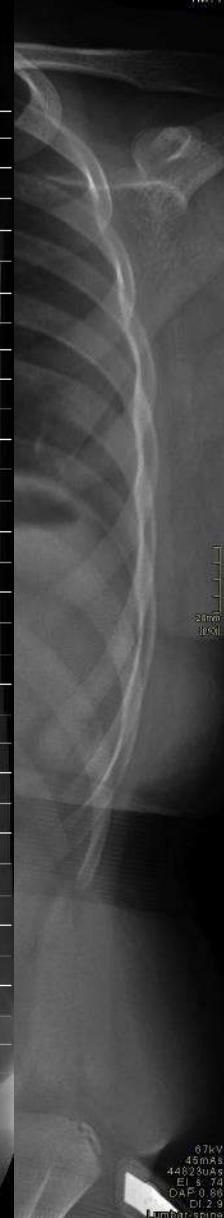


1000
600
UNC-ORTOPEDSKA KLINIKA

ANA GRDADOLNIK IFI
24.01.2006 (014Y)



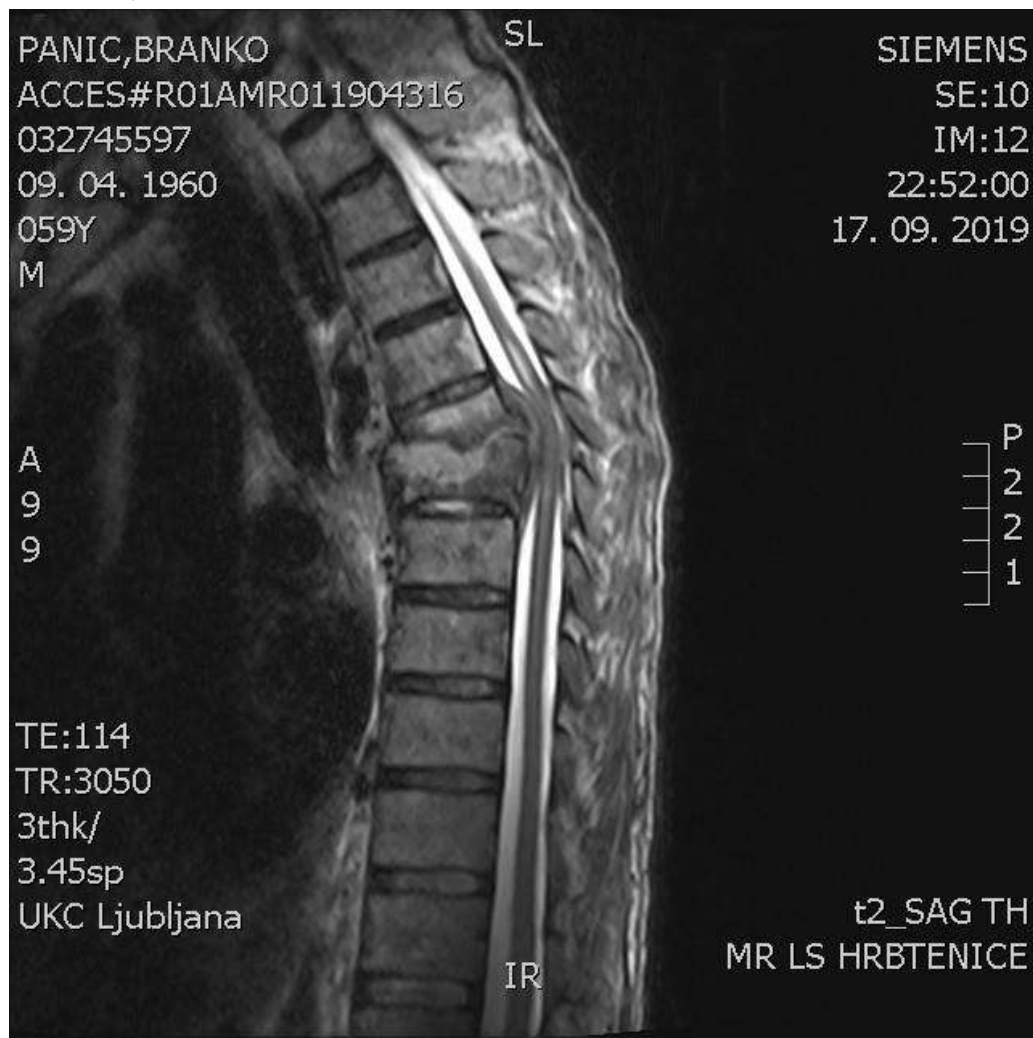HRBTENICA V CELOTI (SCOLIOZE)
ACCERO IACR052005423
29.04.2020 09:13
SE.9984
IM:1



67kV
45mA
44823uAs
EI: 8.74
DAP: 0.88
DI: 2.9
Lumbal spina

Bolezni hrbtenice

- Infekcije



Bolezni hrbtenice

BRIGITA PRAHIN (F)
25.09.1957 (064Y)

H

CT TREBUŠNIH ORGANOV S KS
ACC#TEL3937451395708

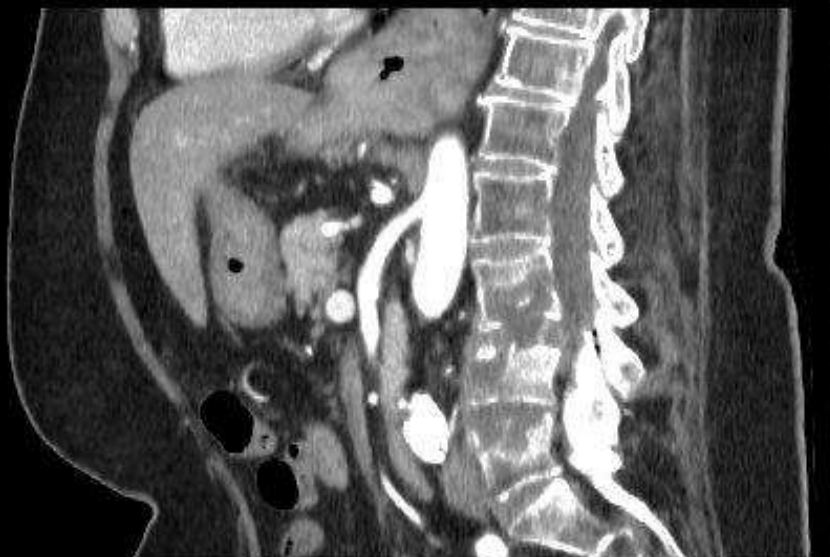04.11.2021 09:57

SE:601
IM:101

TOM9
ACCE
03923
27.1
037Y
M

A
1
0
3

A



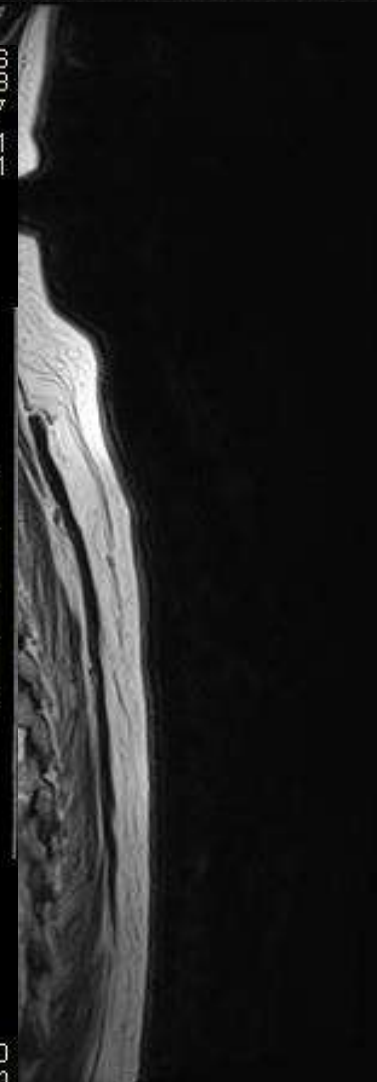
80mm

Medil

Revolution HD
SPLOSNA BOLNISNICA BREZICE
DEFAULT
CTHD

kV:120
2mm
ART SAG2

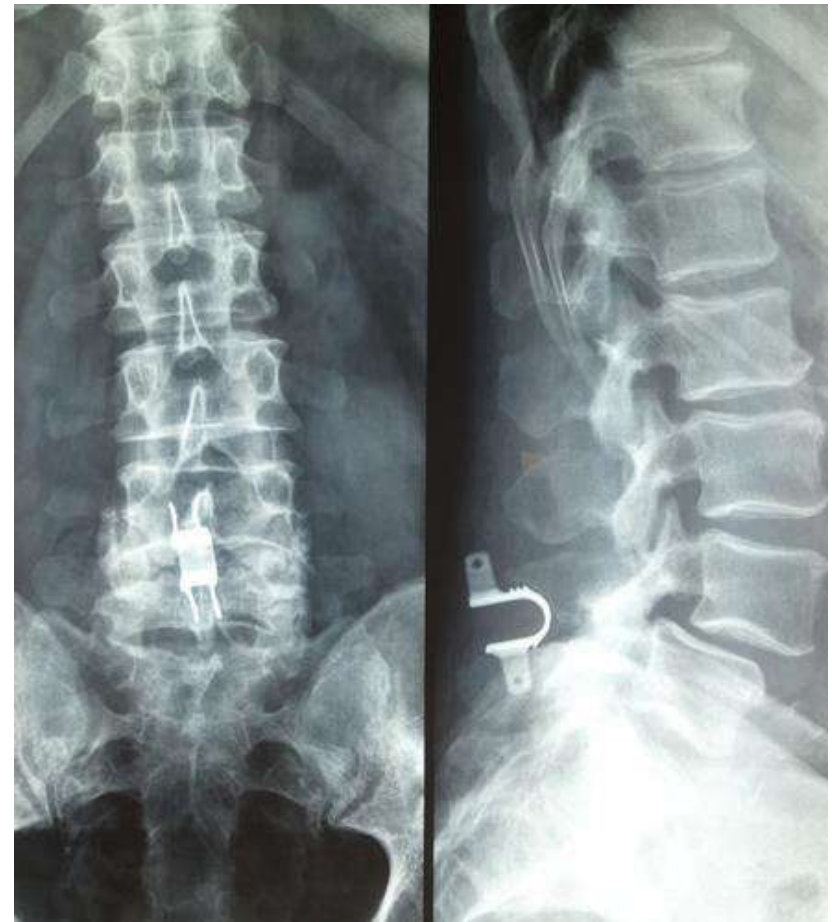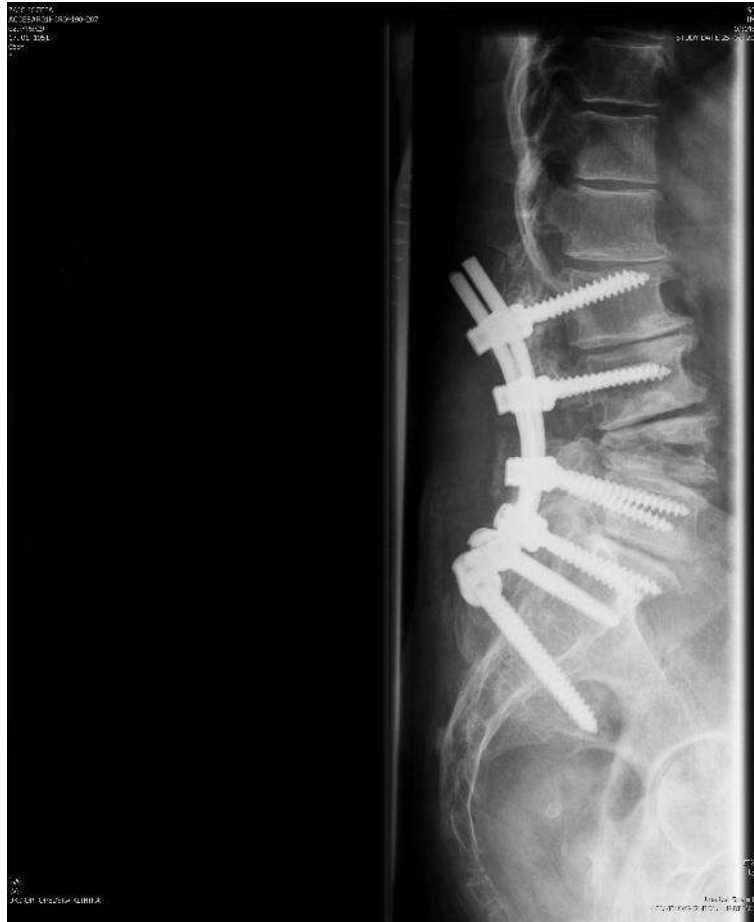A



30mm

Bolezni hrbtenice

- Ponovne operacije

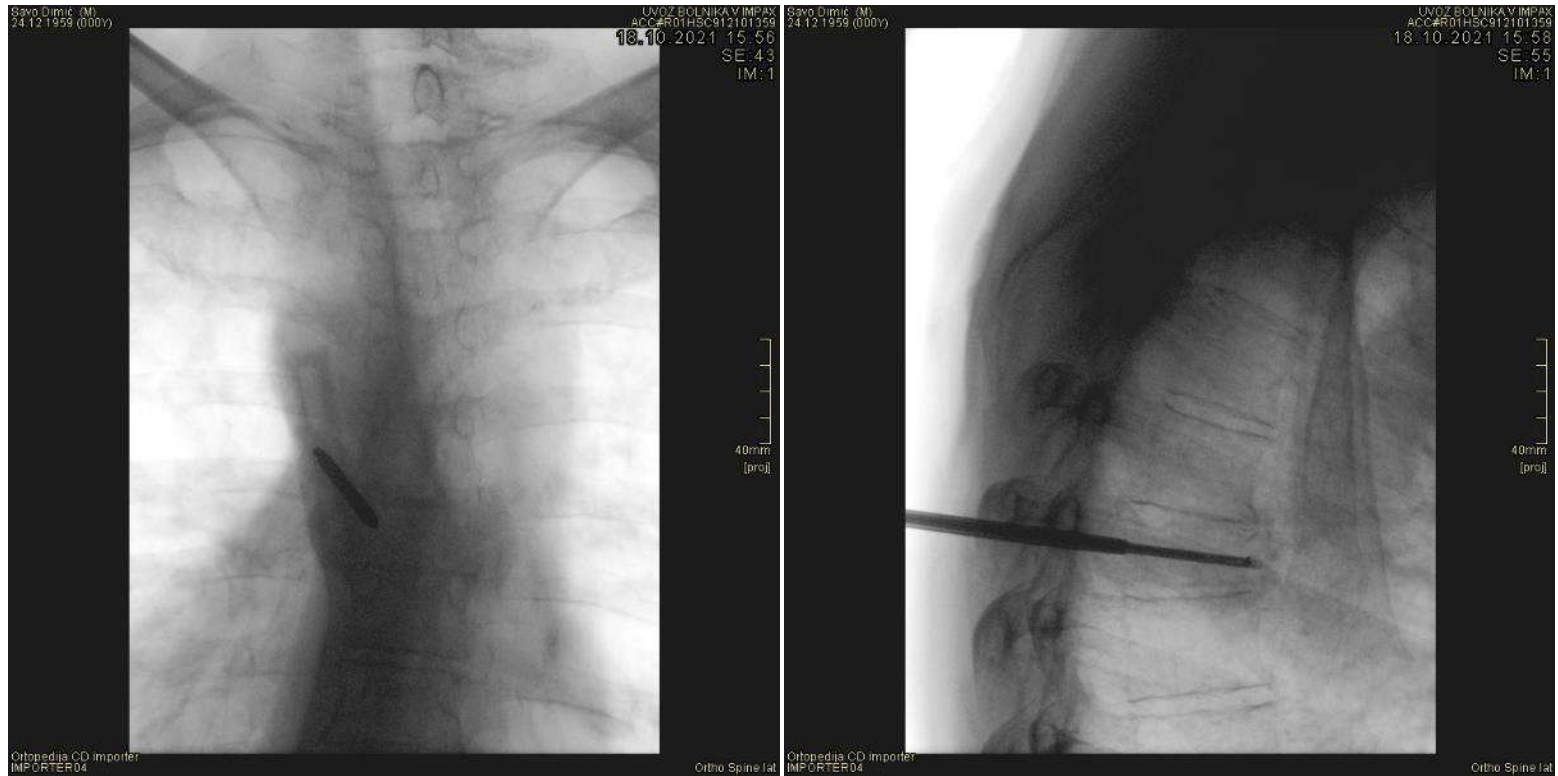


Plan predstavitve

- Osnovni pregled področja (10 min)
- Pacient s težavo s hrbtenico (10 min)
- Bolezni hrbtenice (10 min)
- **Kirurgija hrbtenice (kaj počnemo?)**
- V&O (5 min)

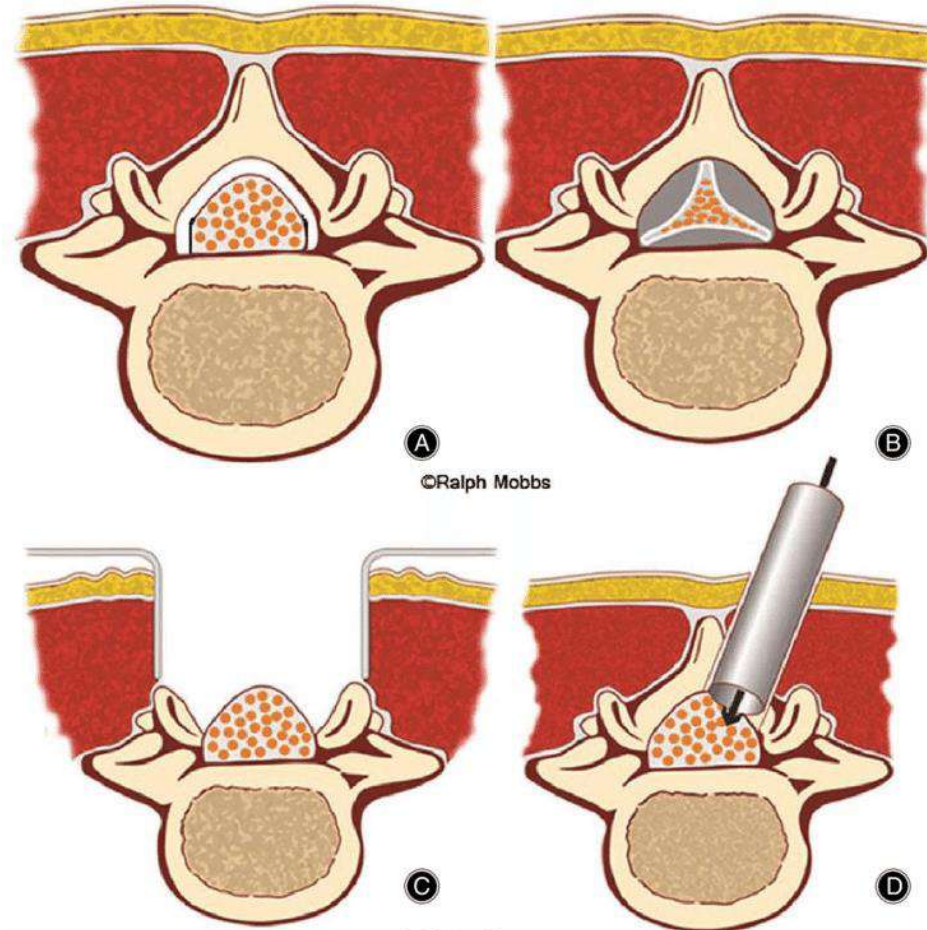
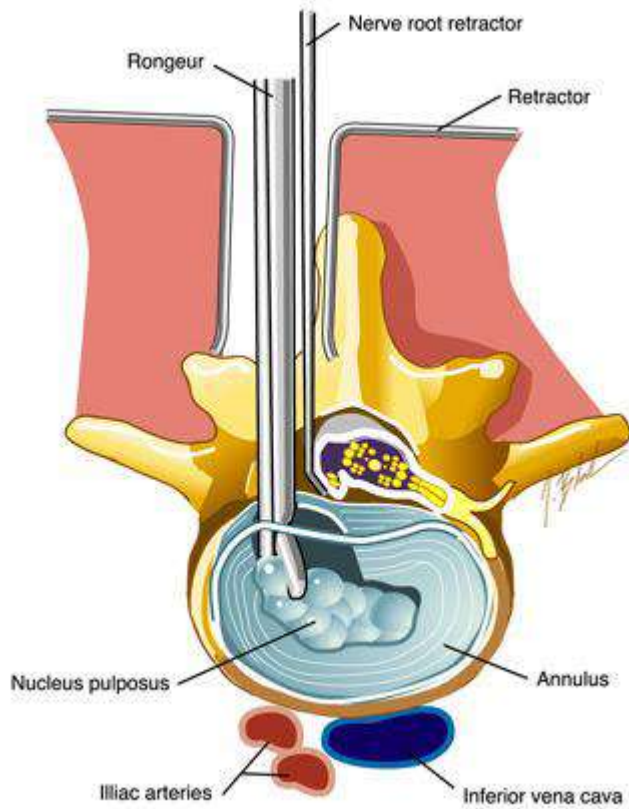
Kirurgija hrbtenice (kaj počnemo?)

- Biopsija vretenca

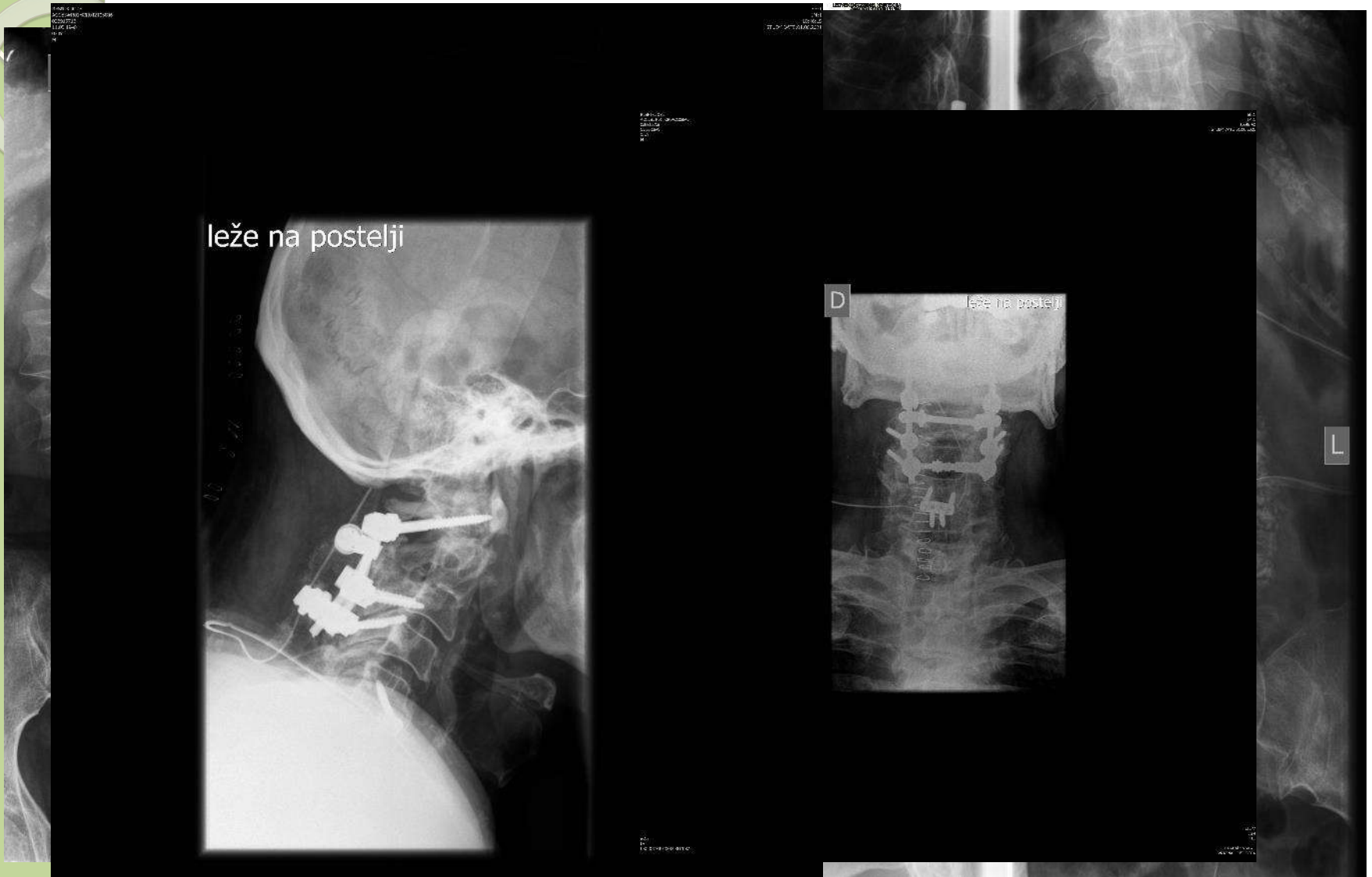

Kirurgija hrbtenice (kaj počnemo?)

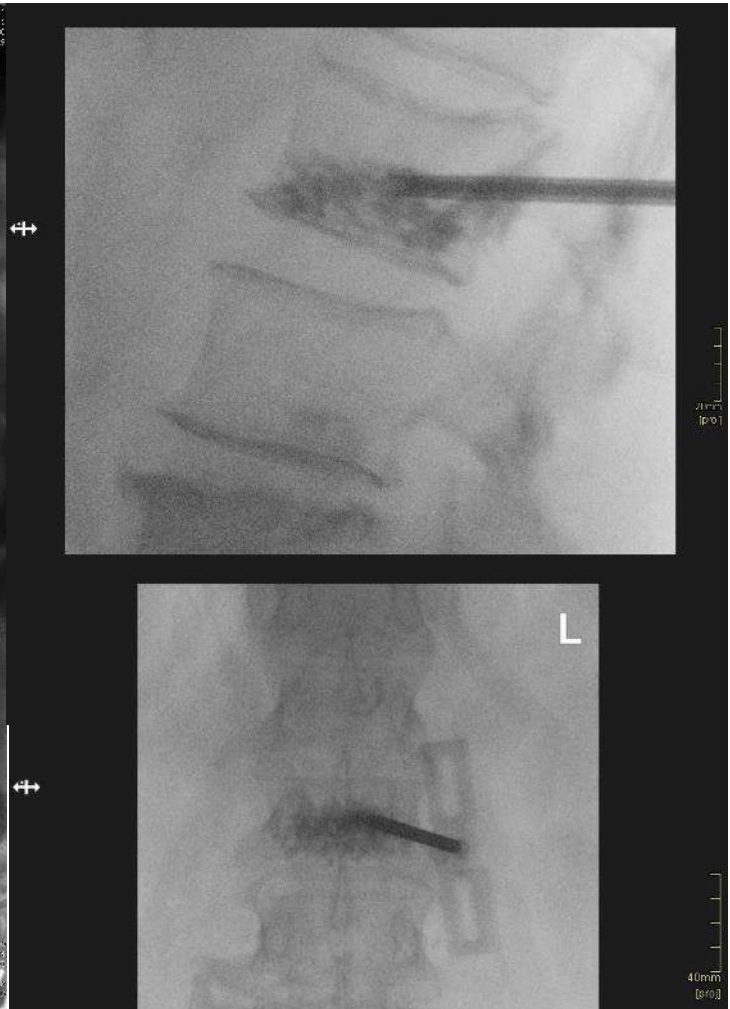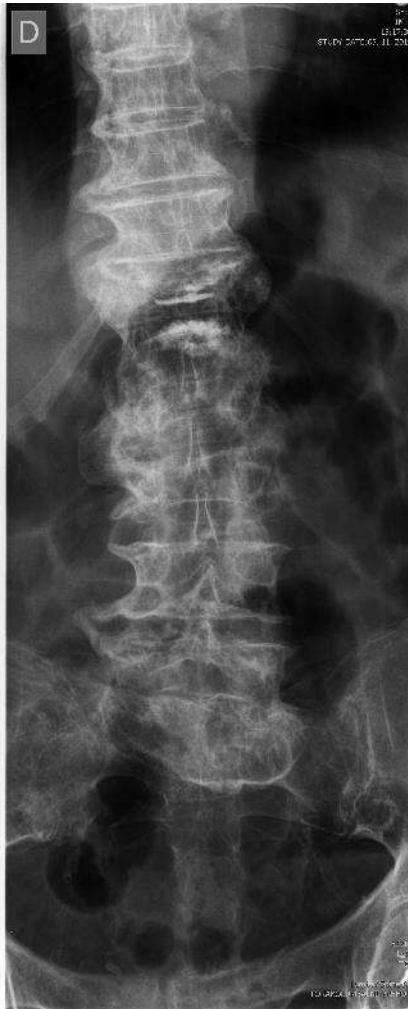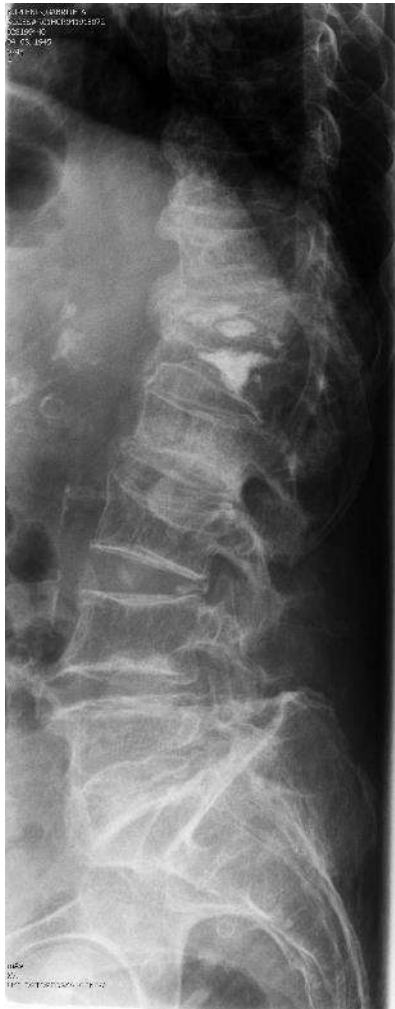Discektomija in dekompresija



Kirurgija hrbtenice (kaj počnemo?)

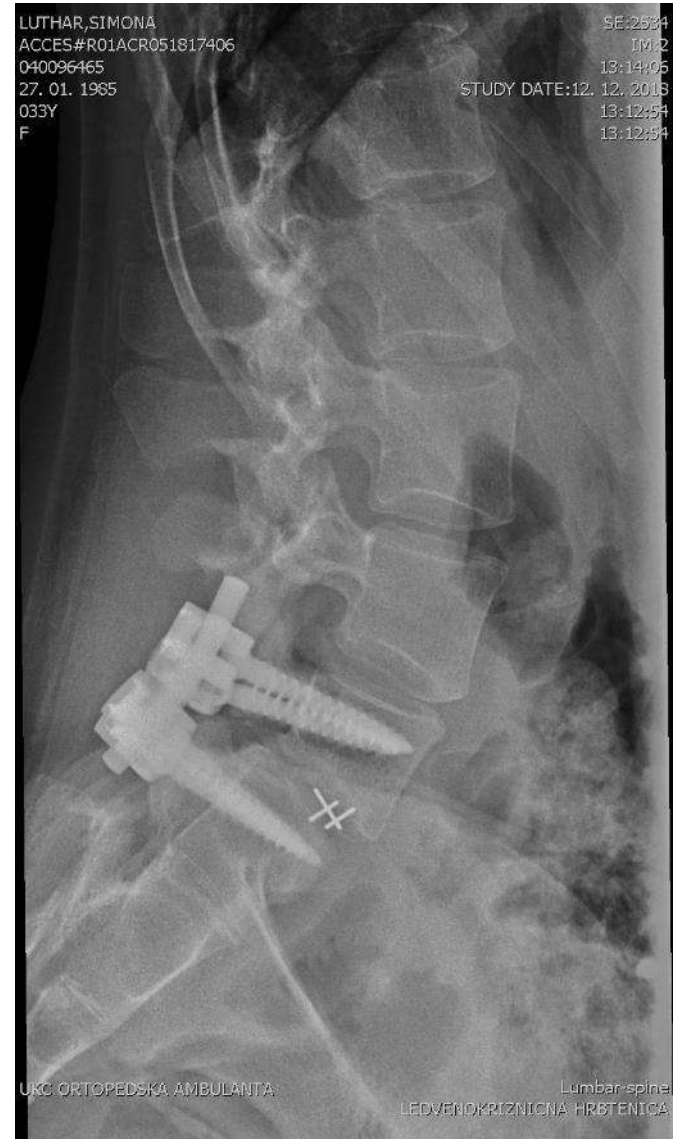
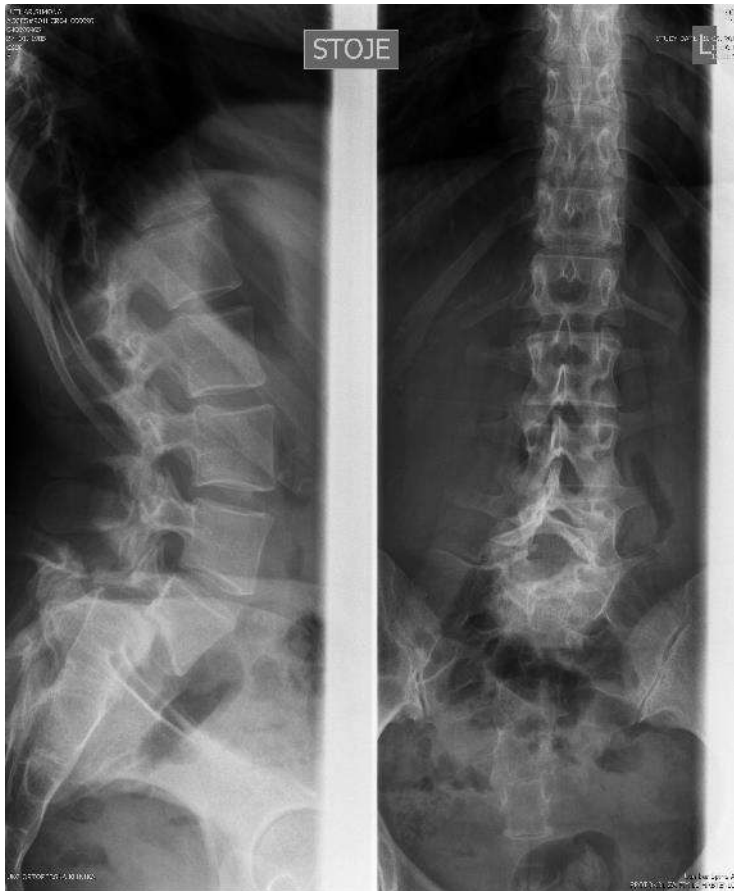


Kirurgija hrbtenice (kaj počnemo?)

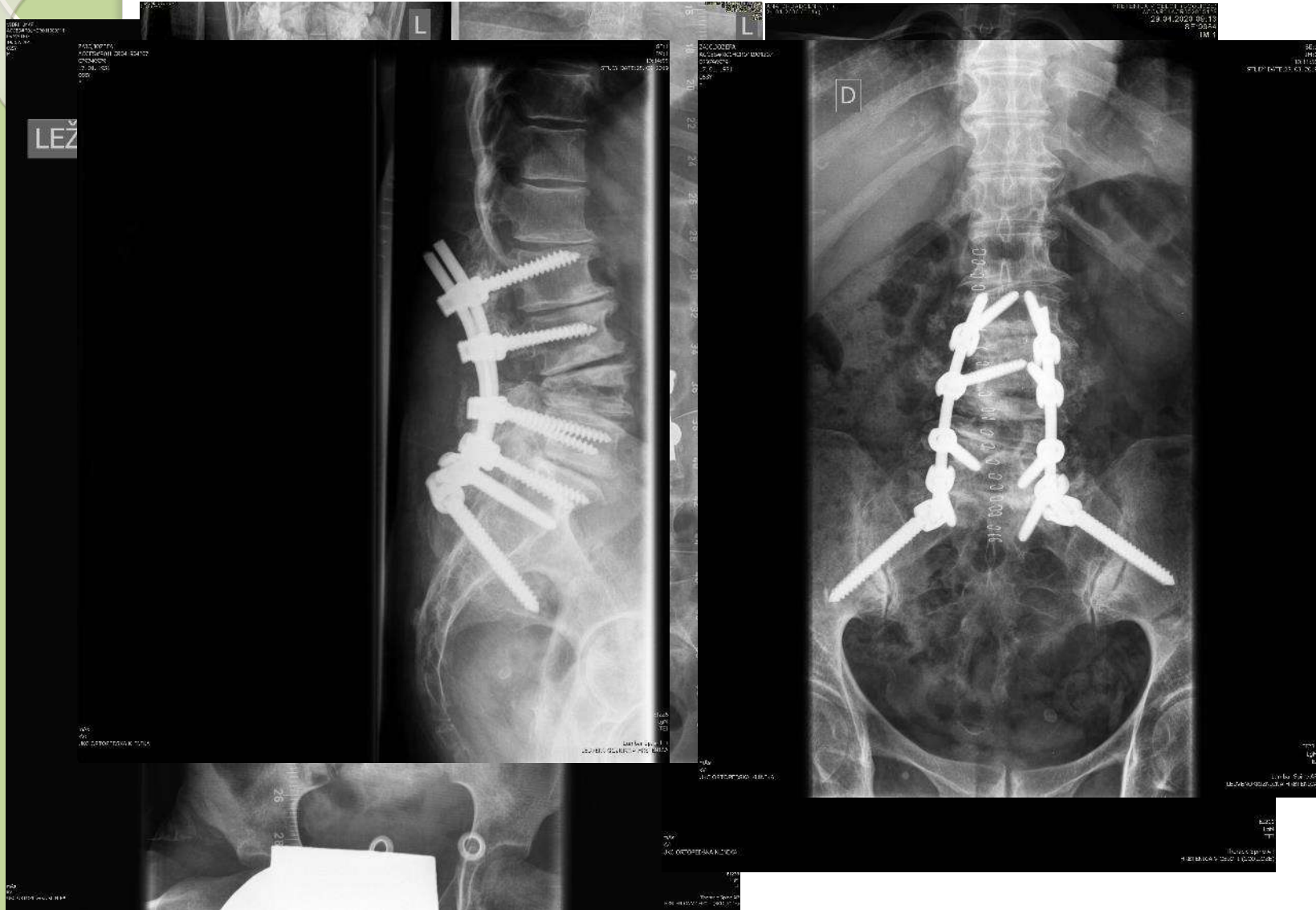

Kirurgija hrbtenice (kaj počnemo?)

- Displastična listeza

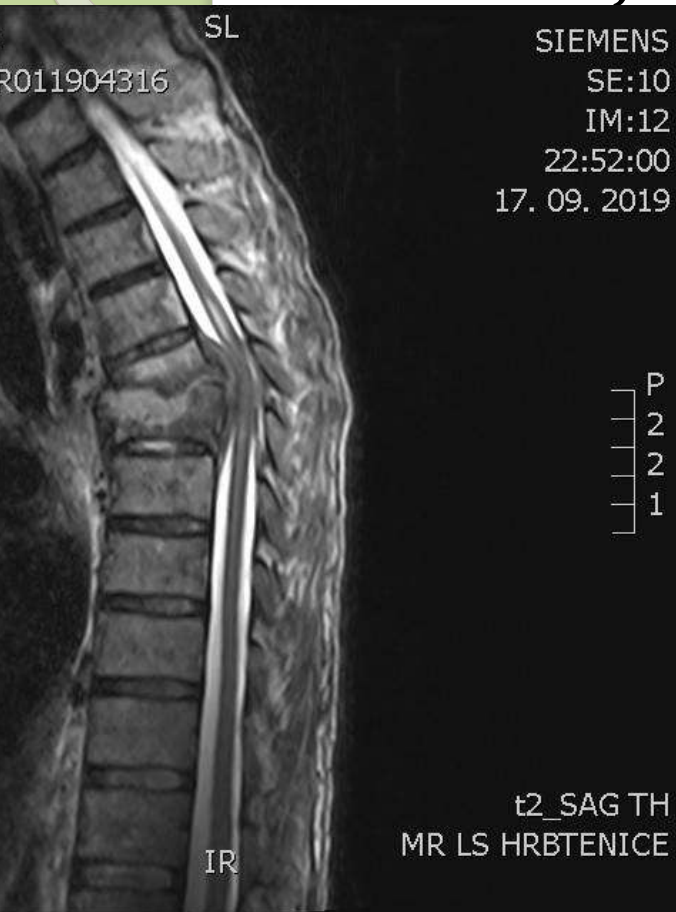

Kirurgija hrbtenice (kaj počnemo?)



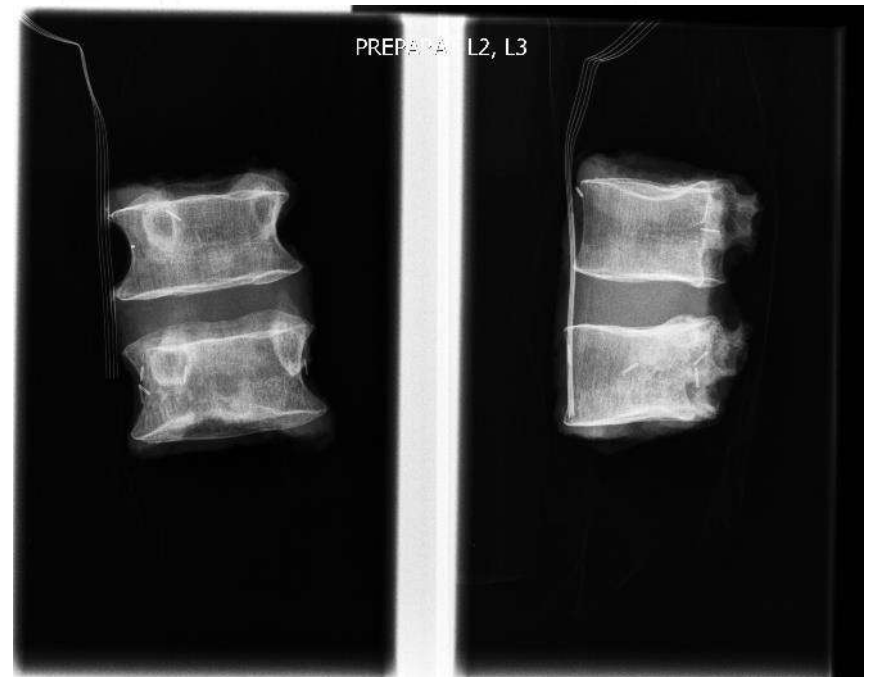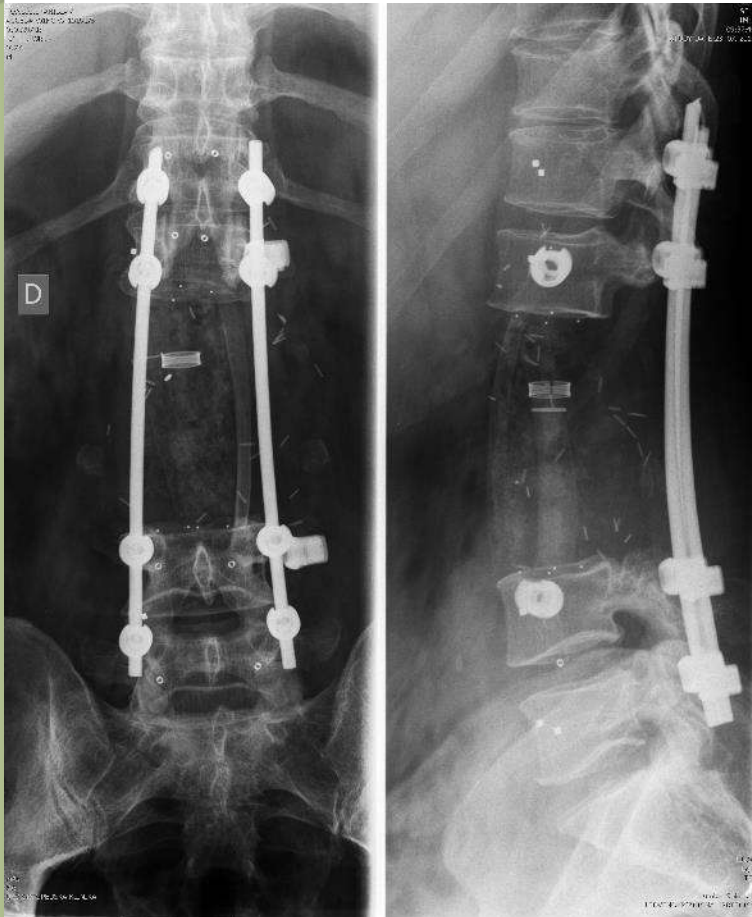Kirurgija hrbtenice (kaj počnemo?)

- Infekcije



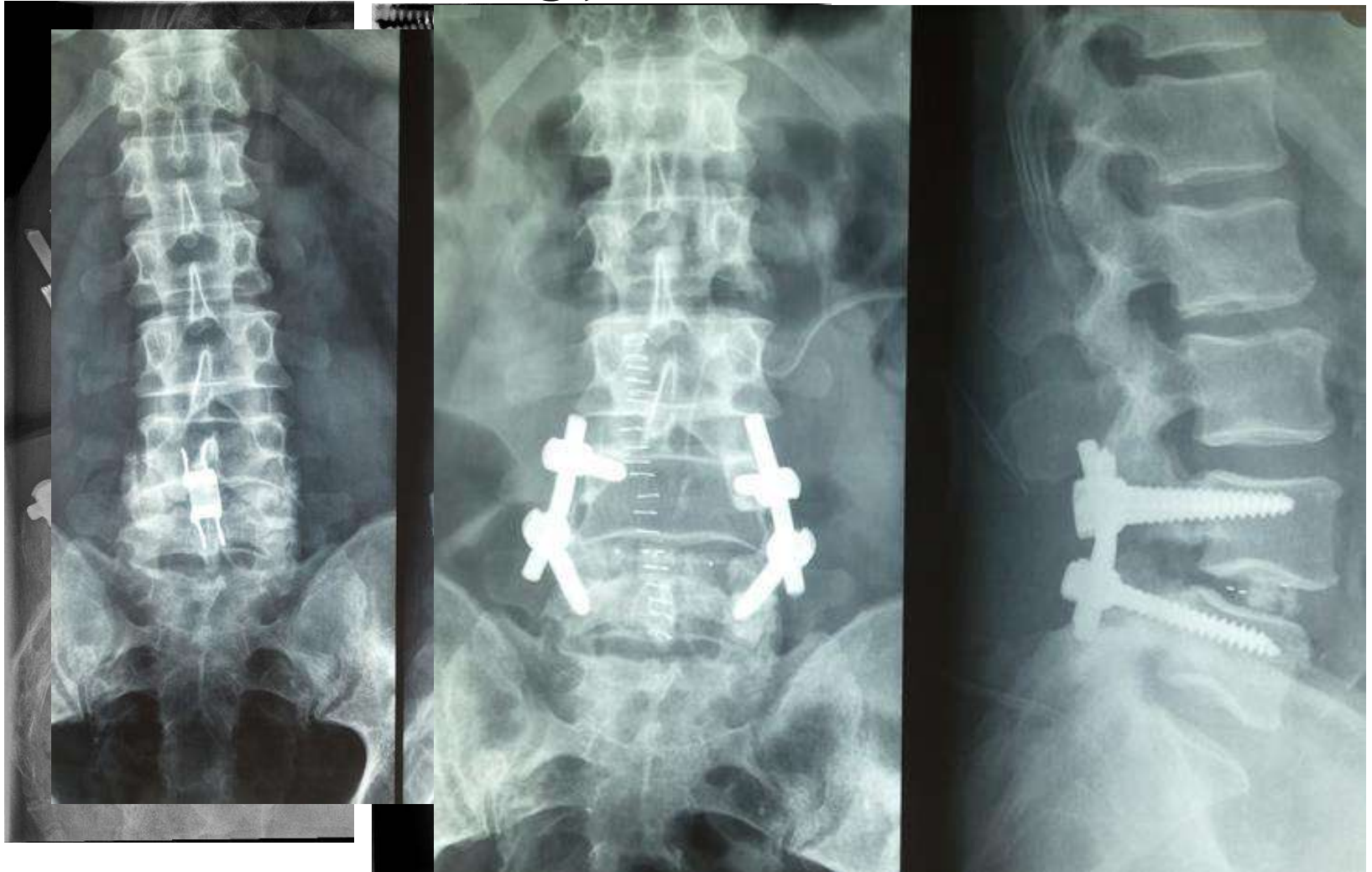
Kirurgija hrbtenice (kaj počnemo?)

- Tumor



Kirurgija hrbtenice (kaj počnemo?)

- Ponovna kirurgija



Sporočilo za domov

- Večina bolečin v hrbtenici je funkcionalnih in ne potrebuje kirurškega zdravljenja
- Ključen je temeljit klinični pregled in diagnostika
- Moderne kirurške tehnike omogočajo doseganje različnih ciljev zdravljenja
- Najpomembnejša je dobra indikacija
- Vedno je potrebno tehtati dobrobit pacientu v primerjavi z možnostjo komplikacij

Plan predstavitve

- Osnovni pregled področja (10 min)
- Pacient s težavo s hrbtenico (10 min)
- Bolezni hrbtenice (10 min)
- Kirurgija hrbtenice (kaj počnemo?) (10 min)
- **V&O (5 min)**