



Neck masses

SURGERY UPDATES

A Lump In The Neck — What To Do**

K.H. Lam*, MS, FRCSE, FRACS, FACS
W.L. Wei, FRCSE, DLO, FACS
C.M. Ho, FRCSE
S.K. Lau, FRCSE, DLO
L.K. Lam, FRCSE
Department of Surgery
University of Hong Kong

lesion likely to give rise to a lump, and what are the most frequent pathologic likely to be encountered in the local... Together with this information, the avail findings will allow a provisional diag made, and further confirmatory inves the appropriate treatment to be reco

Surgical Anatomy

For detailed anatomy of the are referred to standard texts of: outline is given herein (Figure 1

Summary

A lump in the neck is a common clinical problem. Its pathology varies according to the location of the lump. Remembering the anatomy in the neck and awareness of the pathological processes surrounding the anatomy allows a clinical diagnosis to be made. Peculiar to the population in Hong Kong, two more frequently seen pathological were tuberculous lymphadenitis and metastatic lymph node

Vinko Kambič
Janez Fischinger
Nina Gale
Lojze Šmid
Marjeta Vovk
Miha Žargl
Avgust Župevc

Žleze
slinavke
in
ščitnica

Maligni
tumorji
in
metastaze

Prirojene
nepravilnosti

Vnetja

otekline na v

Review of Clinical Signs

Series Editor: Bernard M. Karnath, MD

Approach to the Patient with Lymphadenopathy

Bernard M. Karnath, MD

Lymphadenopathy refers to one or more lymph nodes that are abnormal in size, consistency, or number. Lymphadenopathy can be due to a benign, self-limited process or may be due to a serious underlying disease. Infections, malignancy, and immunologic disorders account for most cases of lymphadenopathy (Table 1). This article reviews the diagnostic approach to the patient with localized or generalized lymphadenopathy and discusses common, important systemic illnesses that may cause generalized lymphadenopathy.

KEY FACTORS IN EVALUATION OF LYMPHADENOPATHY

Age of patient
Location of lymphadenopathy
Systemic signs/symptoms
Presence/absence of
Size, consistency

EVALUATION OF LYMPHADENOPATHY

Key factors to consider with lymphadenopathy

Postgraduate Medicine: Common ENT Problems Symposium: Is this lump in the neck... 1. stran od 9

The Practical
Peer-Reviewed
Journal
for
Primary Care
Physicians

Postgraduate Medicine online

about us | cme | home | issue index | patient notes | pearls | ad service

symposium

Is this lump in the neck anything to worry about?

How to recognize warning signs of an abnormal mass

William B. Armstrong, MD; Mark F. Giglio, MD

VOL 104 / NO 3 / SEPTEMBER 1998 /
POSTGRADUATE MEDICINE

This page is best viewed with a browser that supports tables

This is the second of four articles on common ENT problems

Preview: A patient comes in with a neck lump. Does he or she report voice or hearing changes and progressive enlargement of the lump? Are cervical lymph nodes fixed and firm? Is sensation or movement of the face limited? Do you find induration in the mouth or a mass in the thyroid or parotid gland on palpation? These are some high-risk findings that require further evaluation. In this article, the authors summarize the many causes, both benign and malignant, of neck masses in adults. They describe how to conduct history taking and physical examination to narrow the list of causes of the mass, and they provide recommendations for when to refer the patient to a neck specialist.

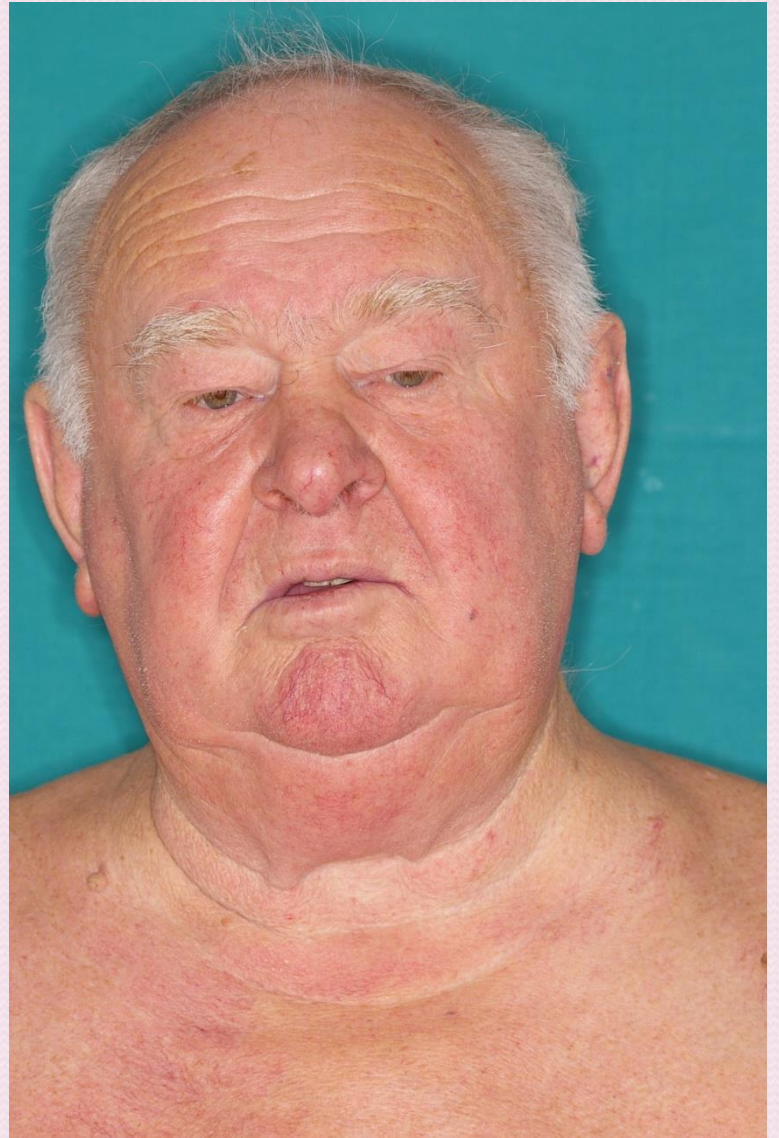
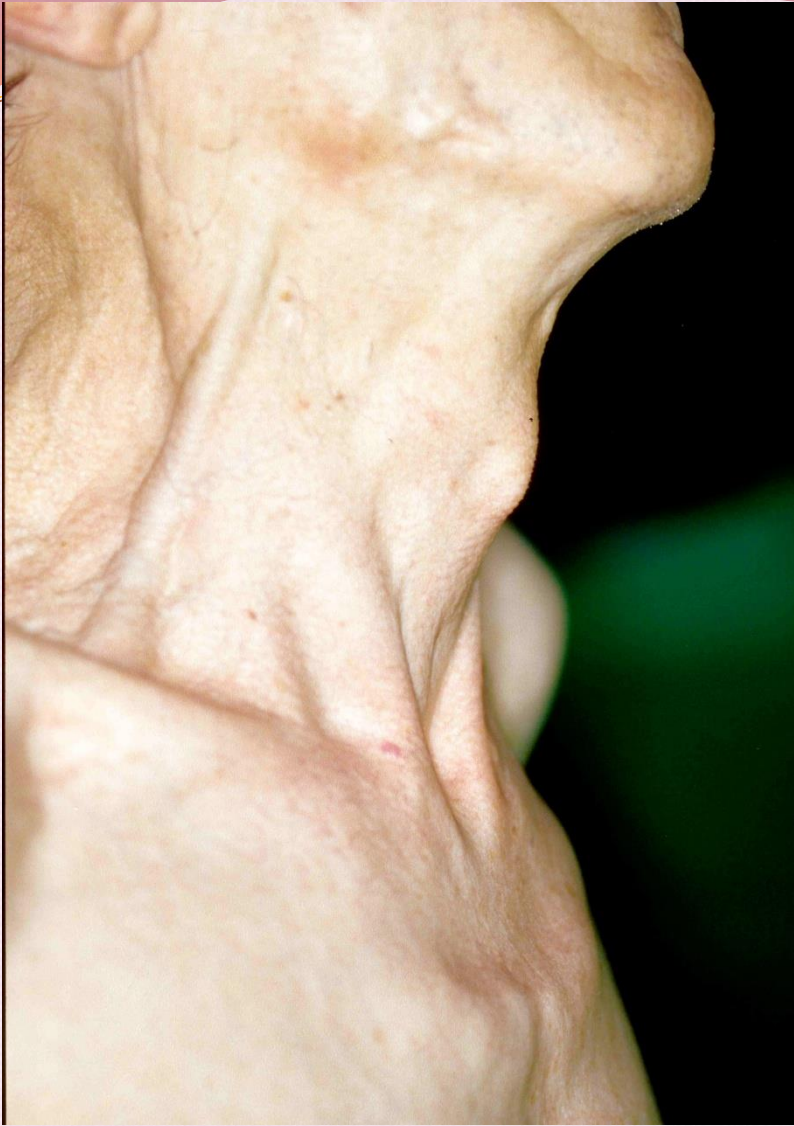
Search
Match ALL

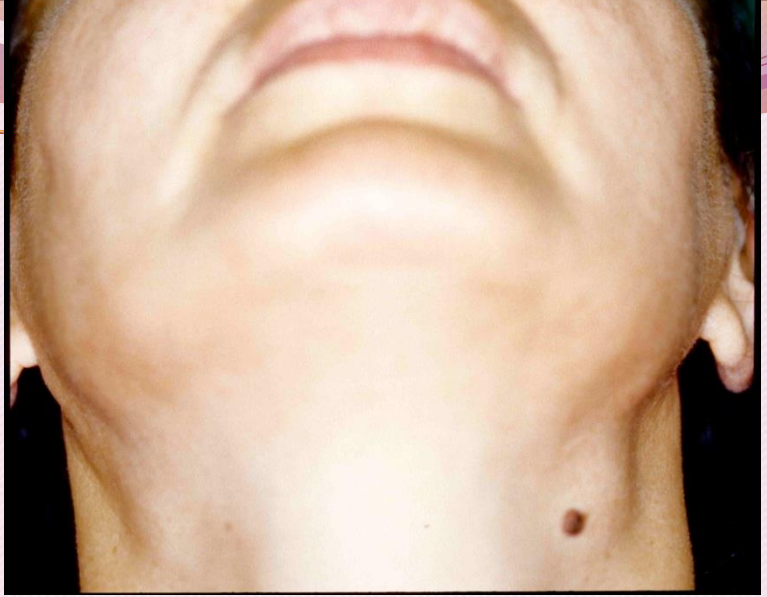
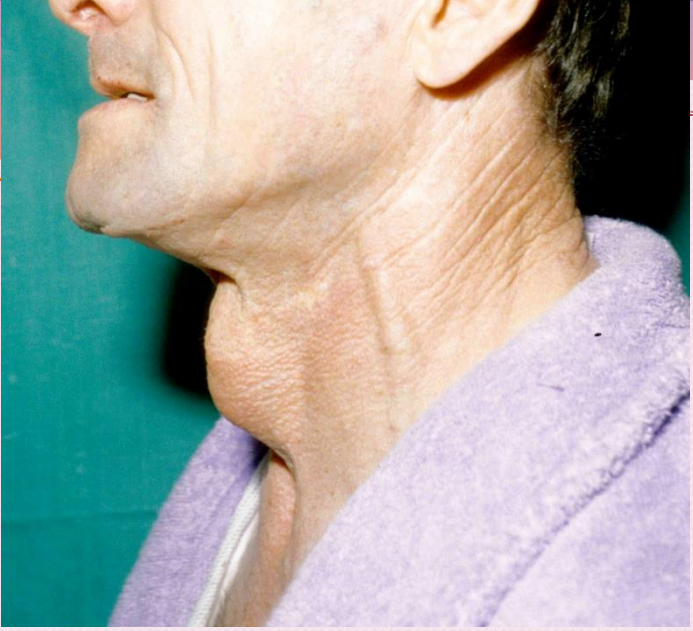FOCUS ON

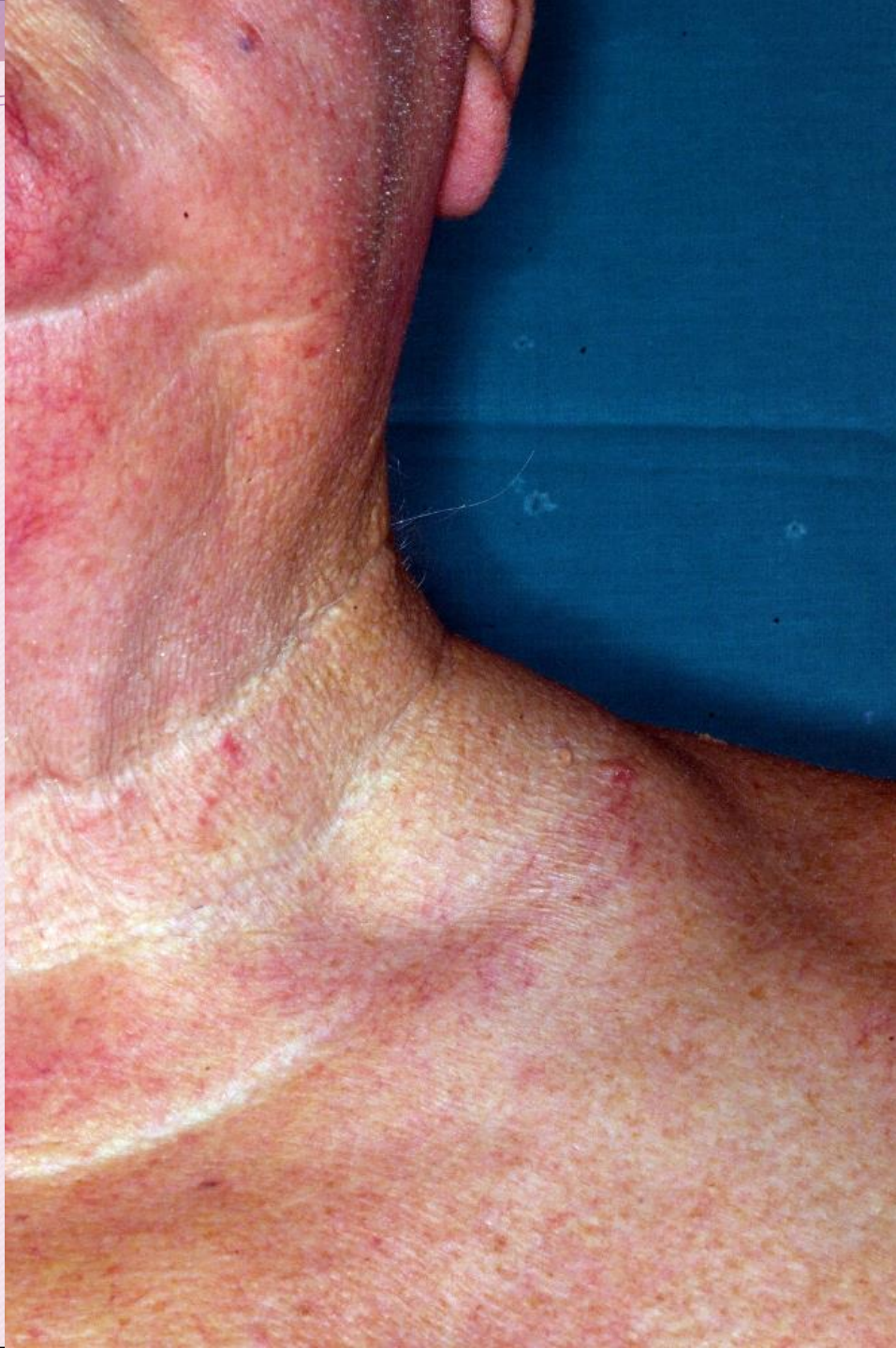- CVD
- Diabetes
- Geriatrics
- Men's Health
- Rheumatology
- Women's Health
- current issue
- web exclusives
- subscriptions

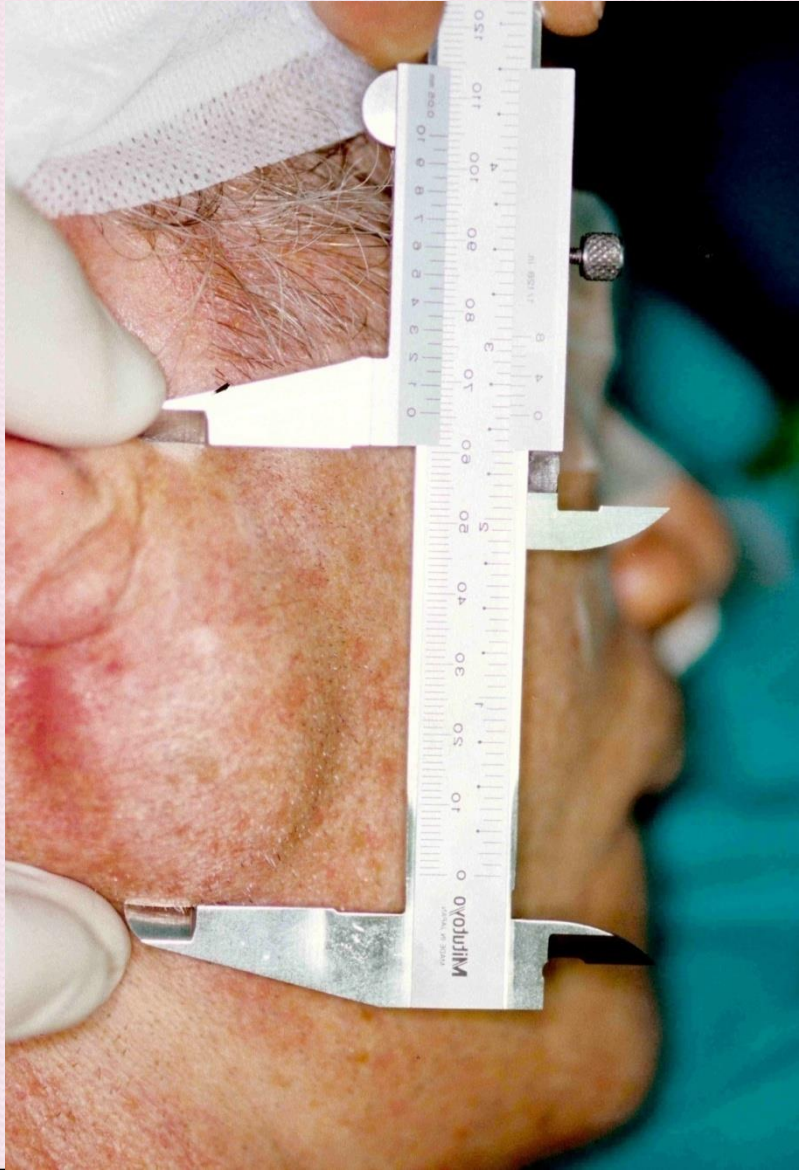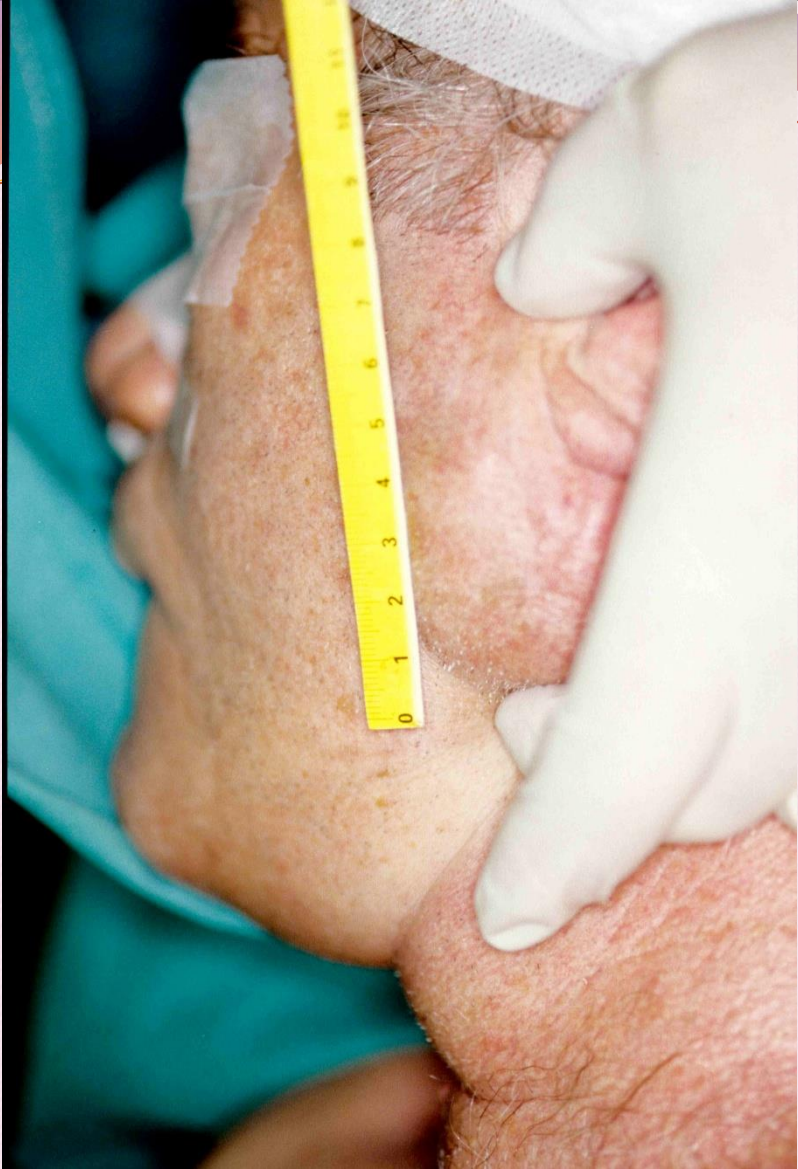The most common neck masses

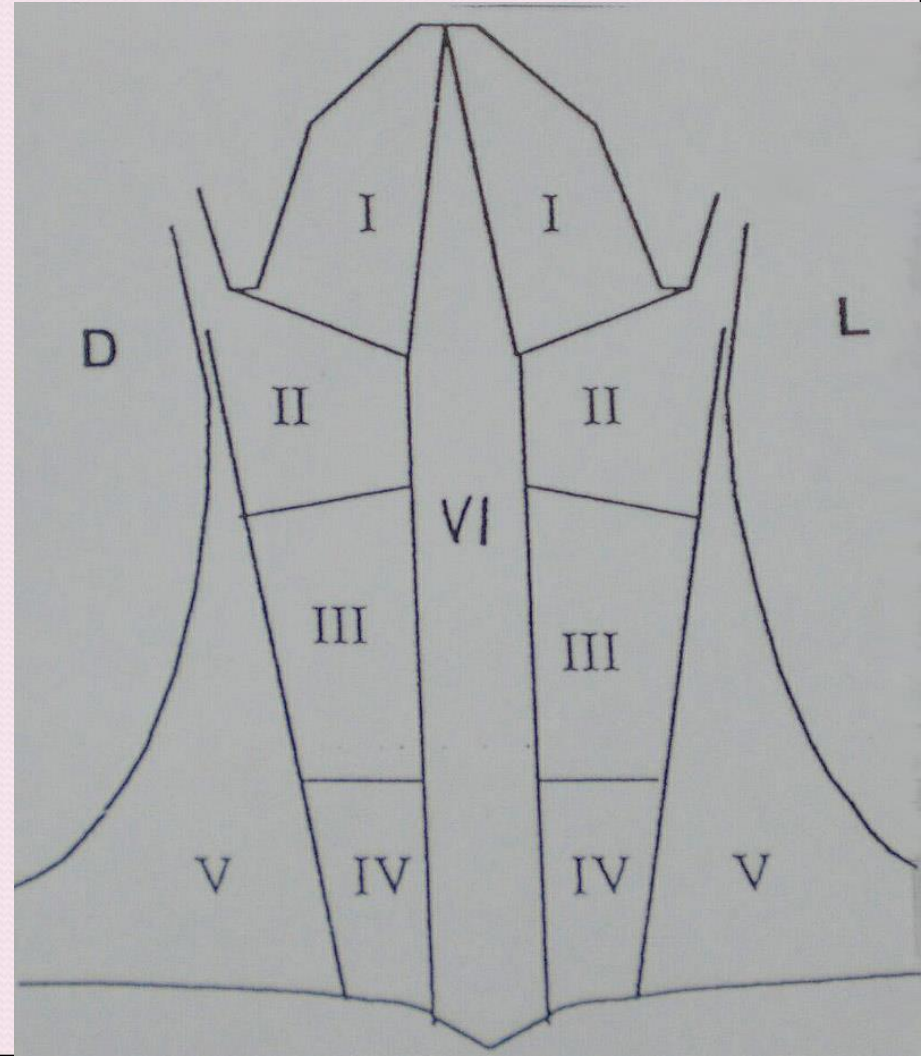
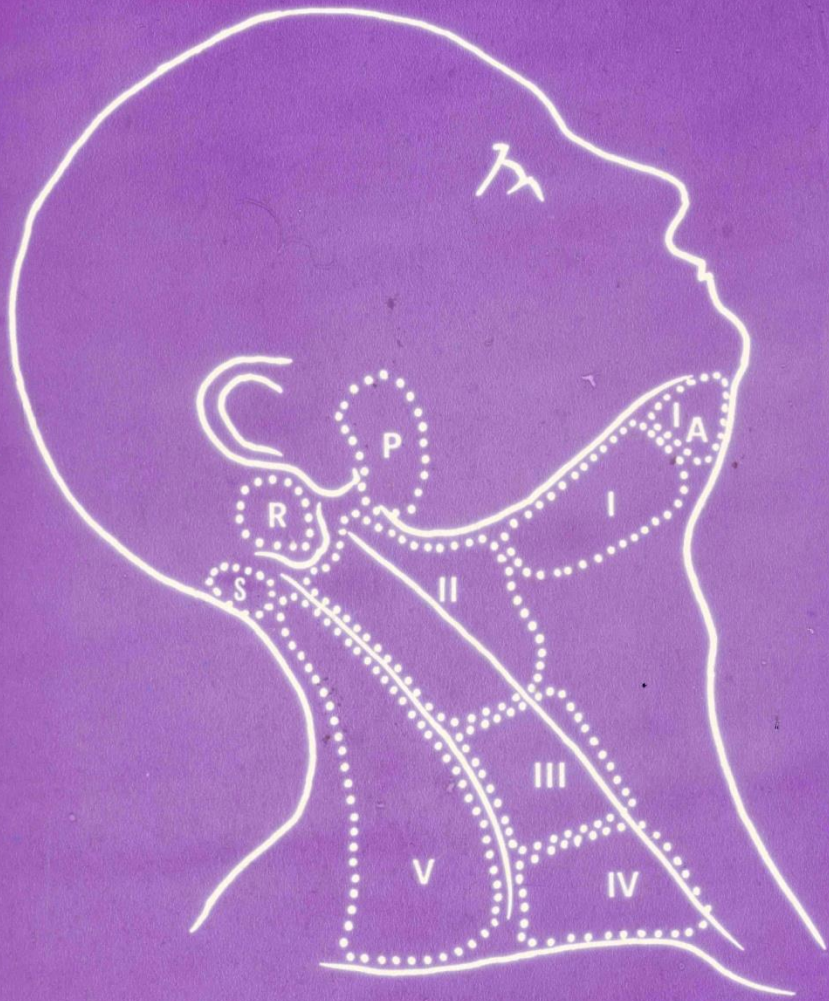
- Anatomical characteristics
- Congenital malformations
- Injuries
- Local inflammation
- Systemic infections
- Benign tumors
- Malignant tumors
- Metastases
- Systemic malignant diseases











14HZ


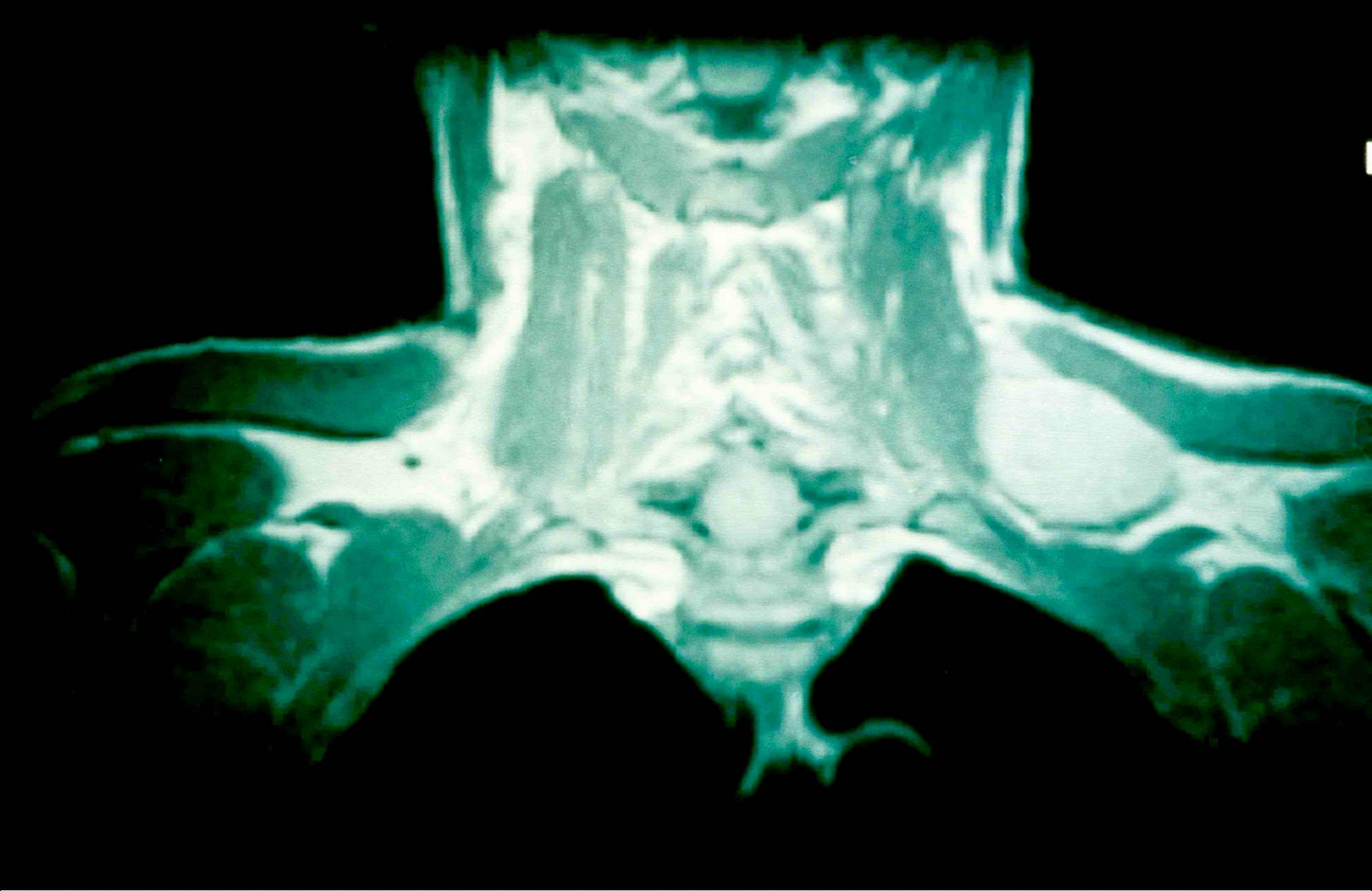
1+ +

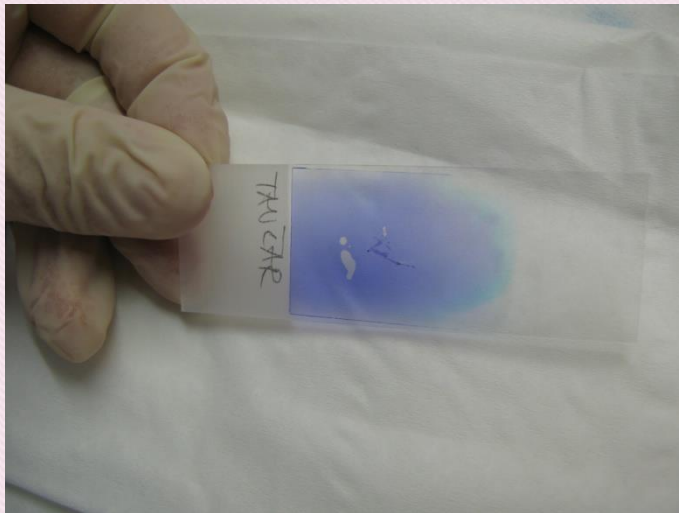
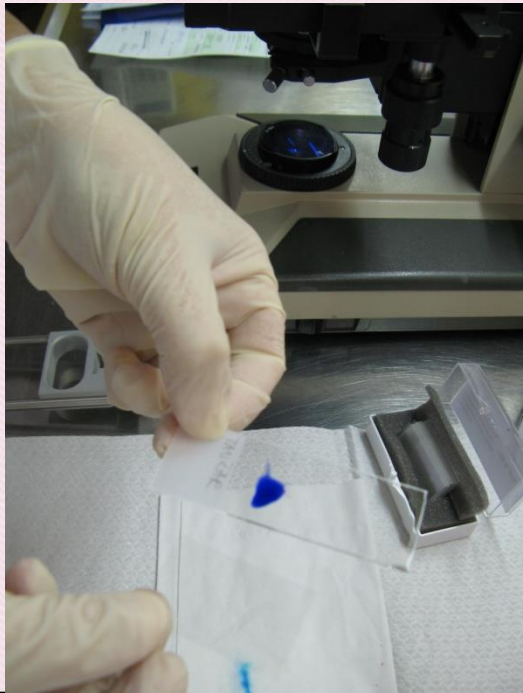
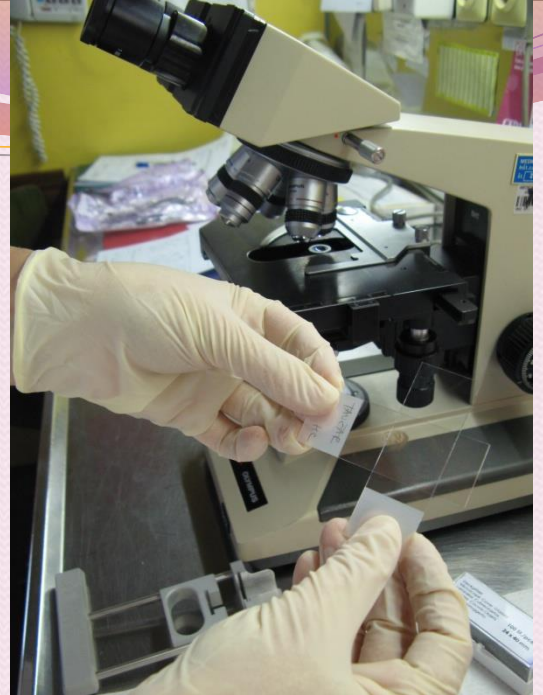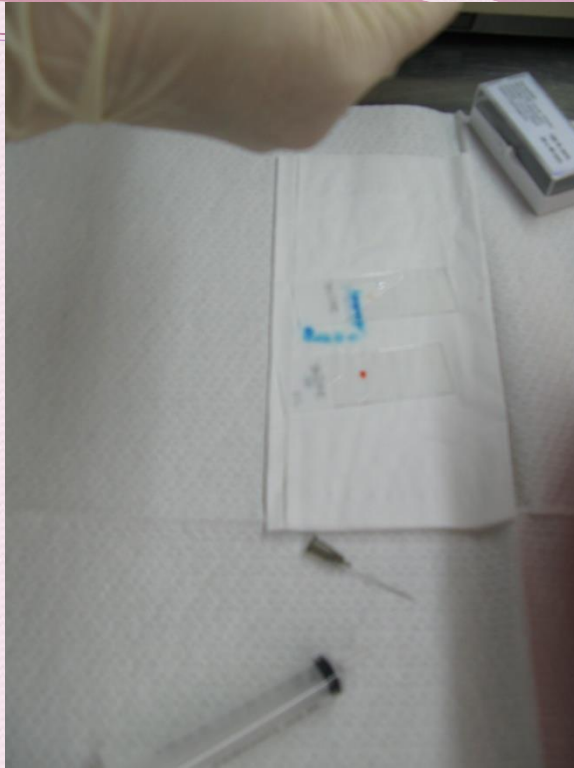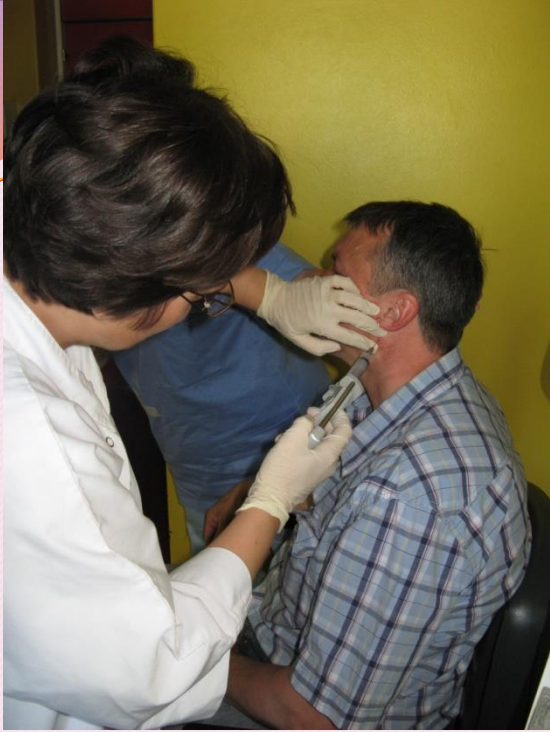2X X

L7.50
14HZ



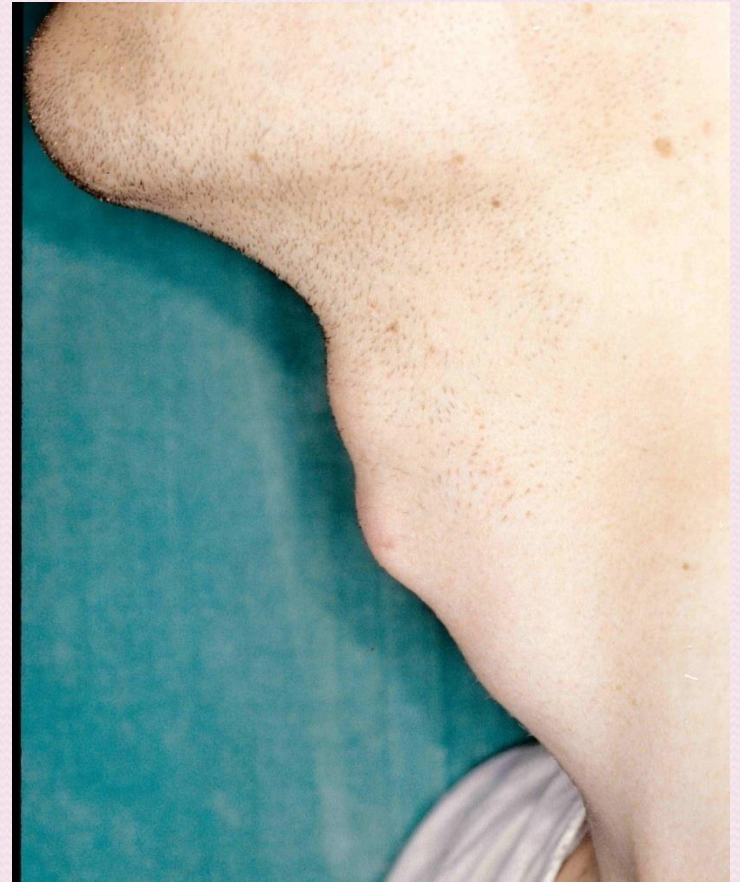
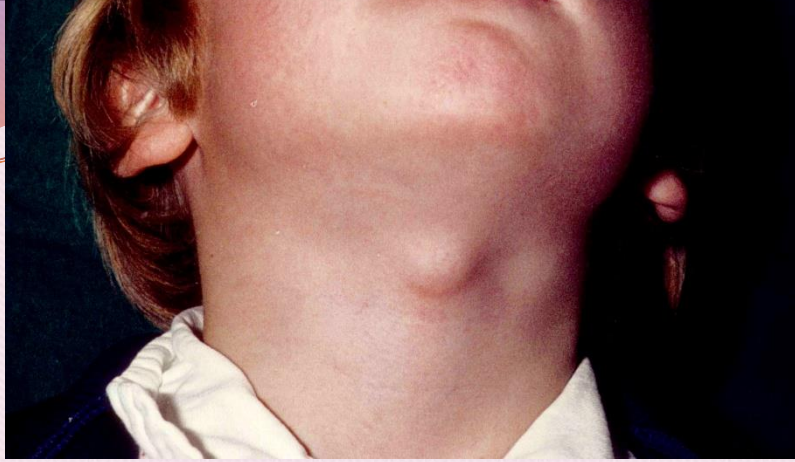DESNO VRAT / LGL

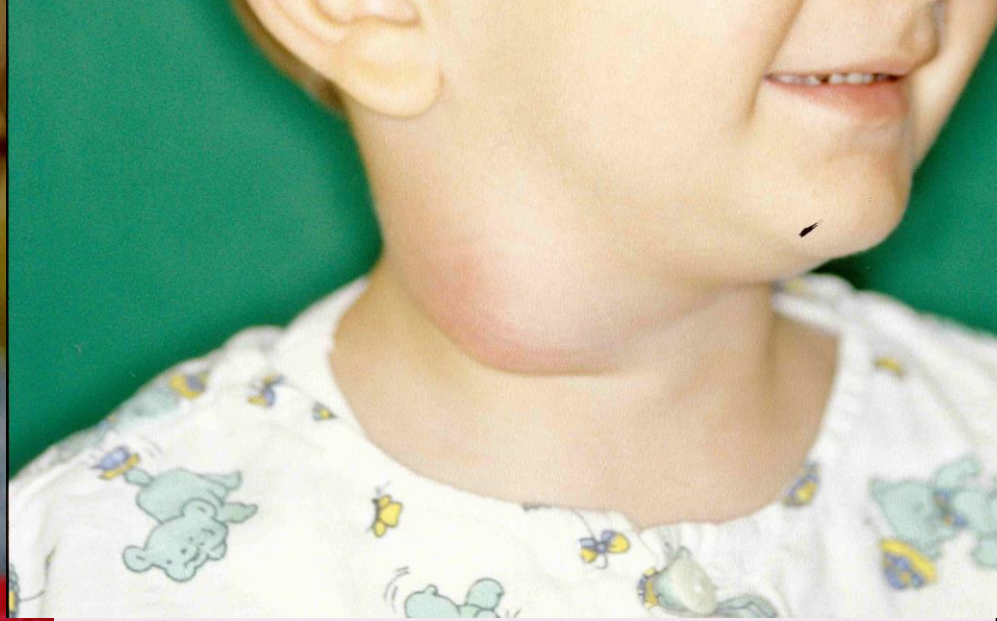
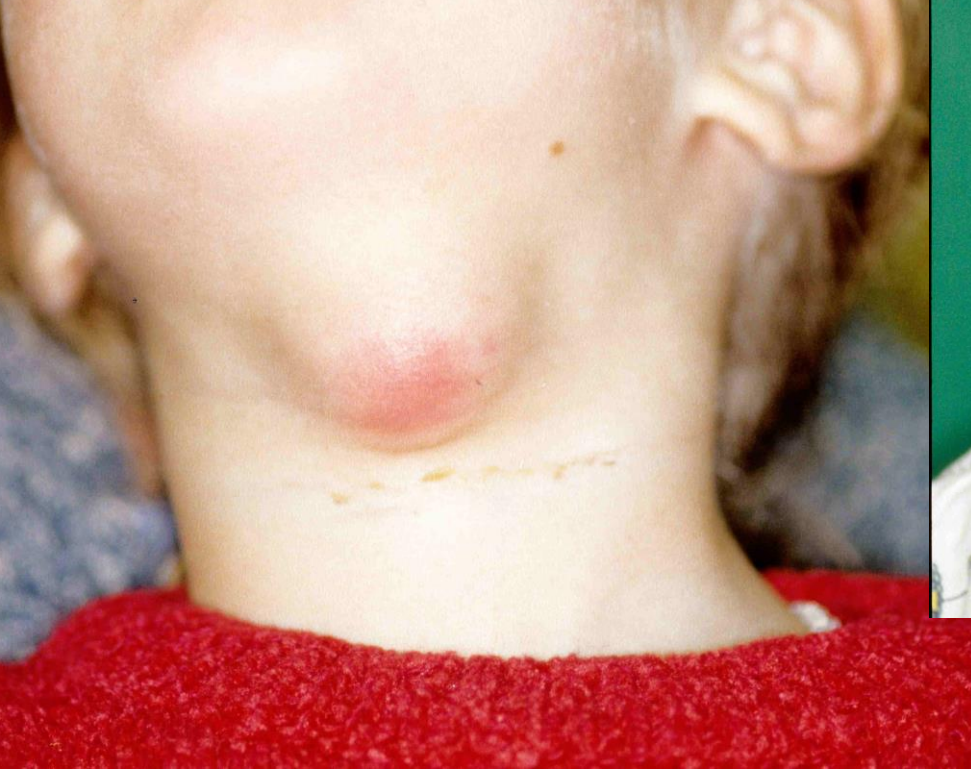

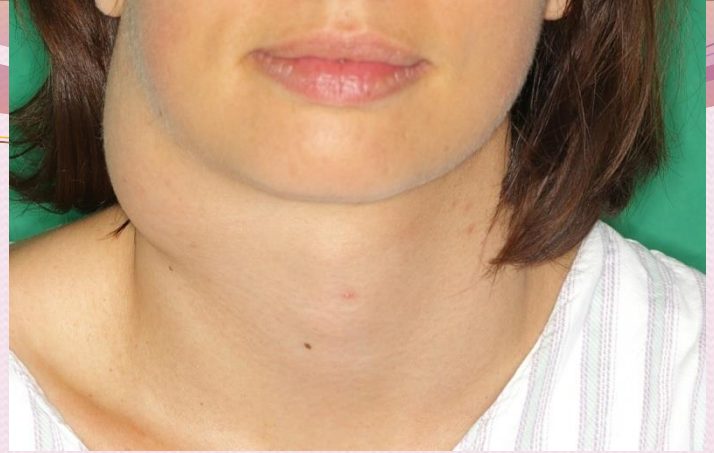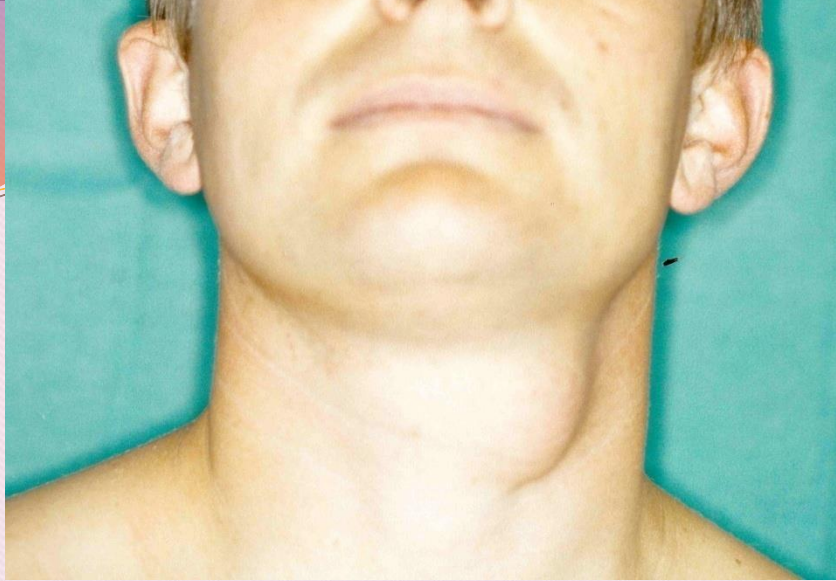




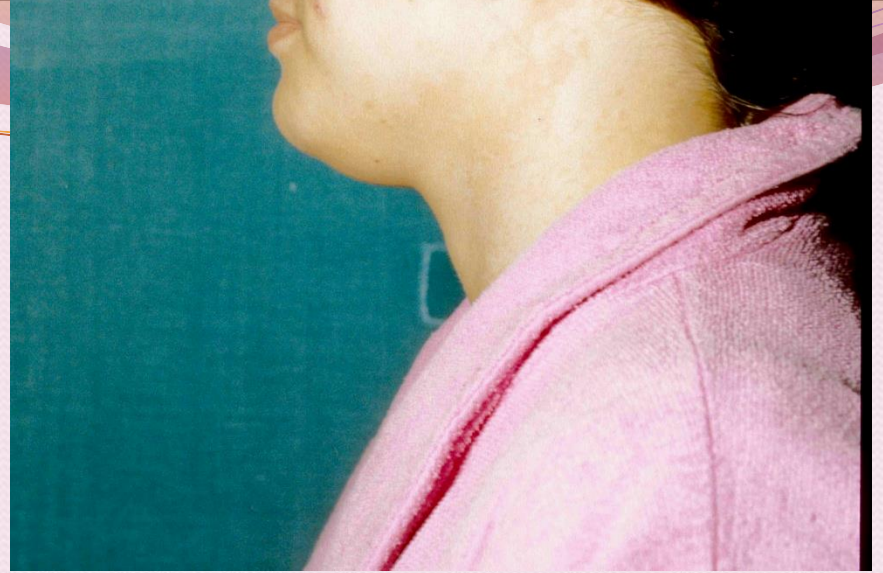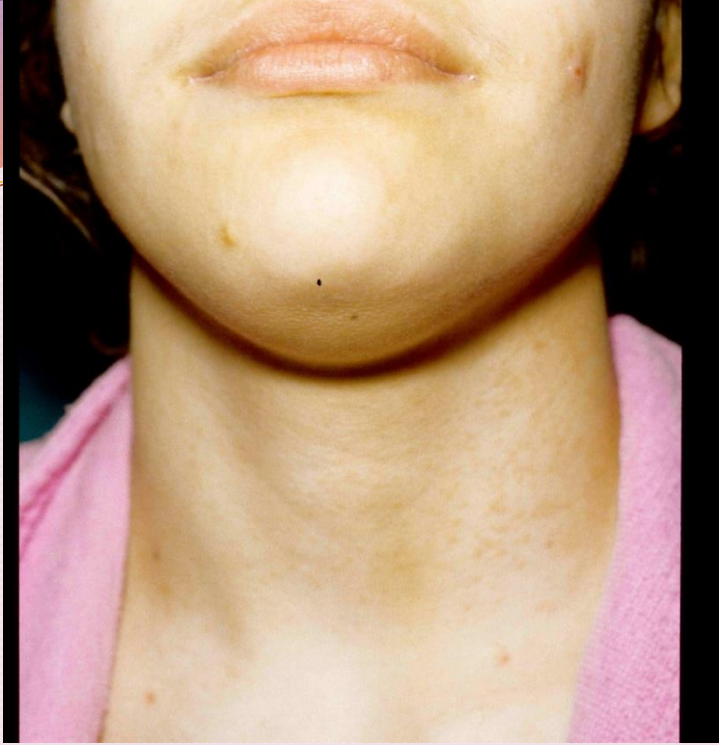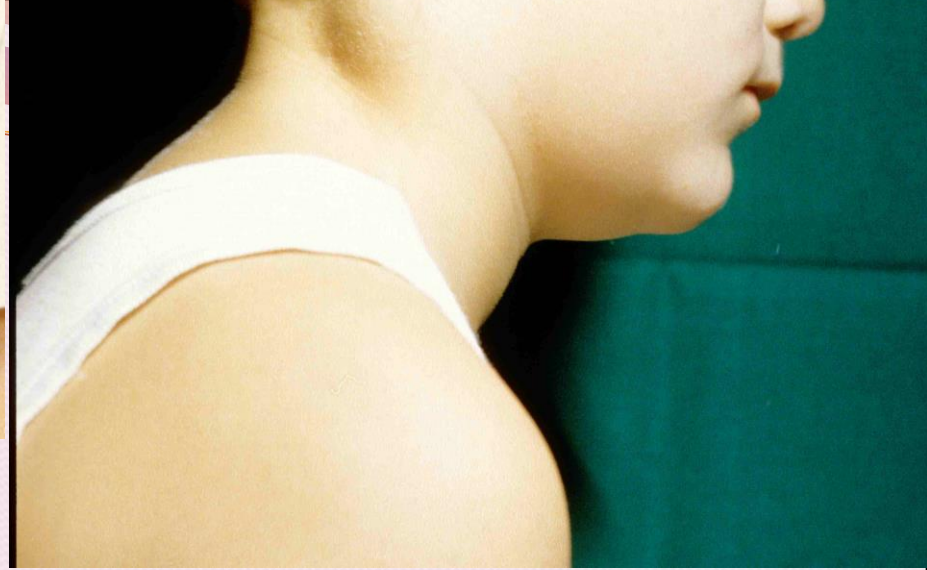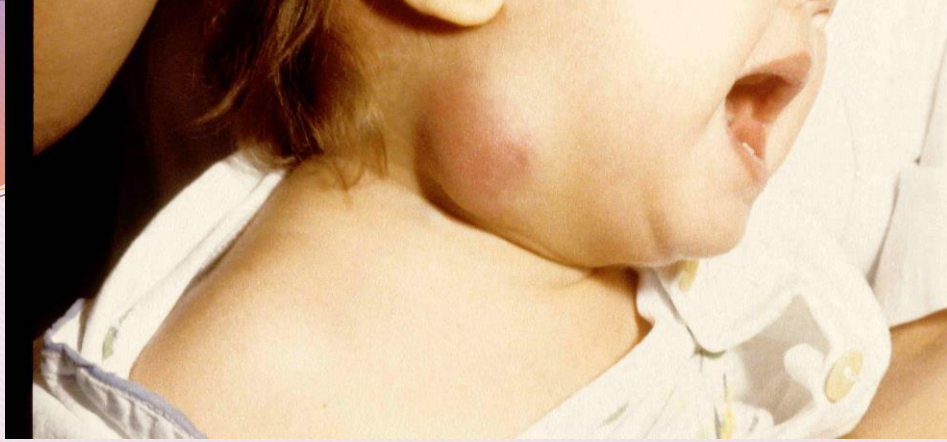Congenital malformations

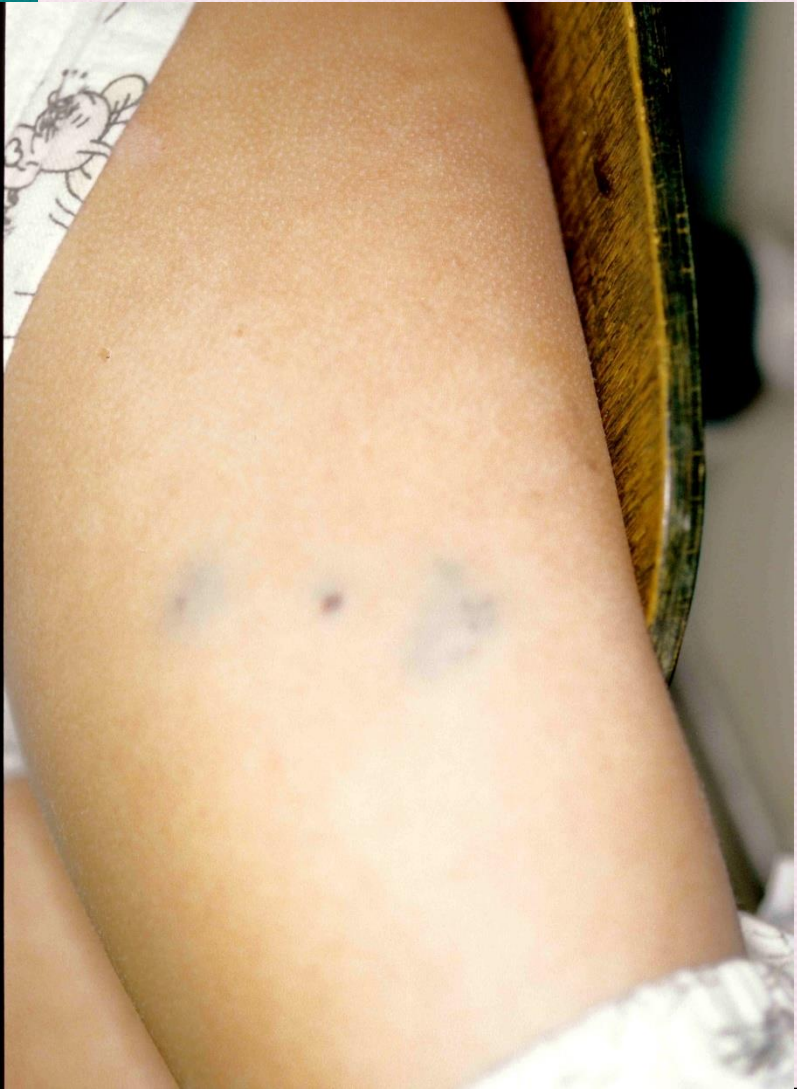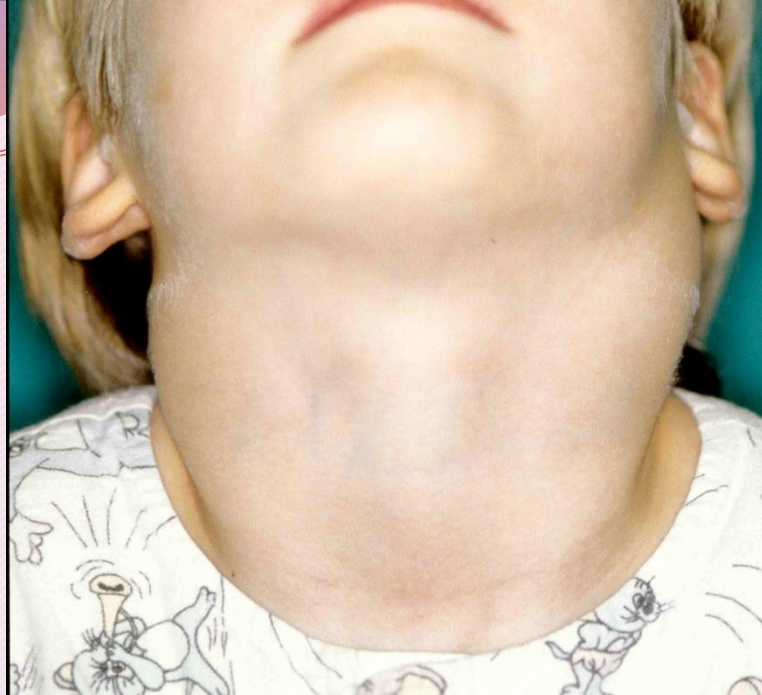



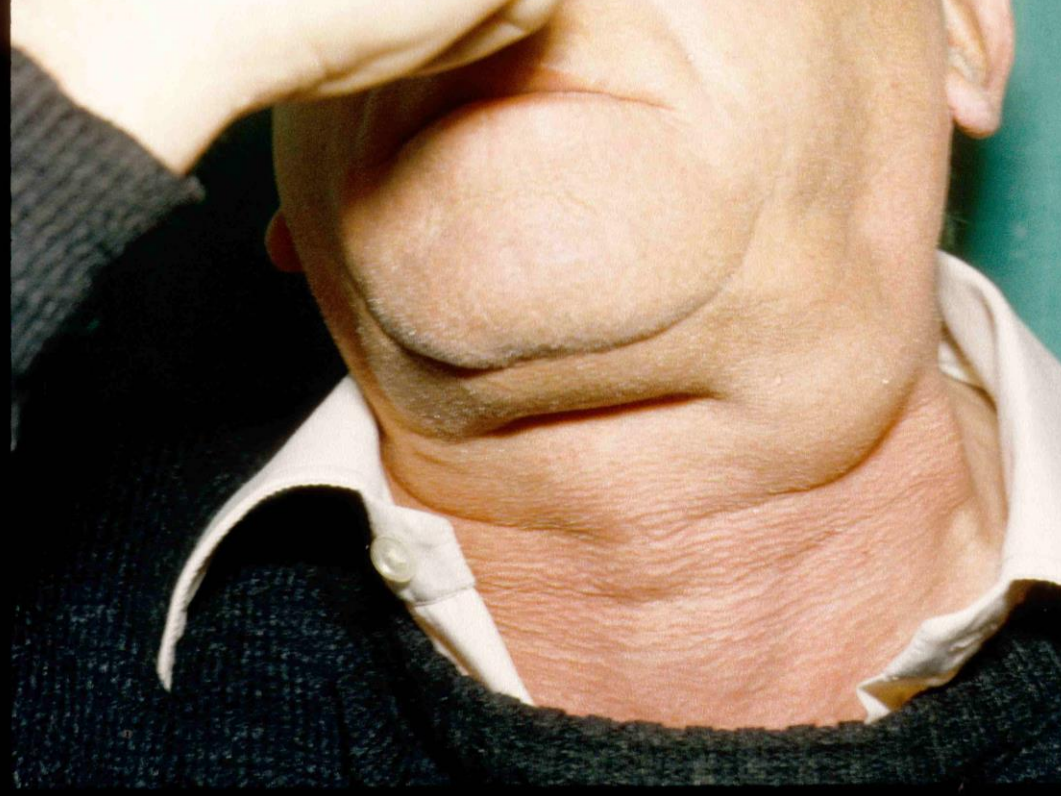
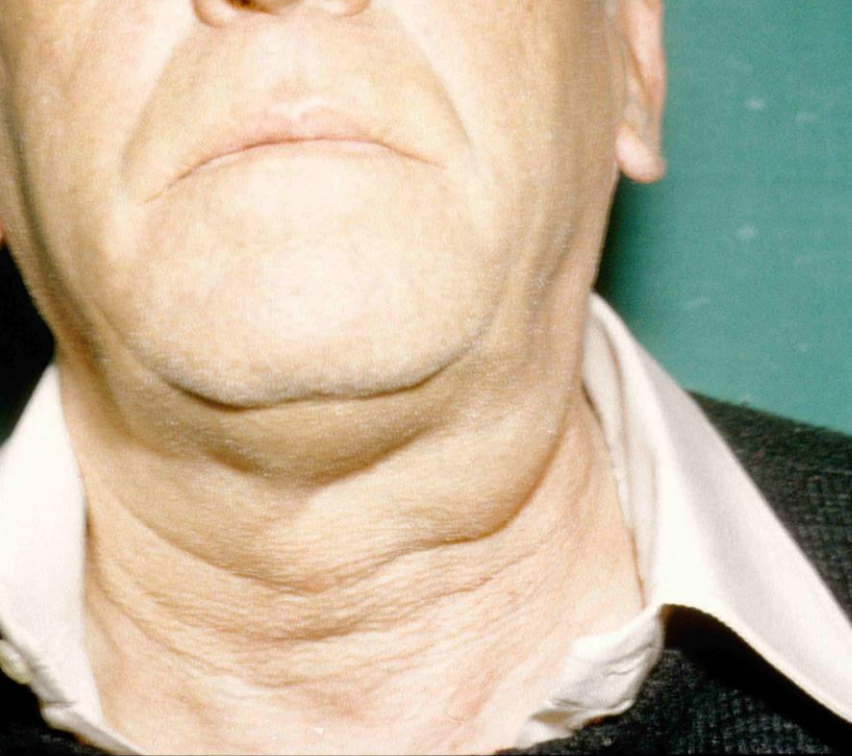






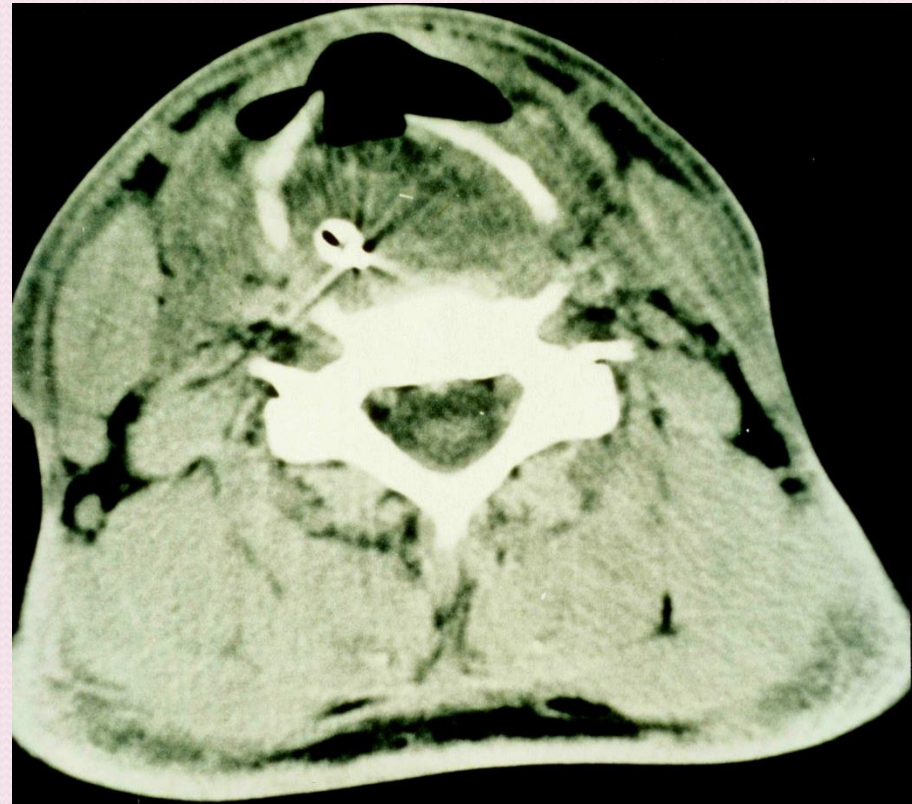
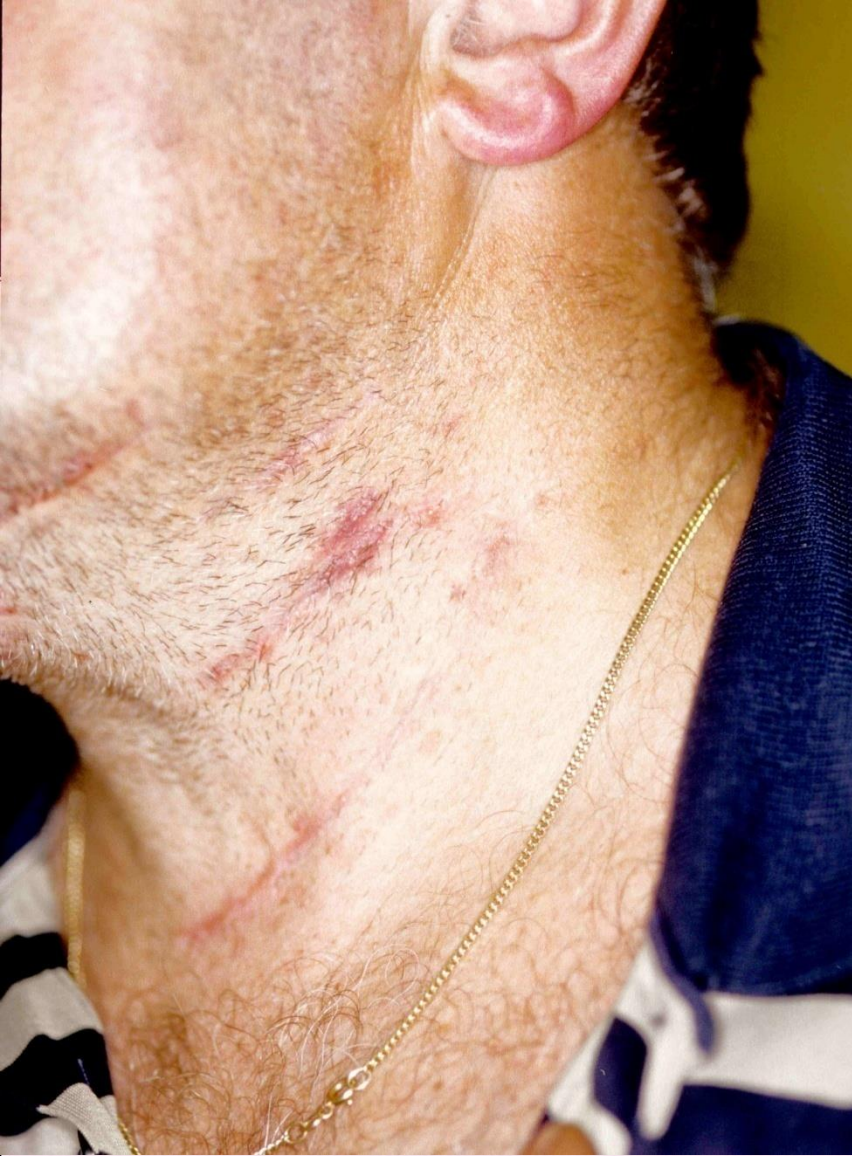


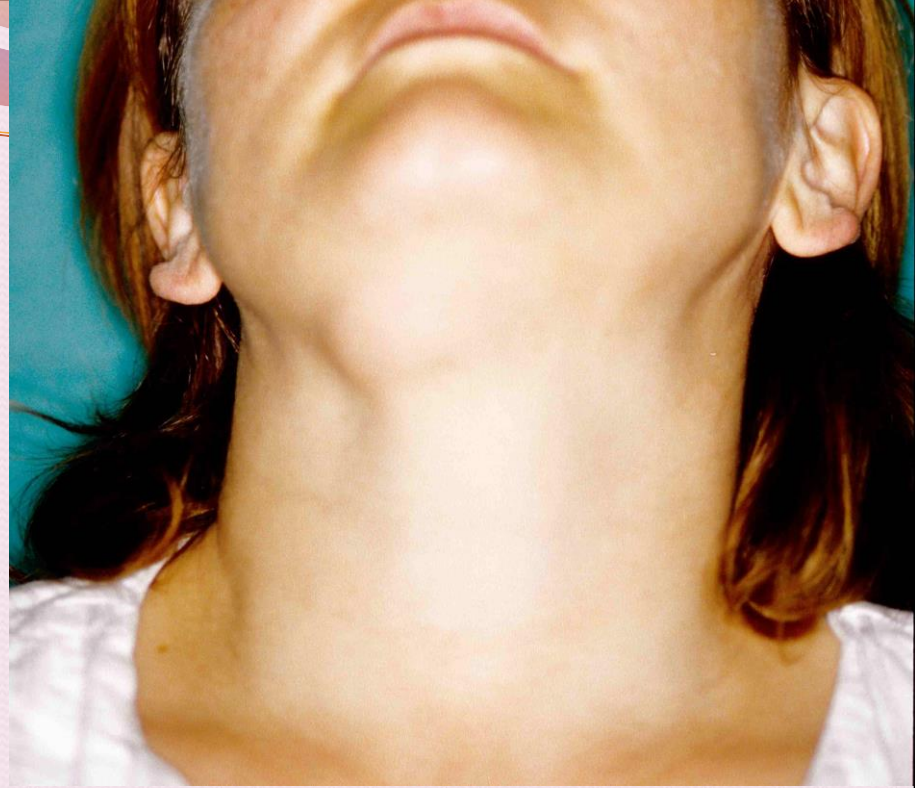


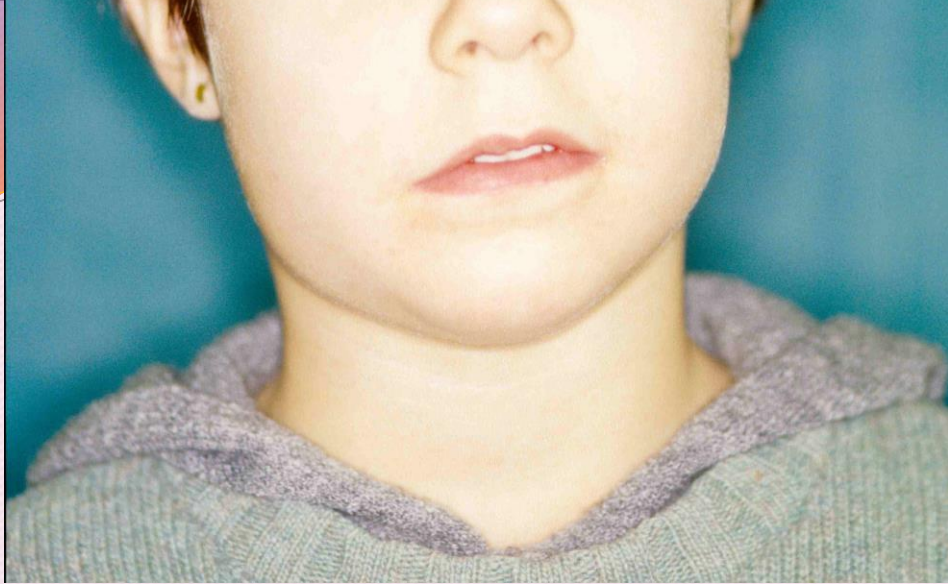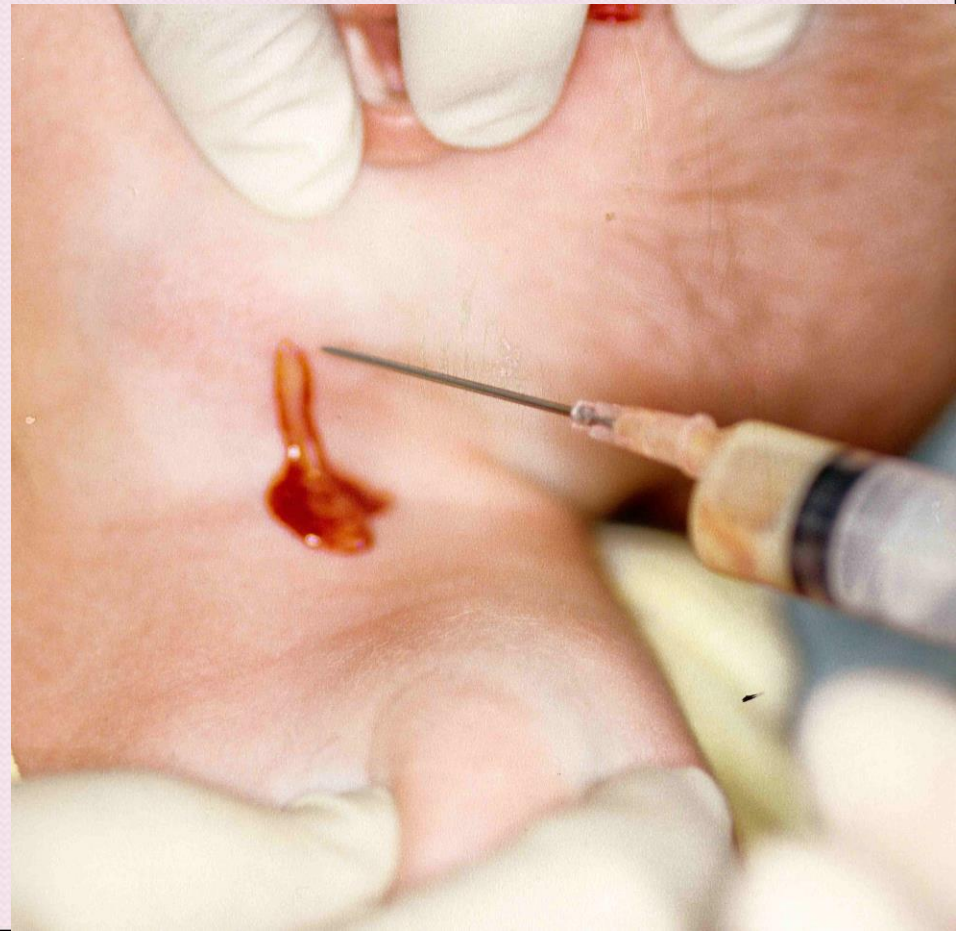
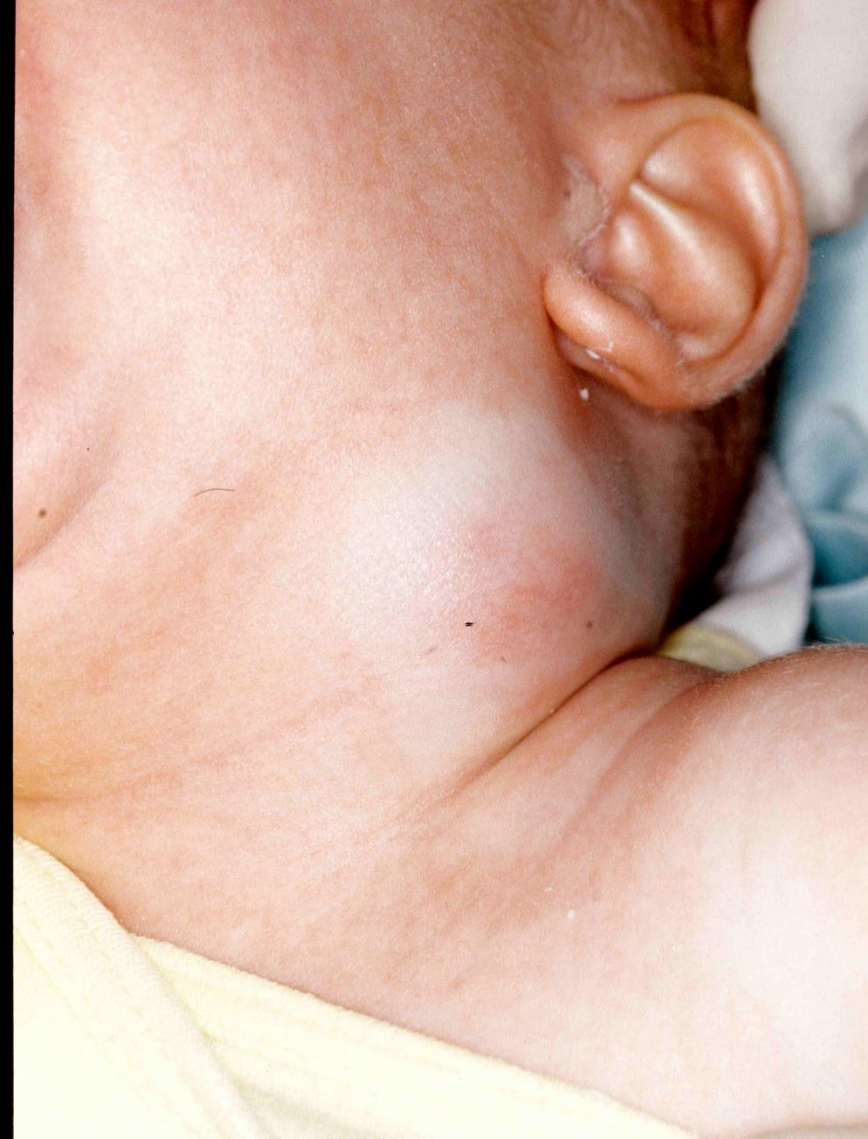Injuries

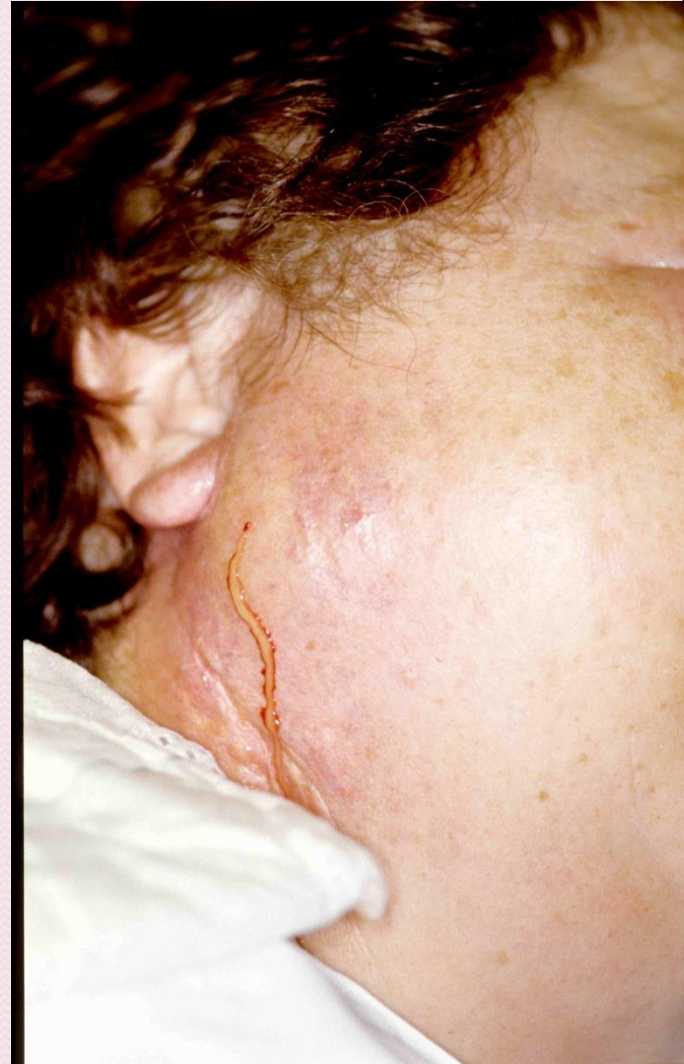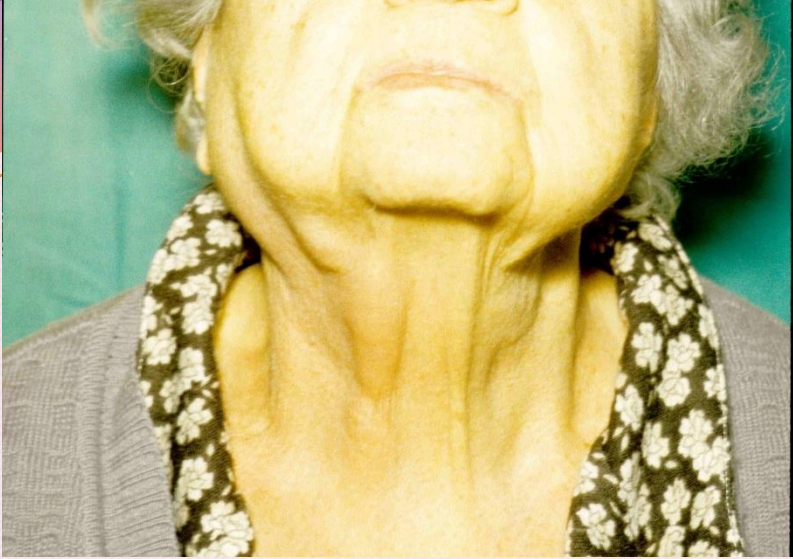



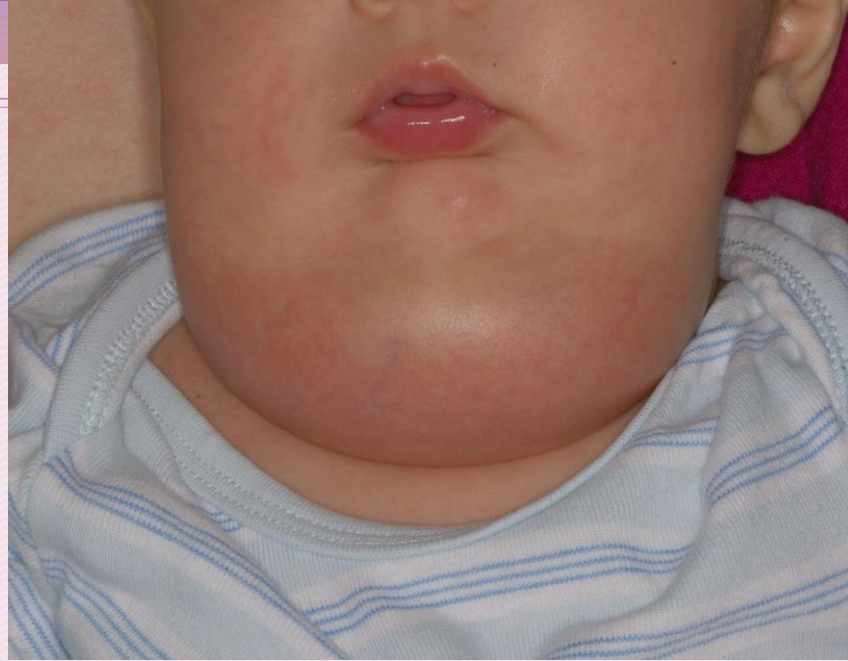
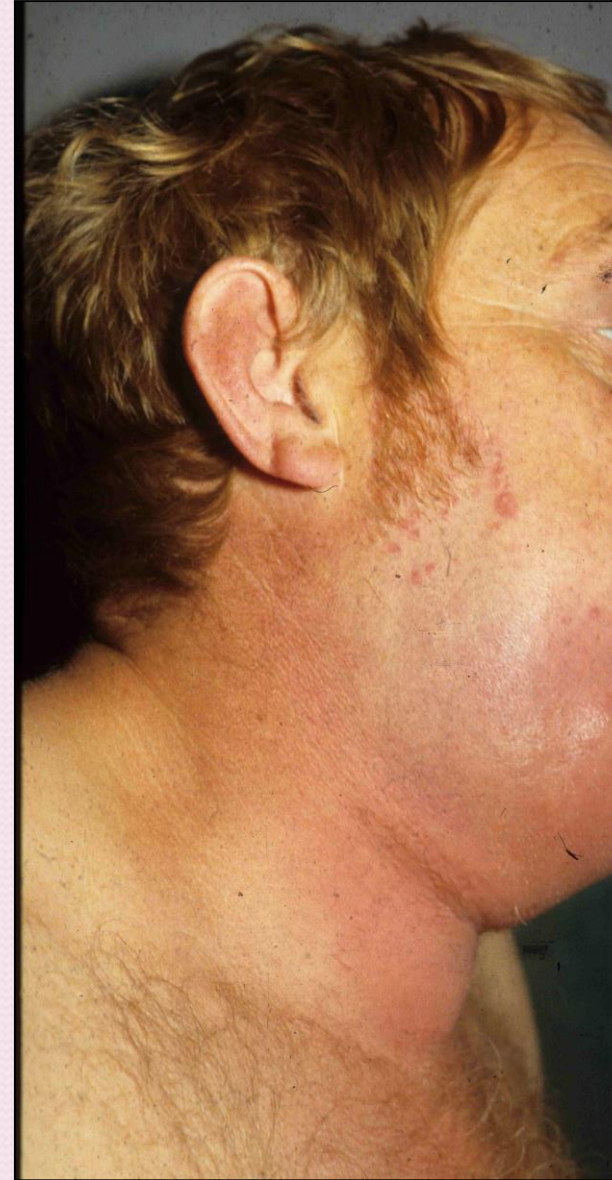
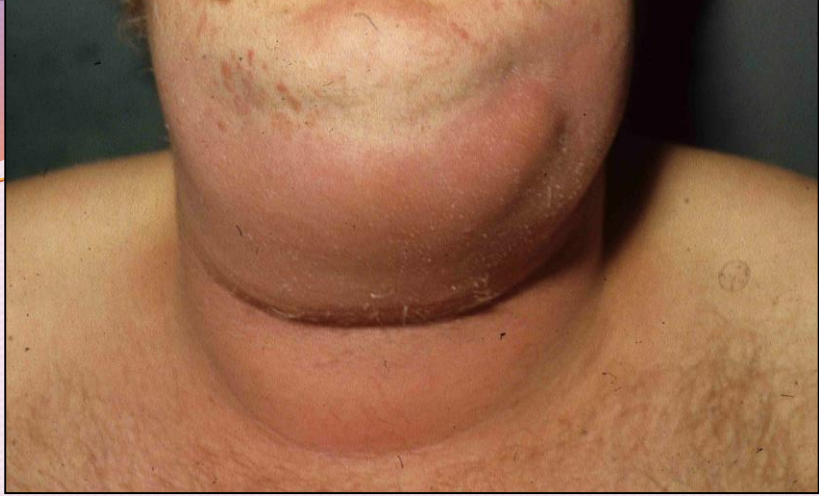Local inflammation

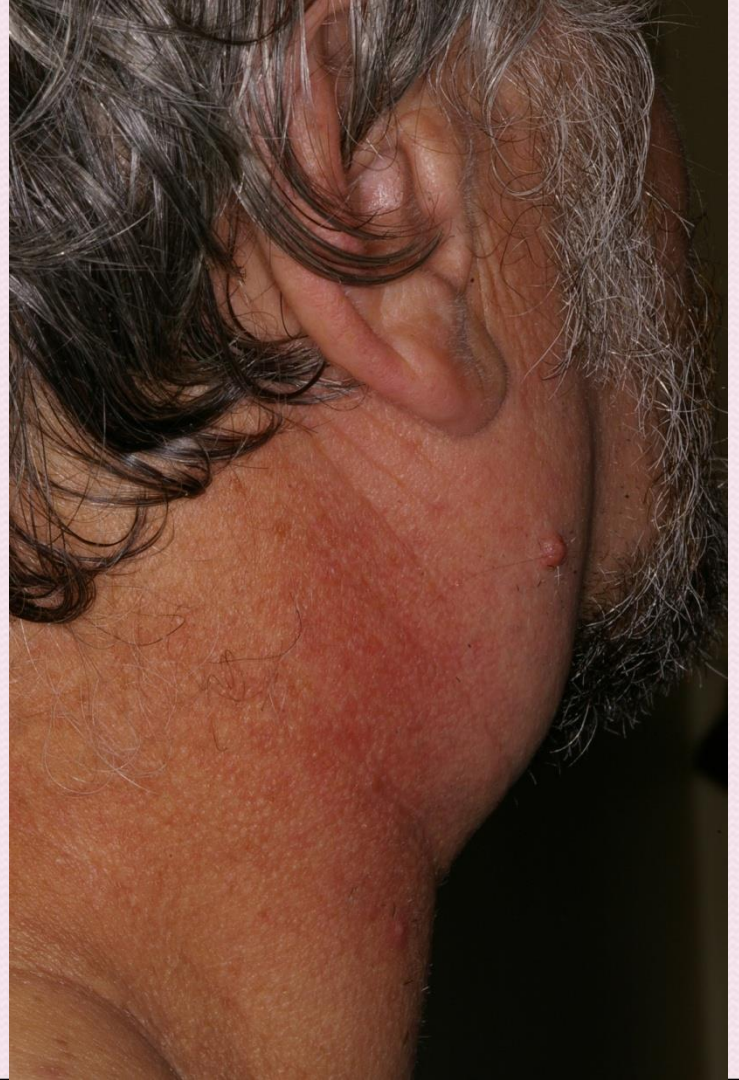
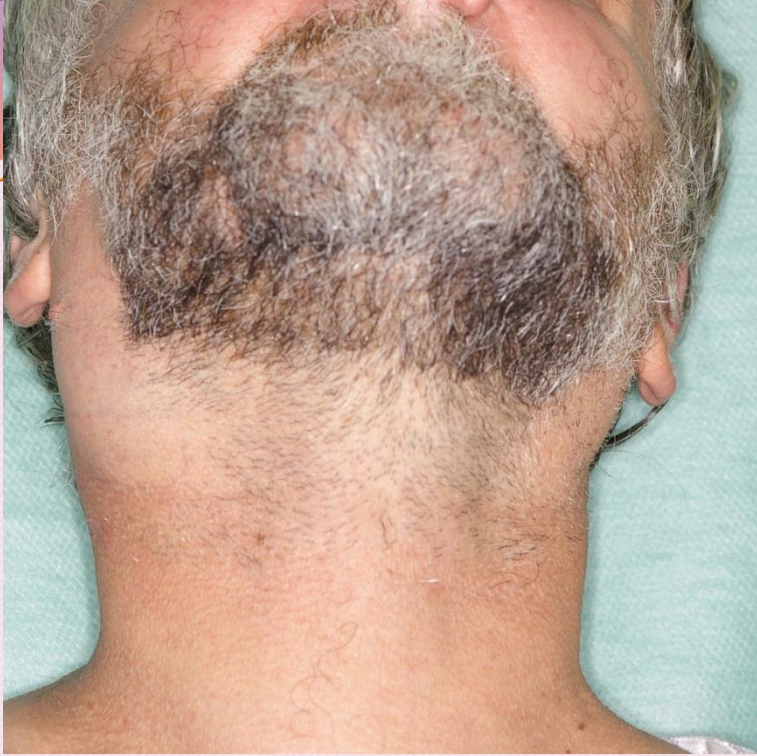
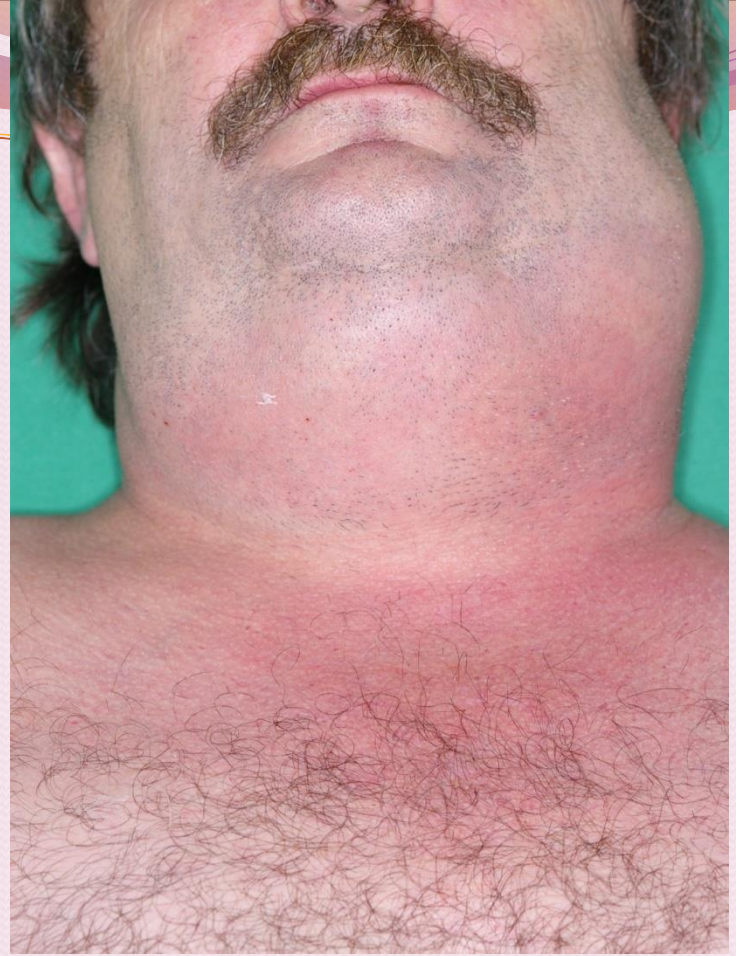


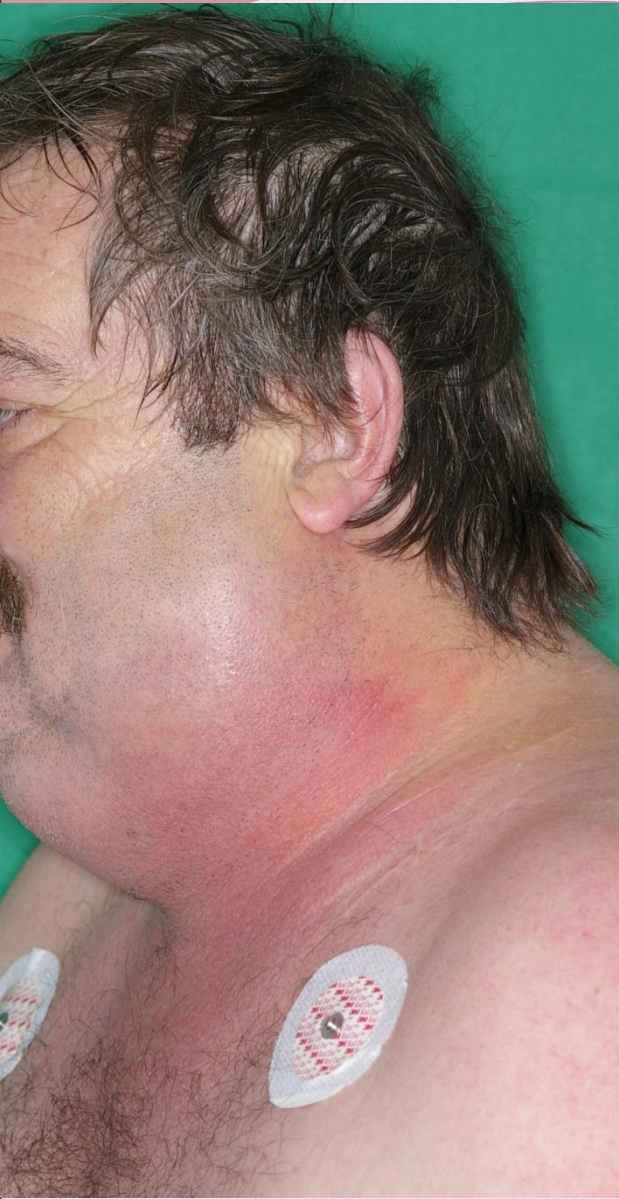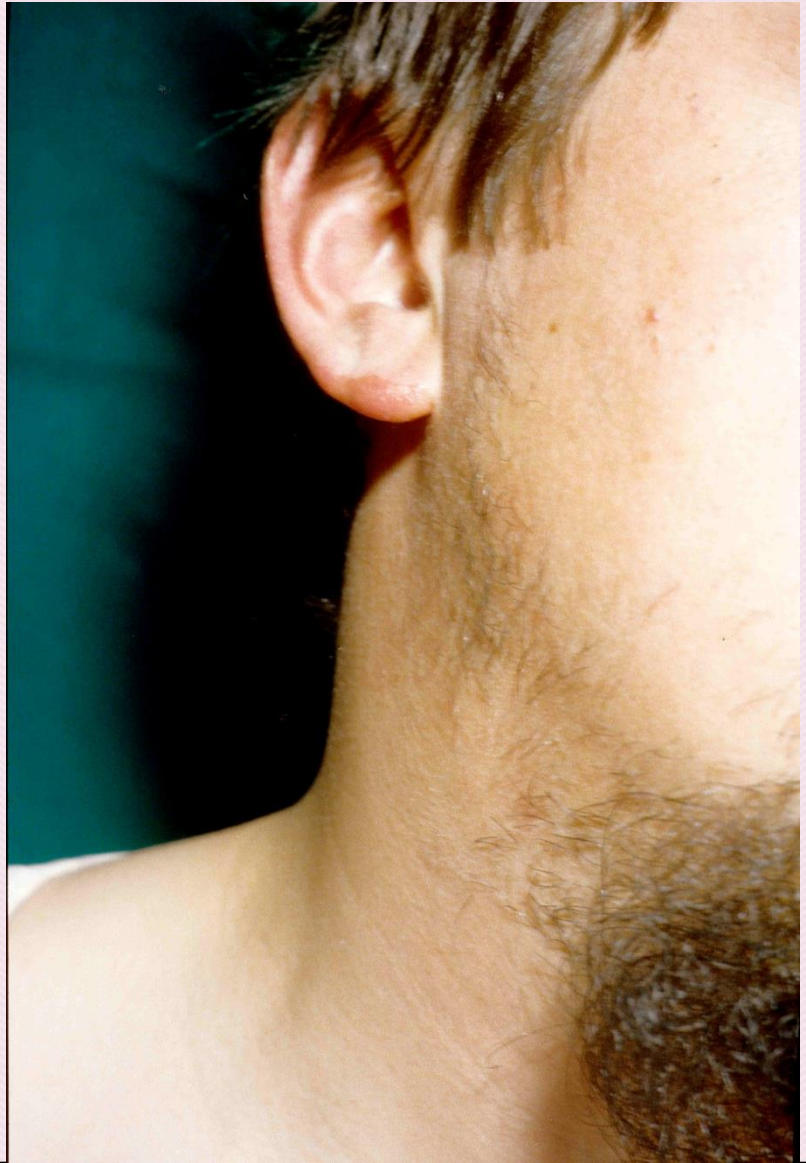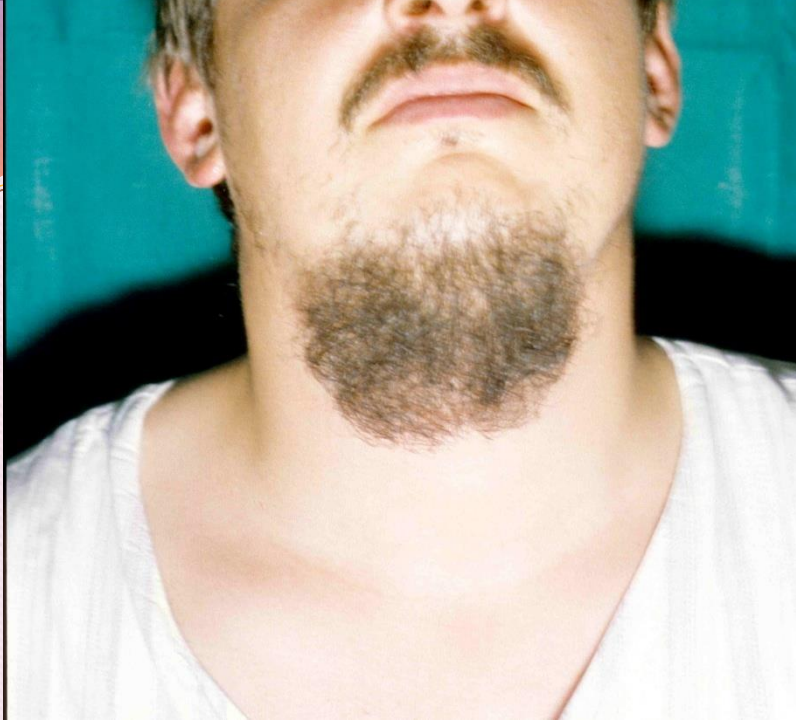






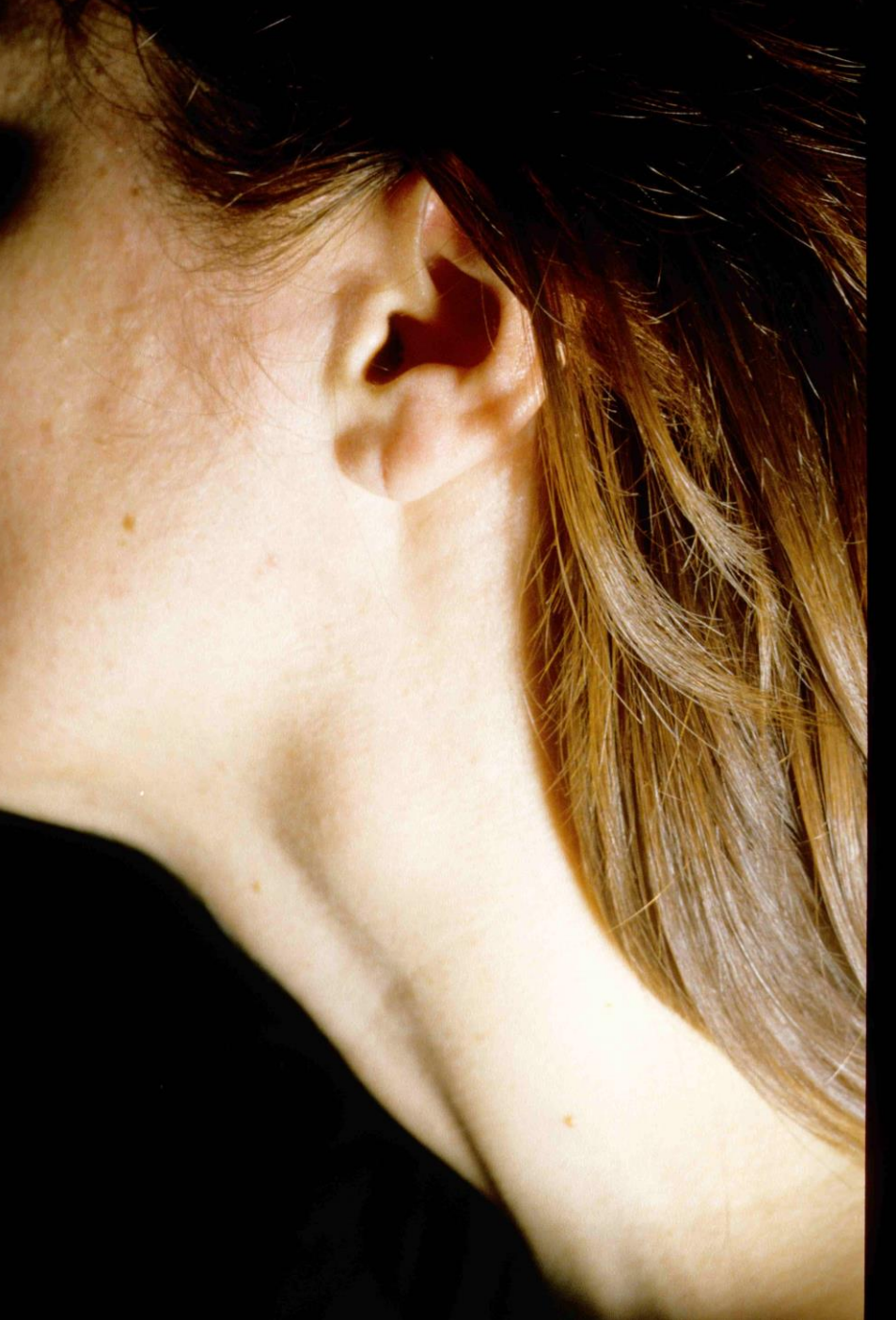


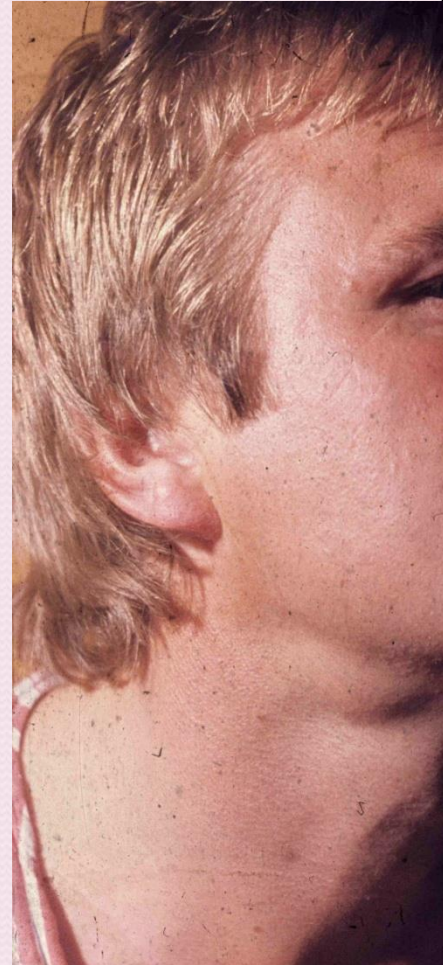
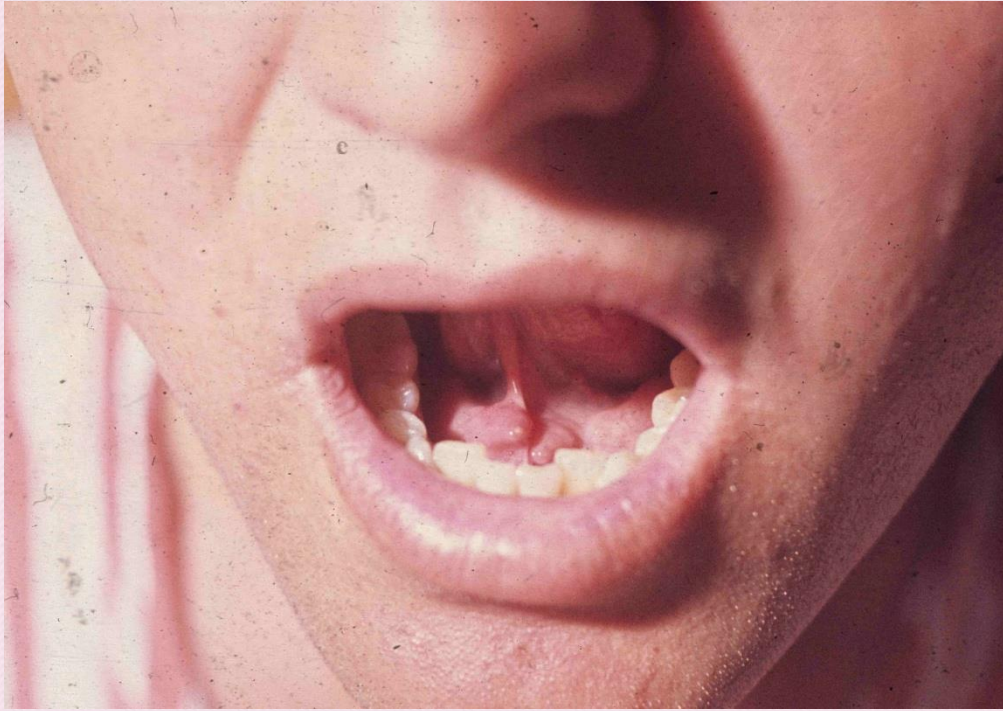

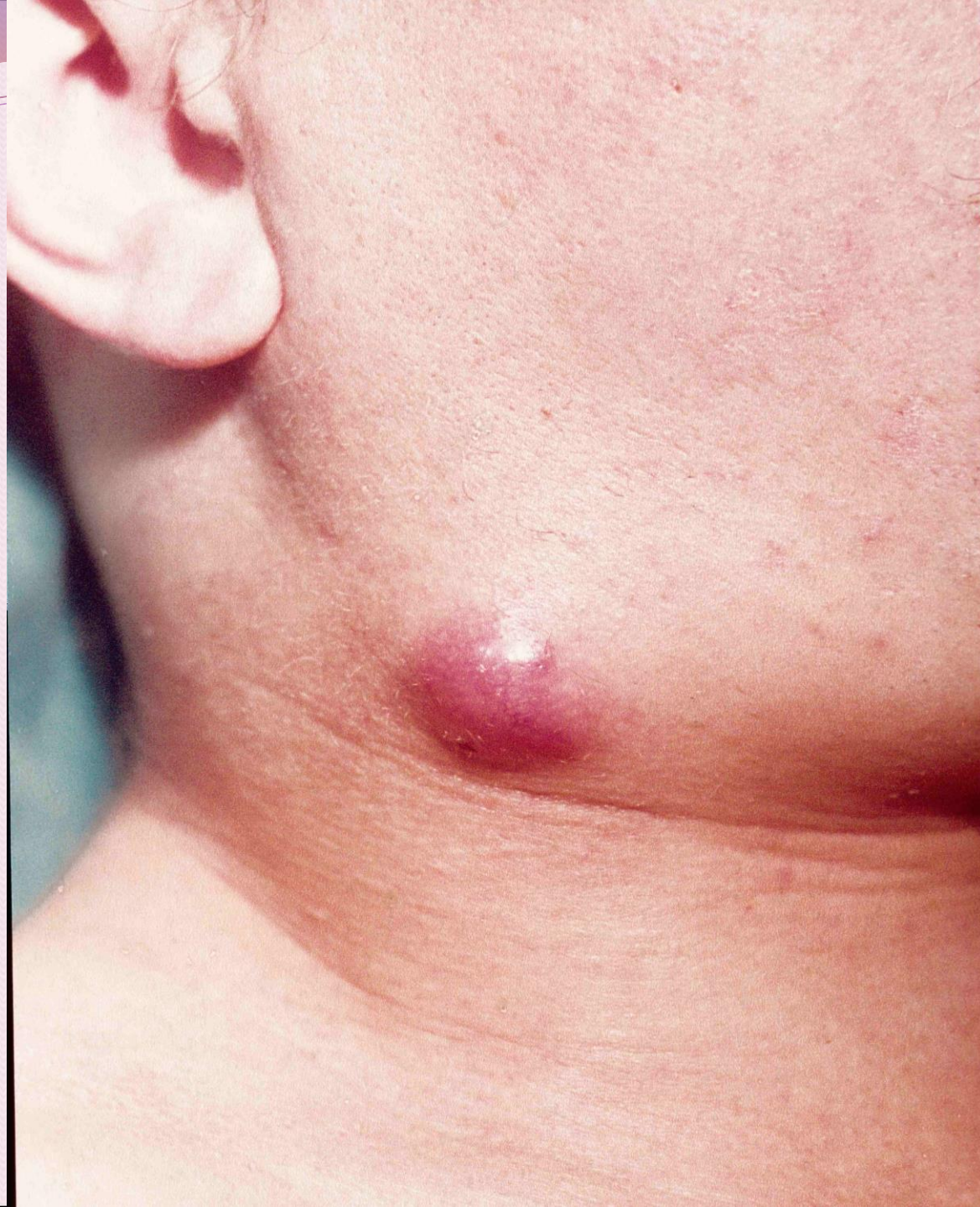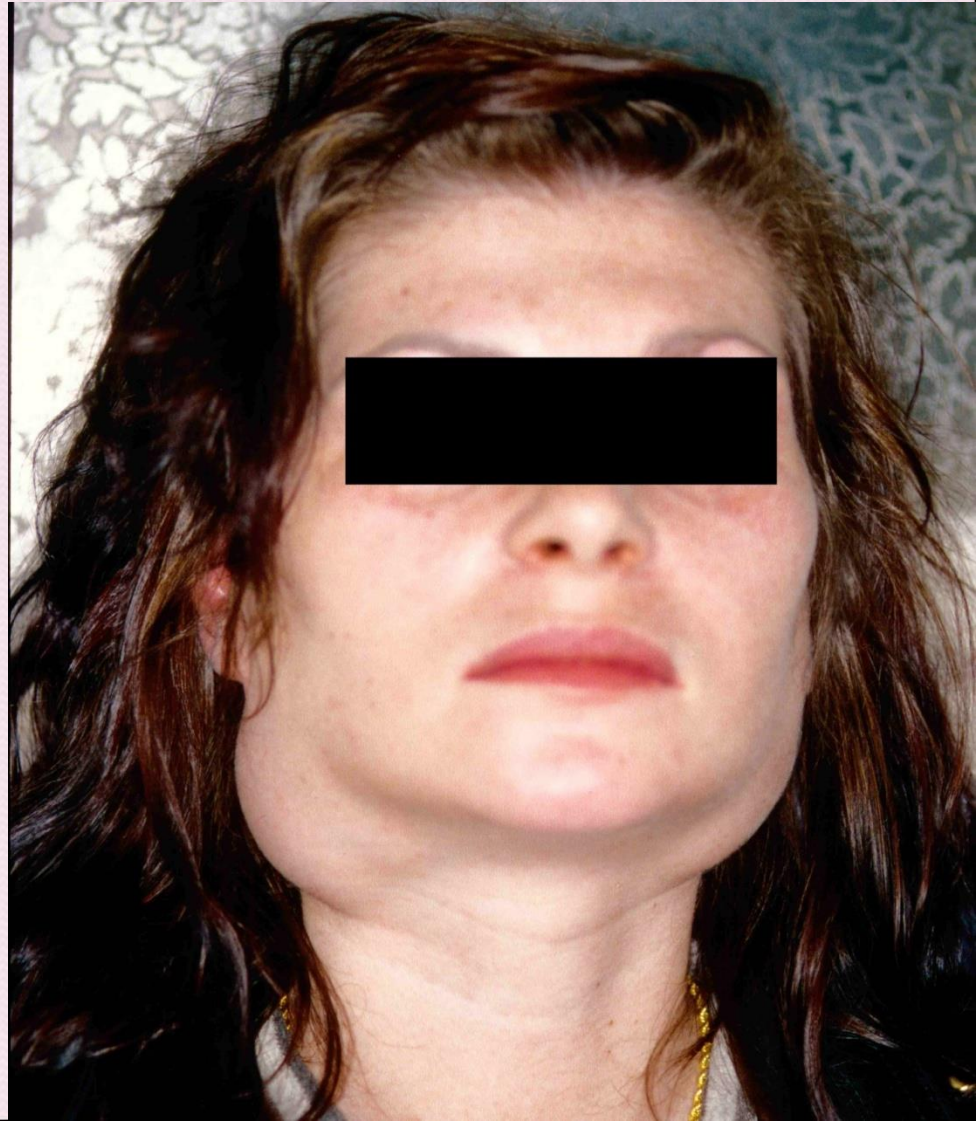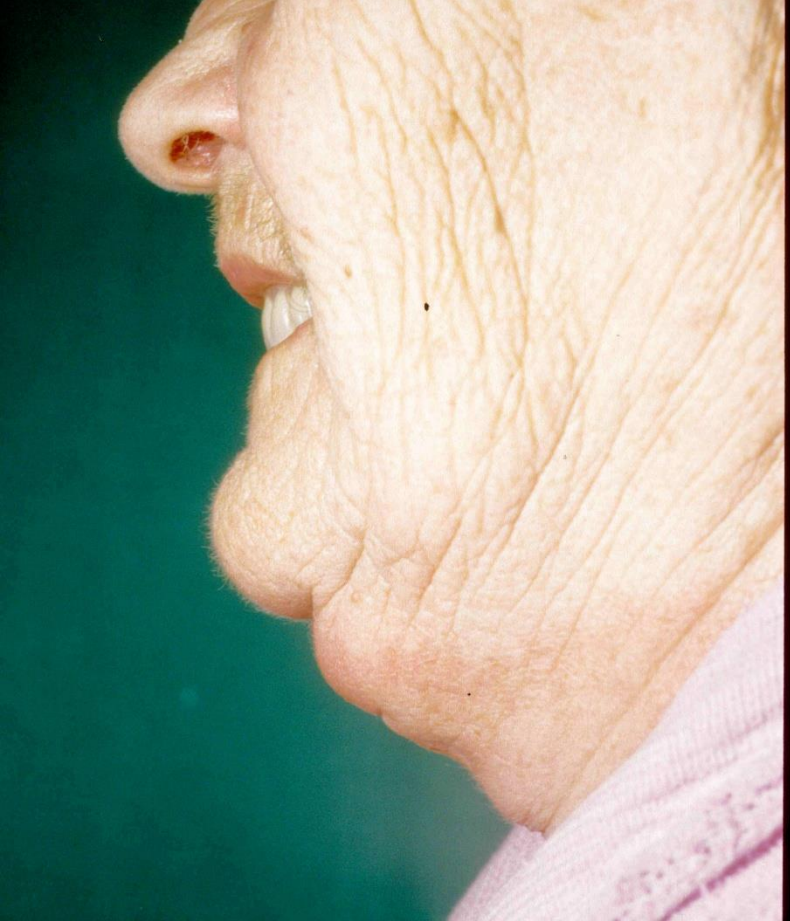








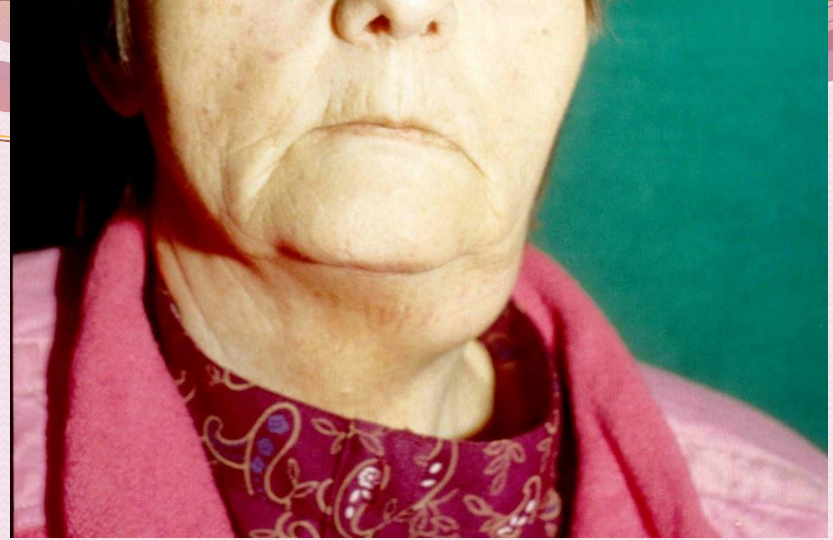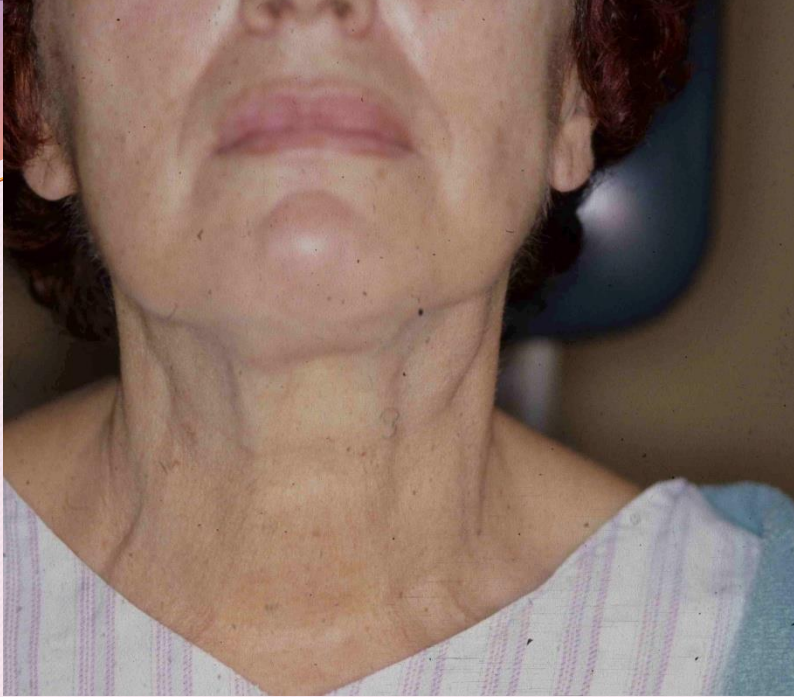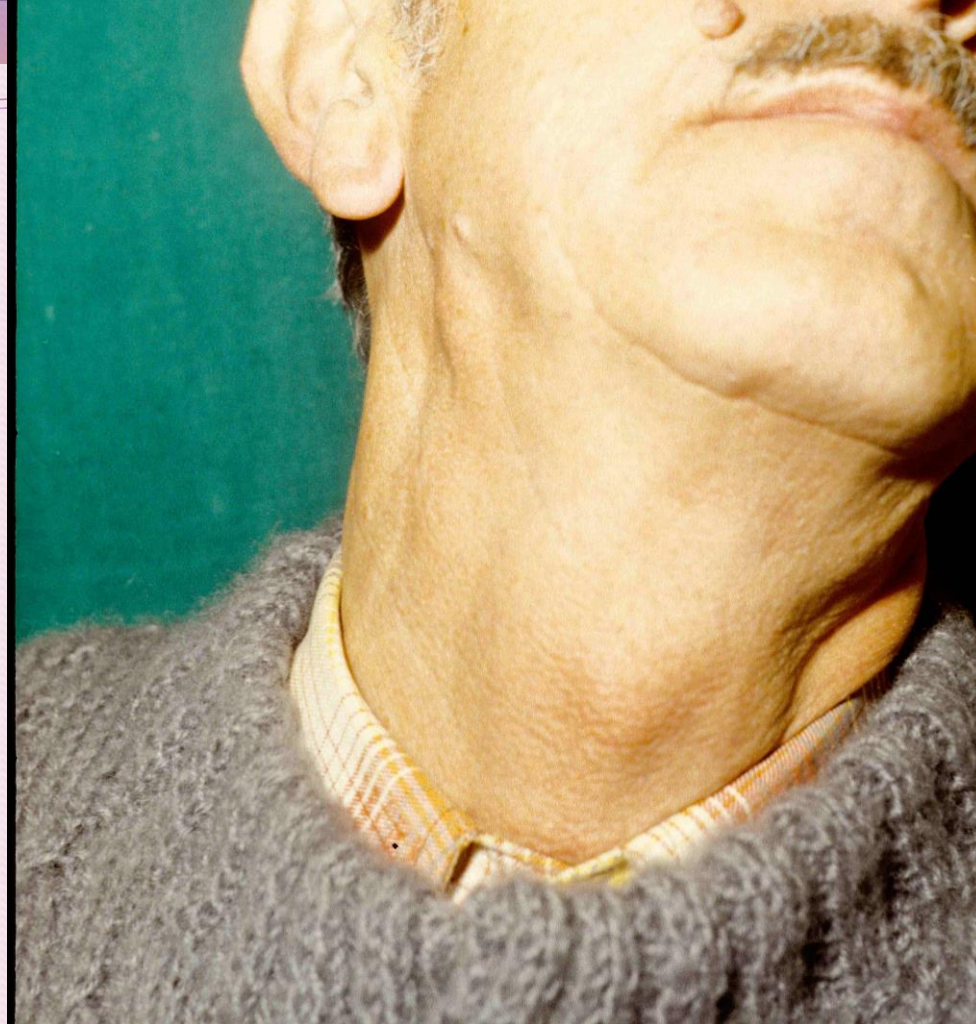
Systemic infections

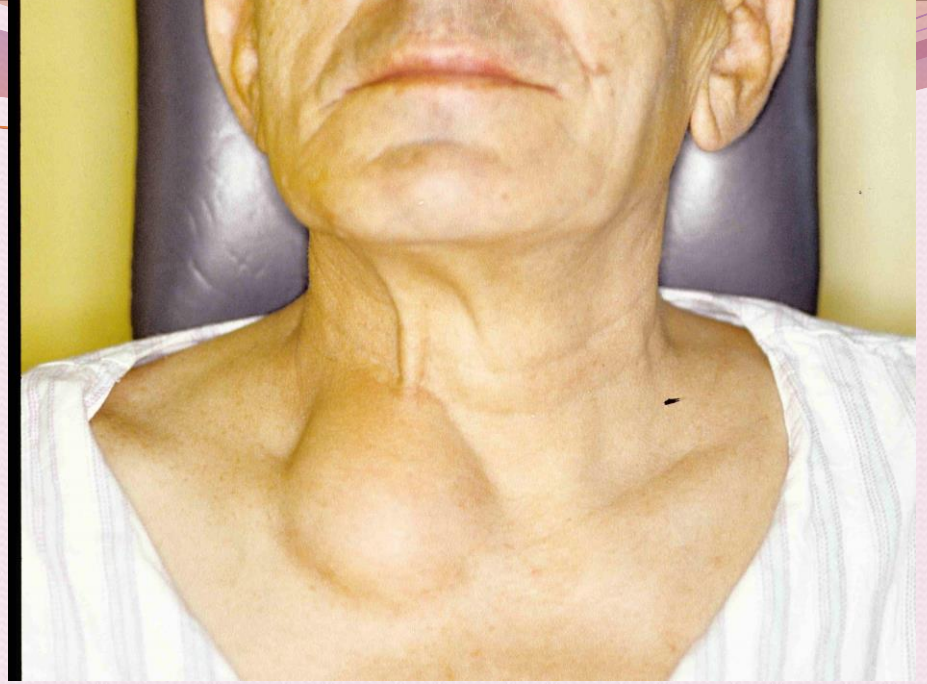
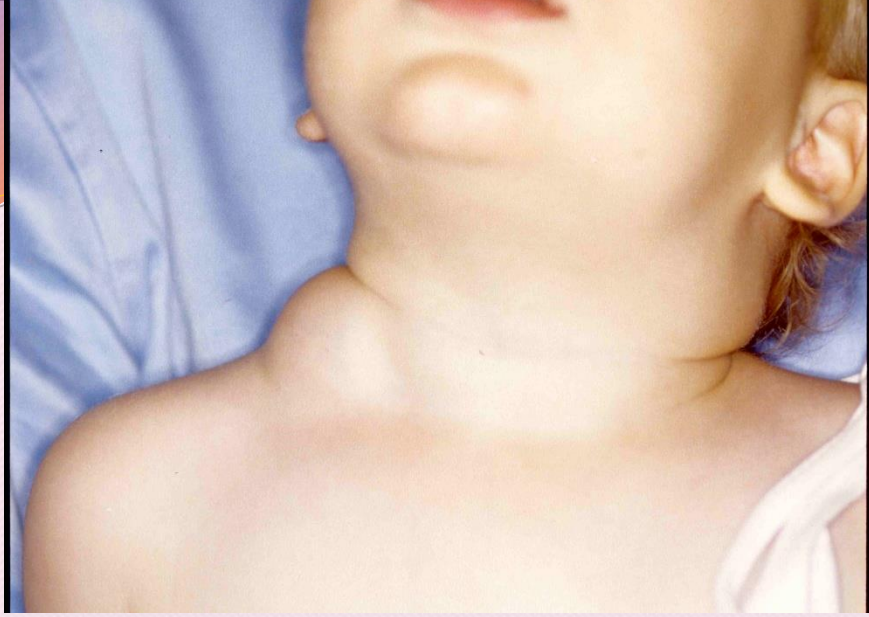


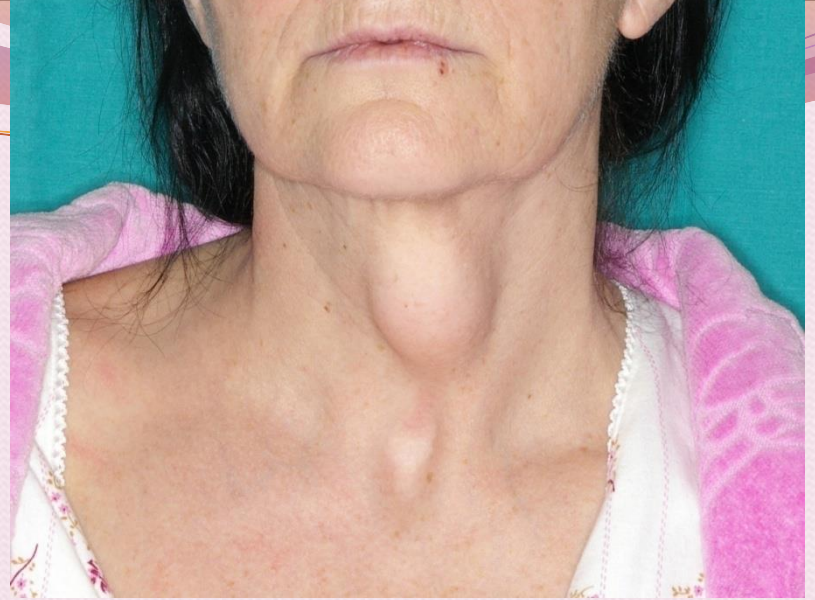
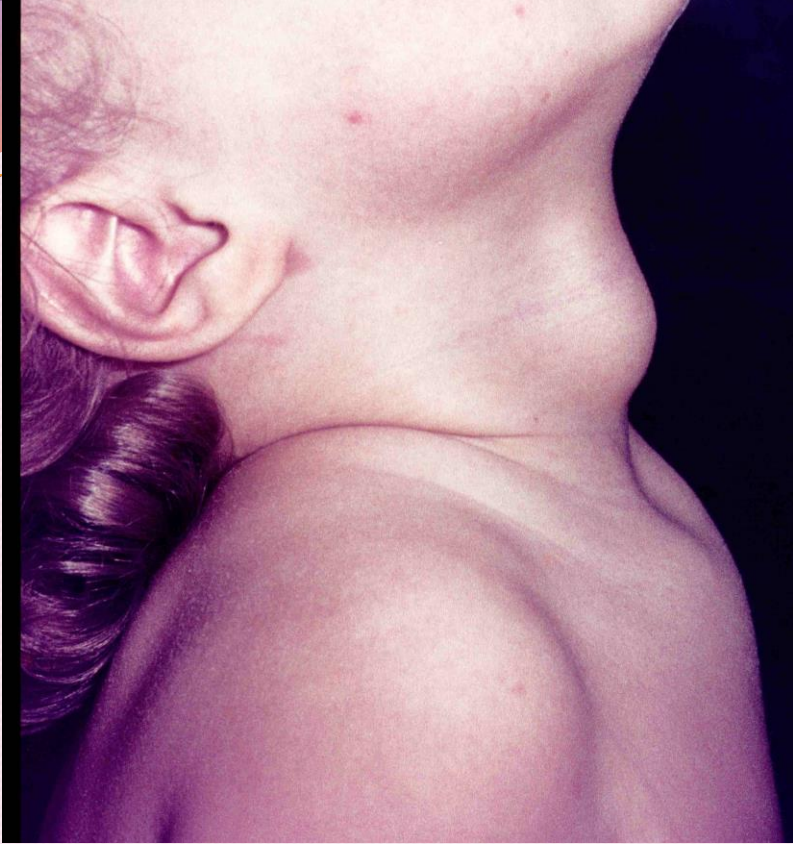

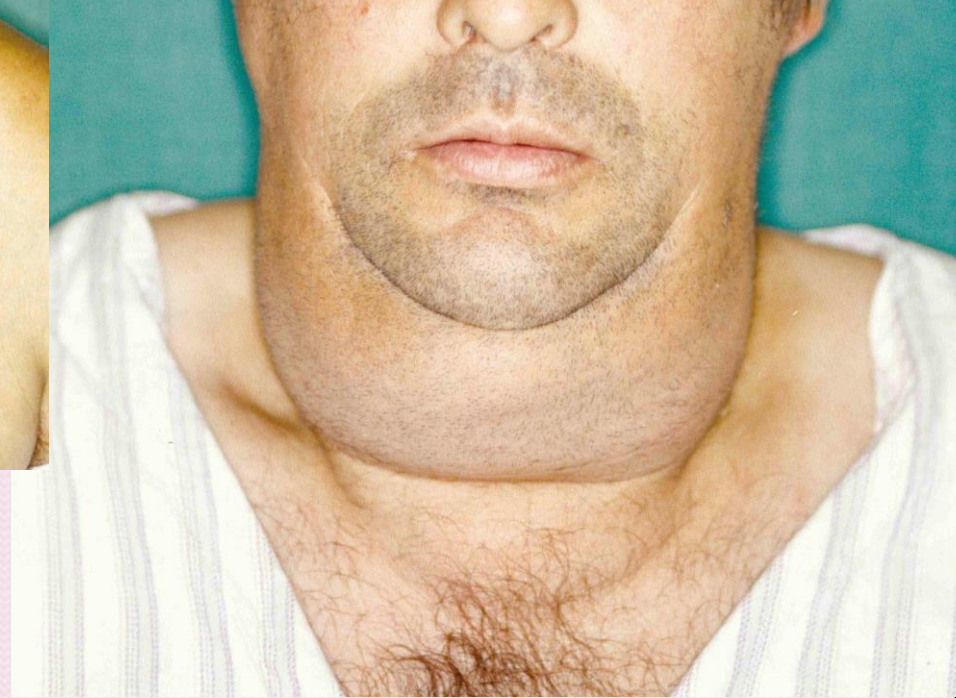

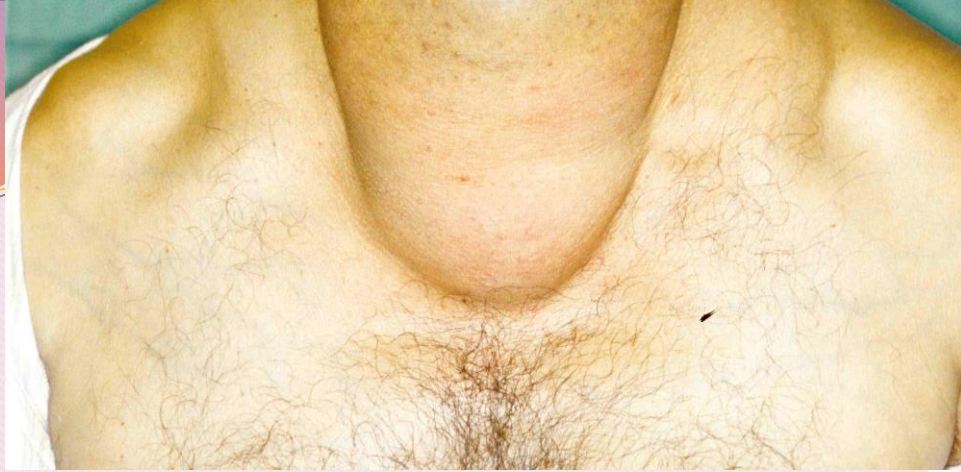
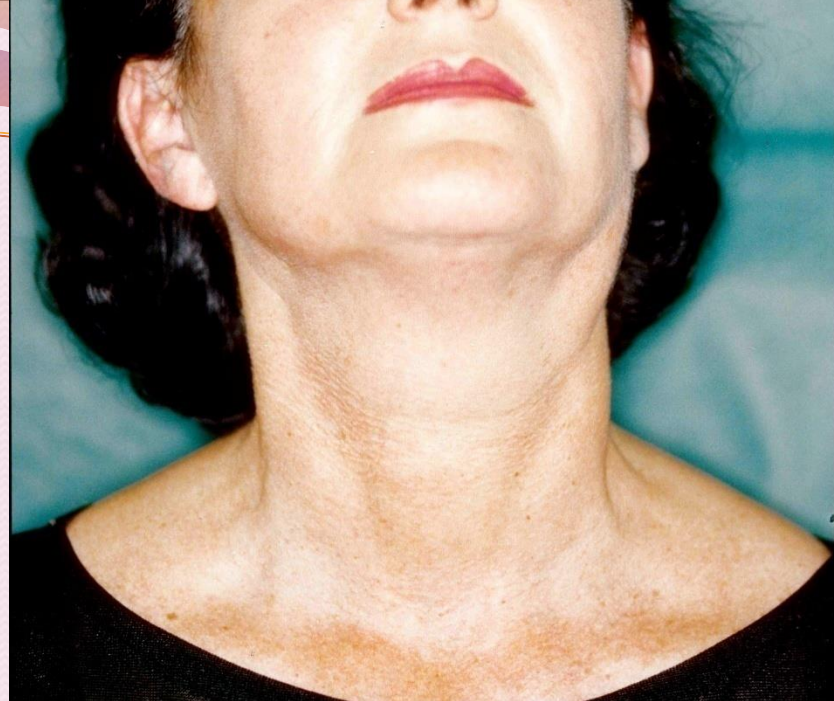
Benign tumors



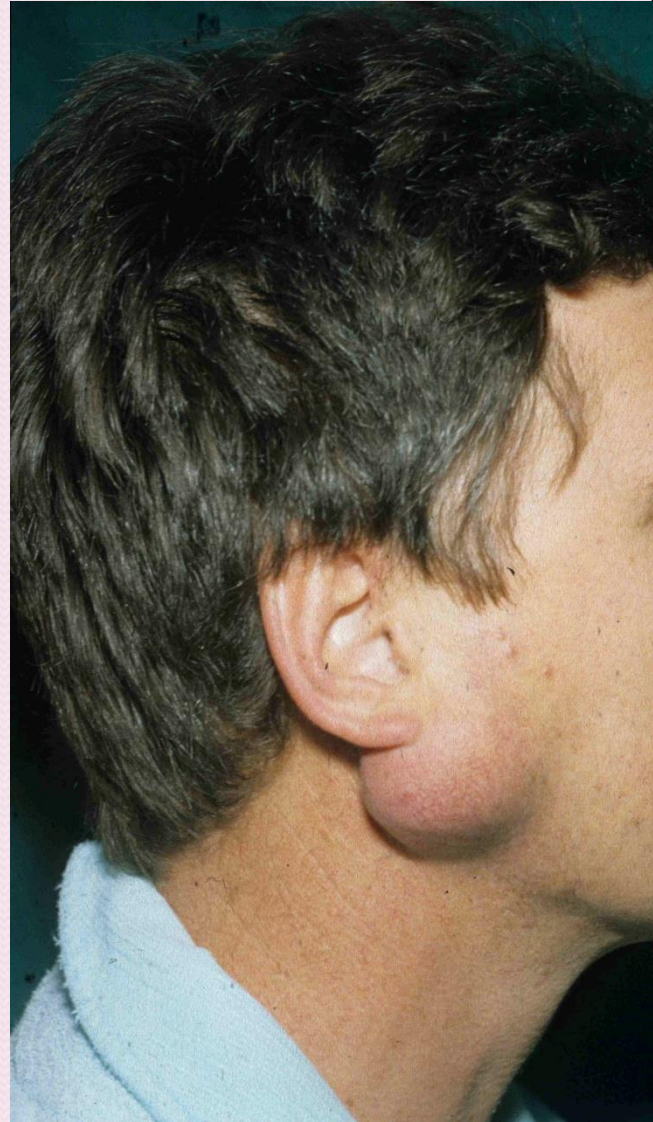


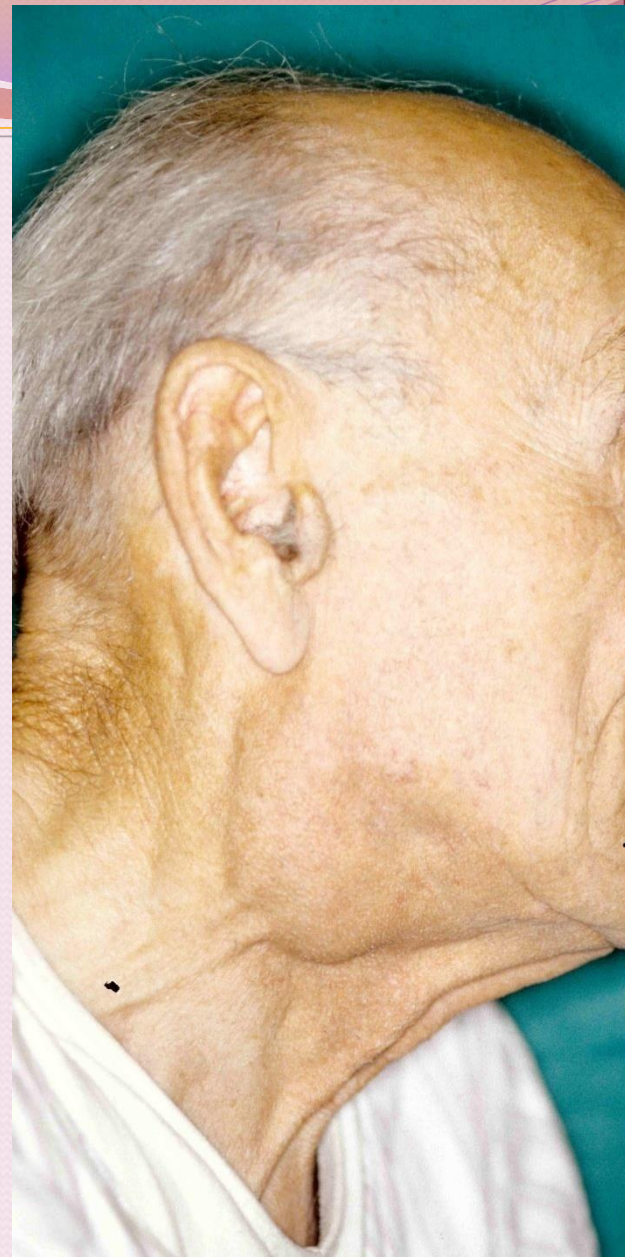
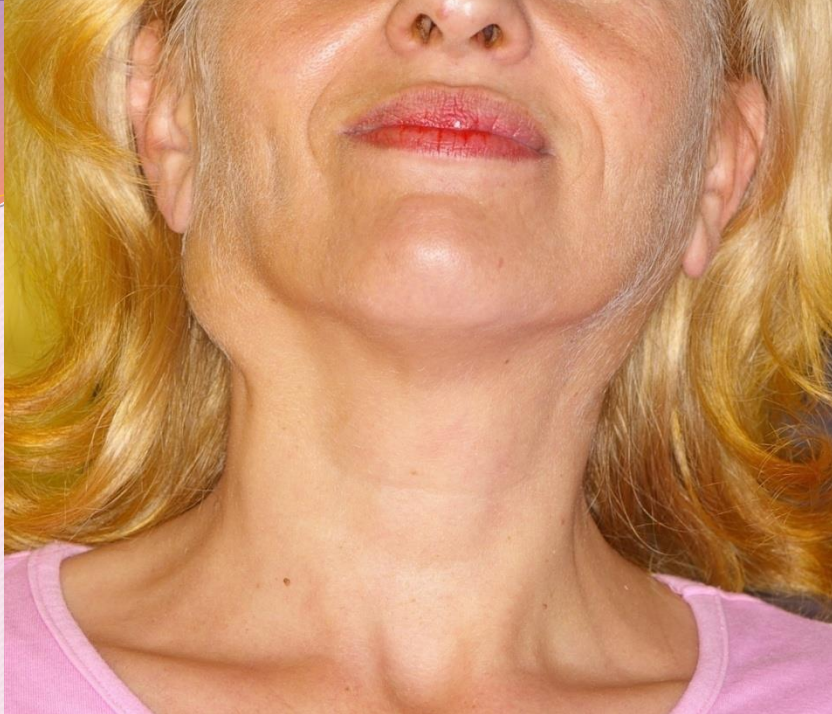






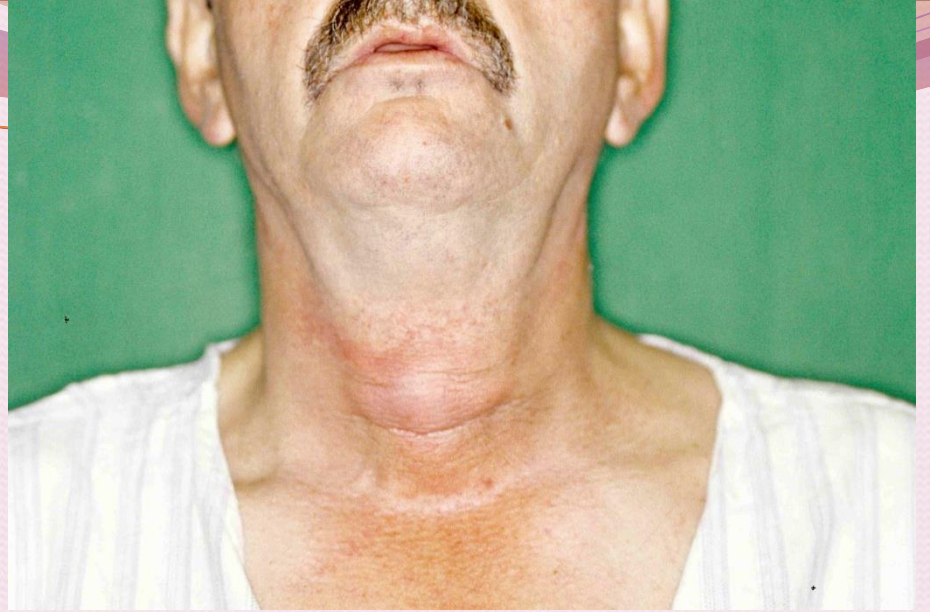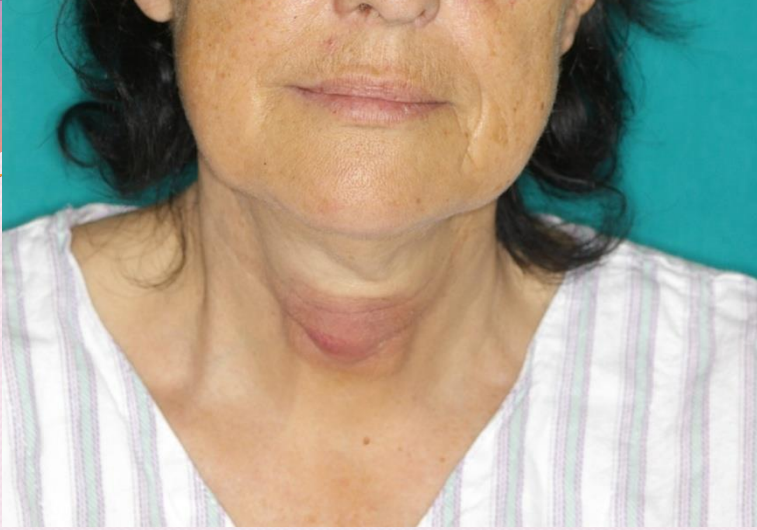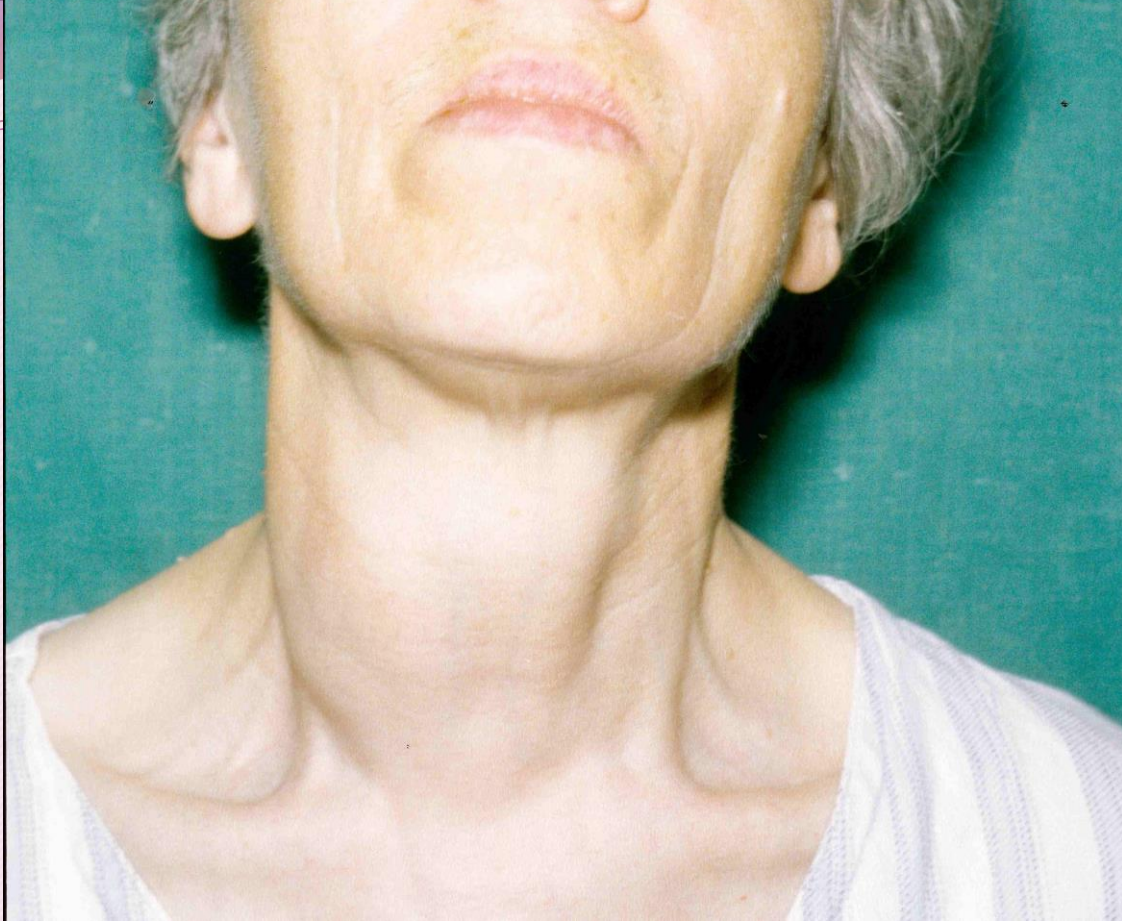


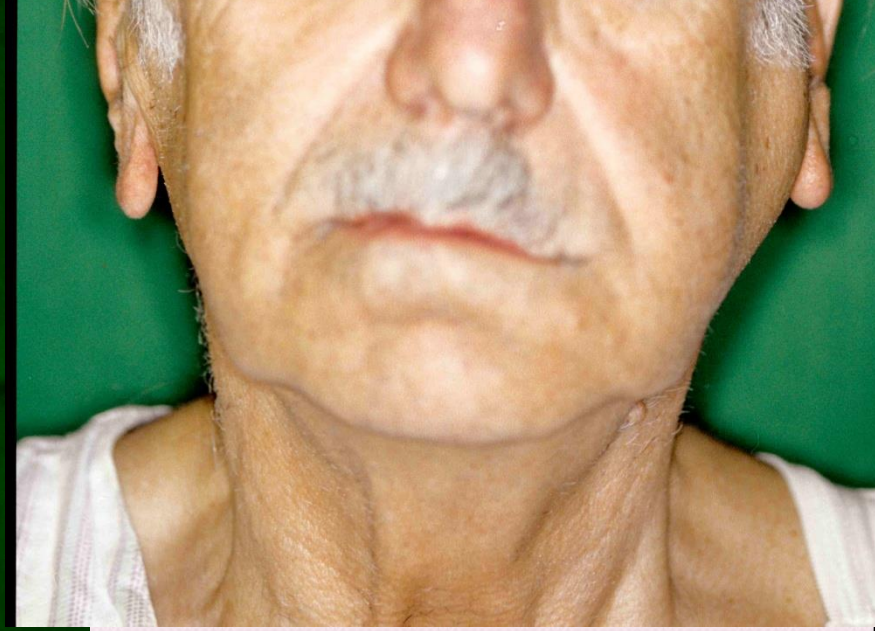




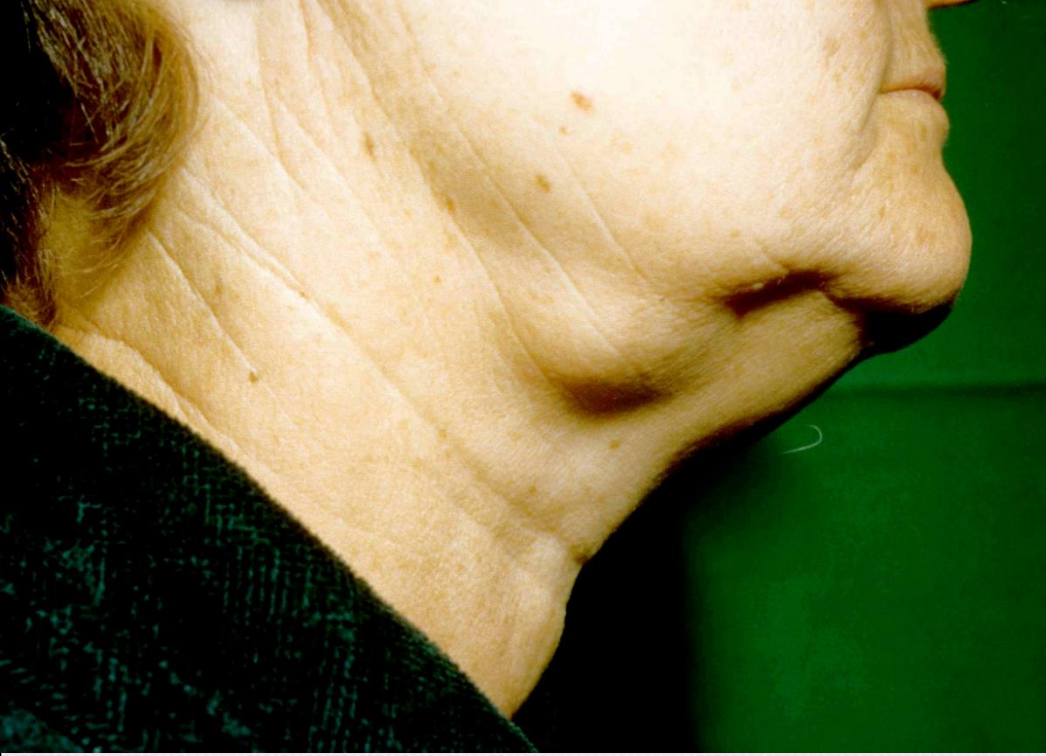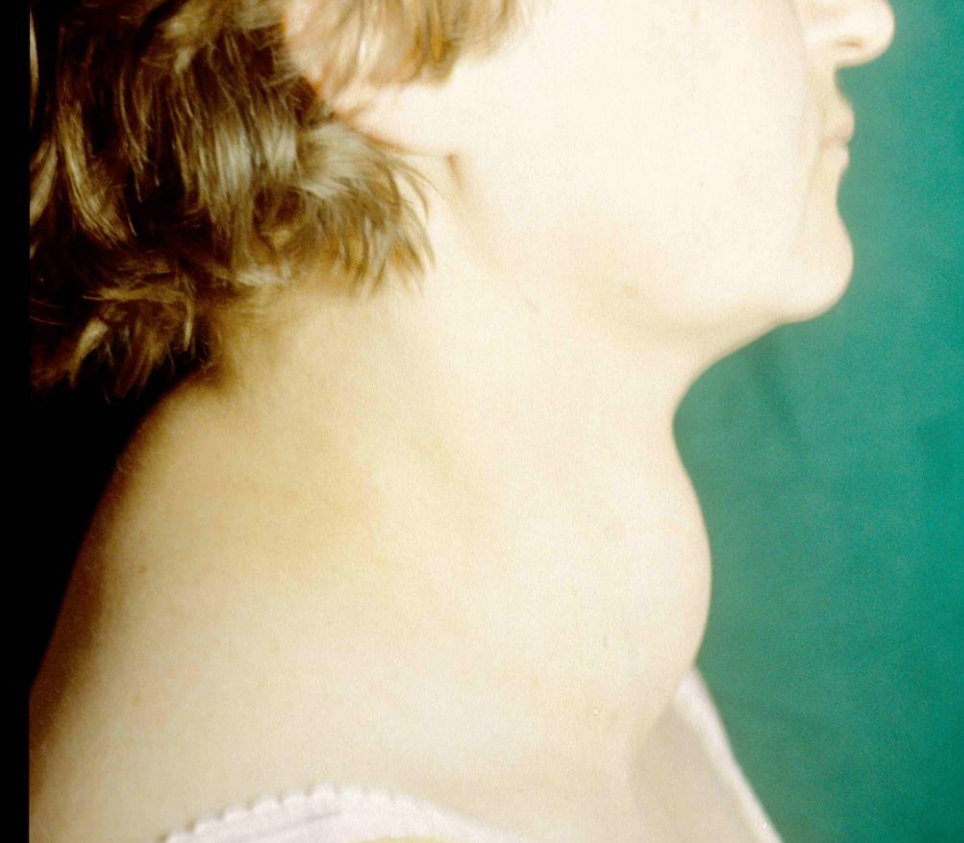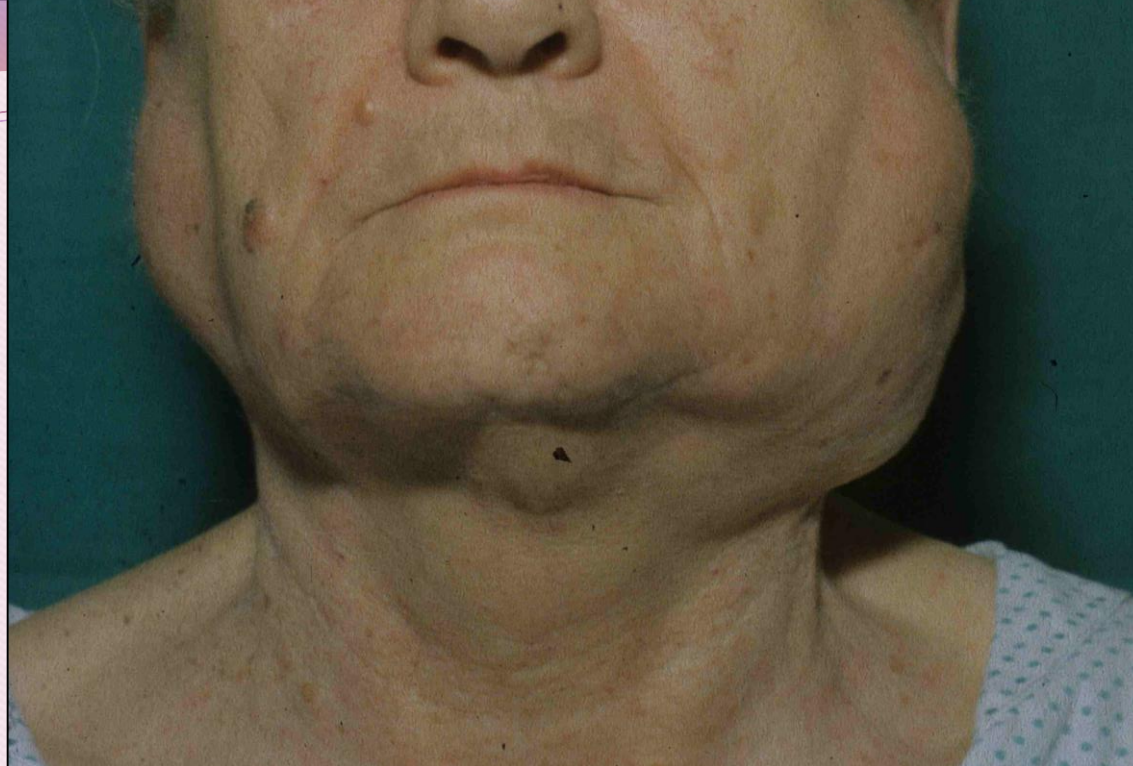
Malignant tumors

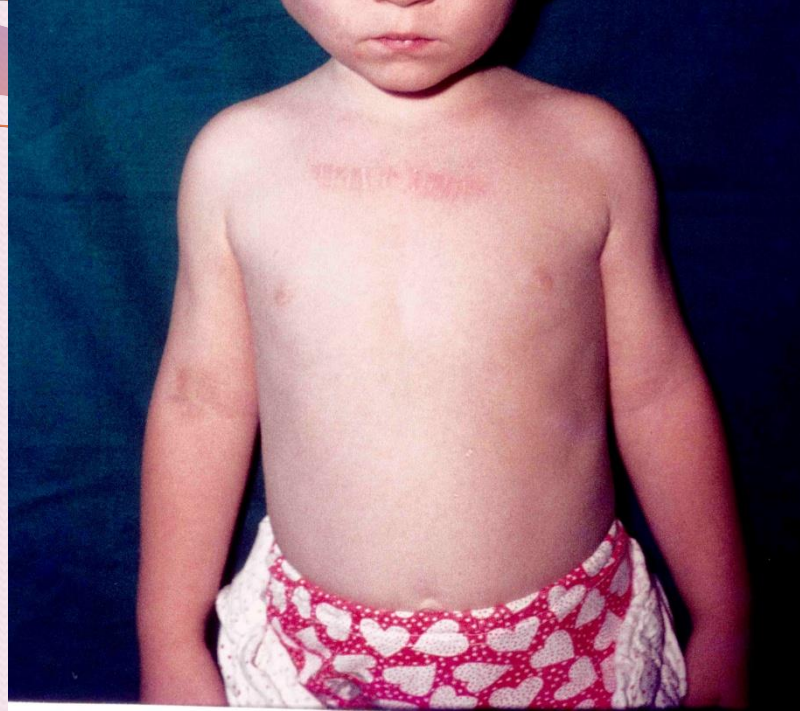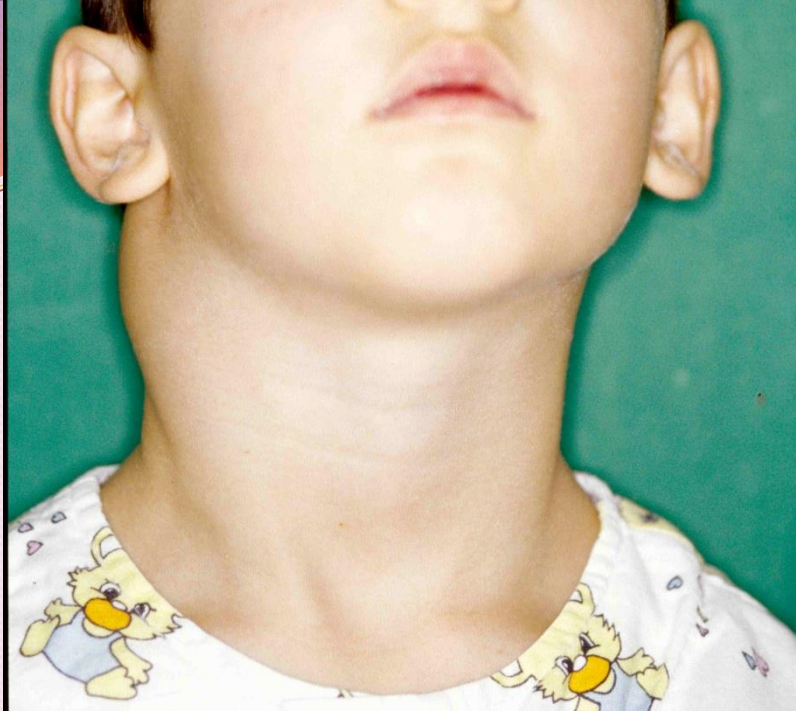


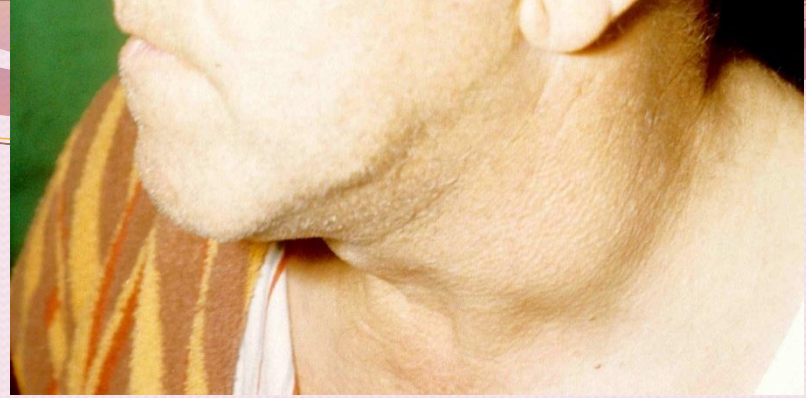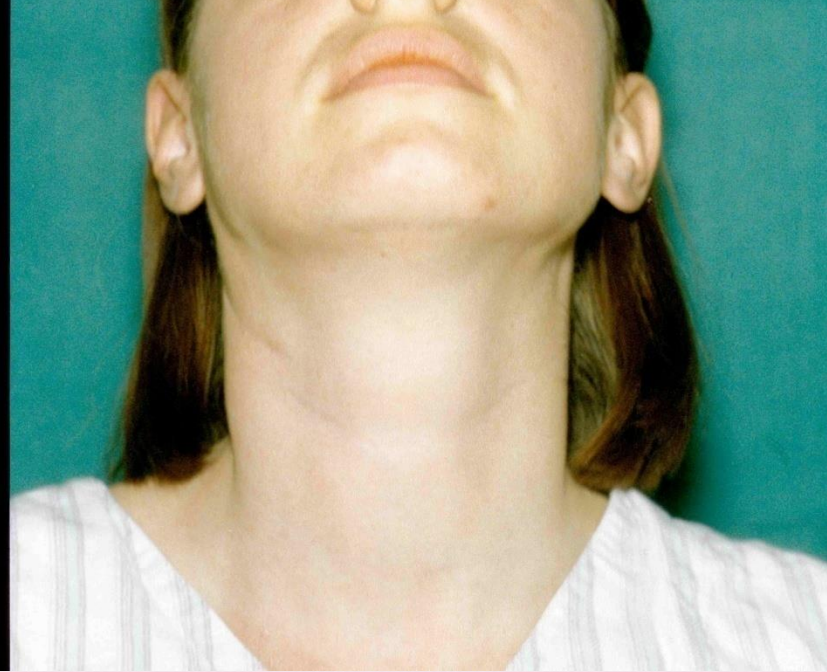






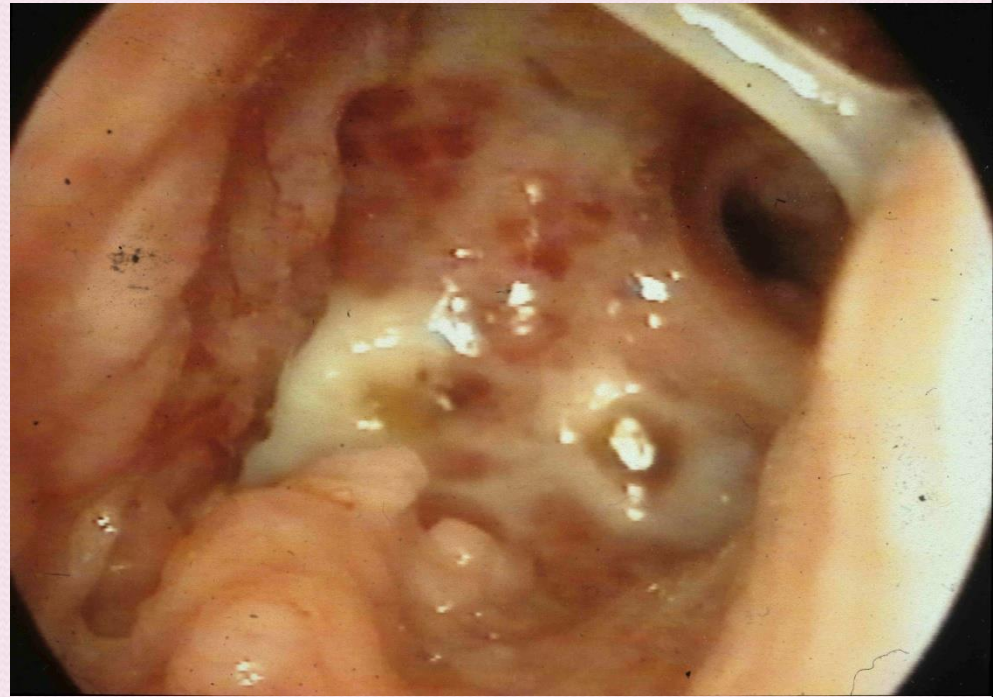


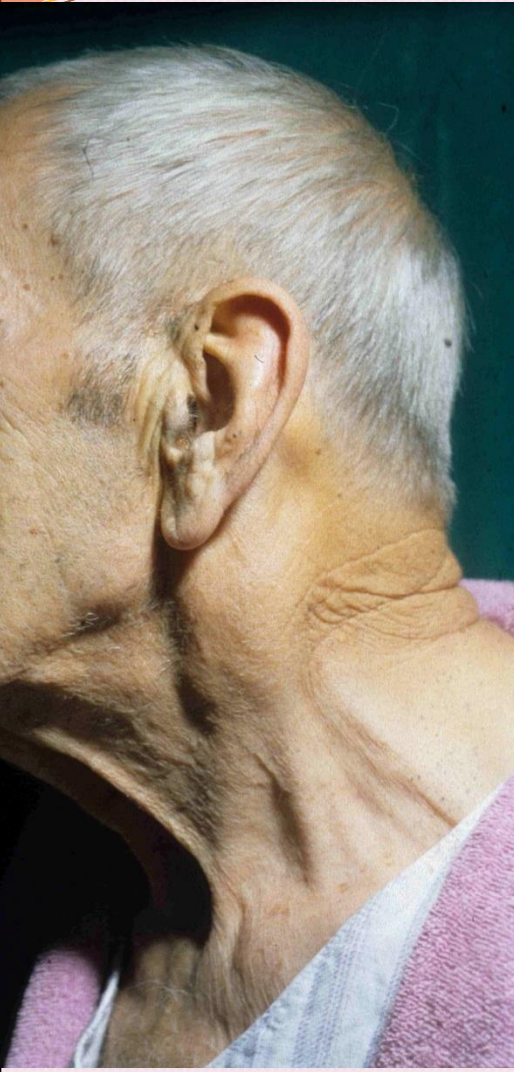

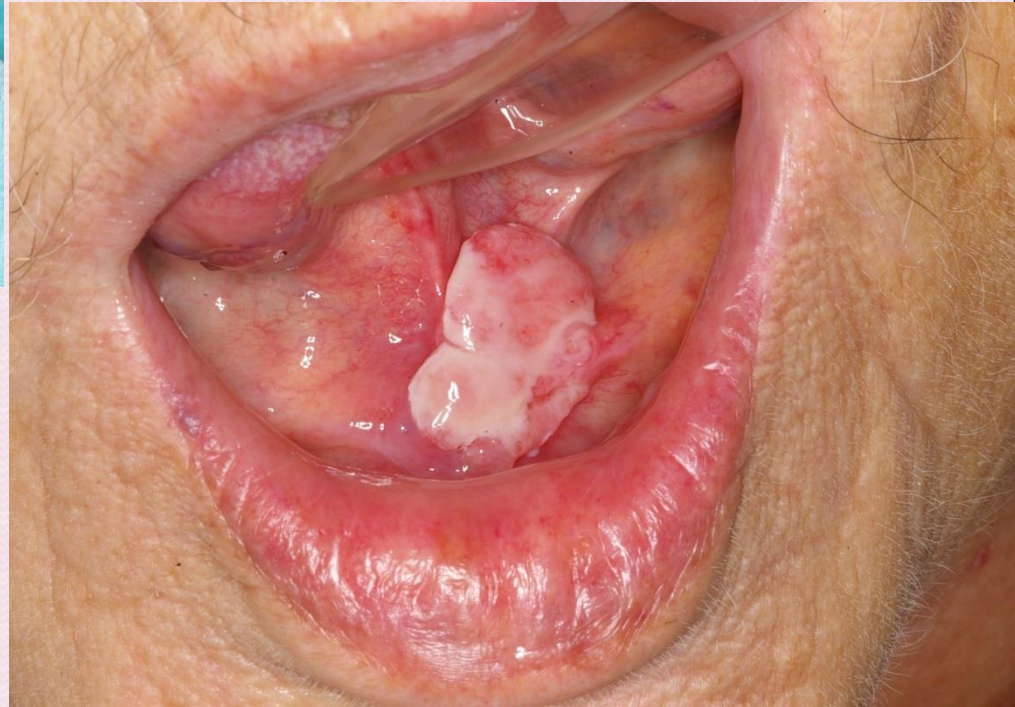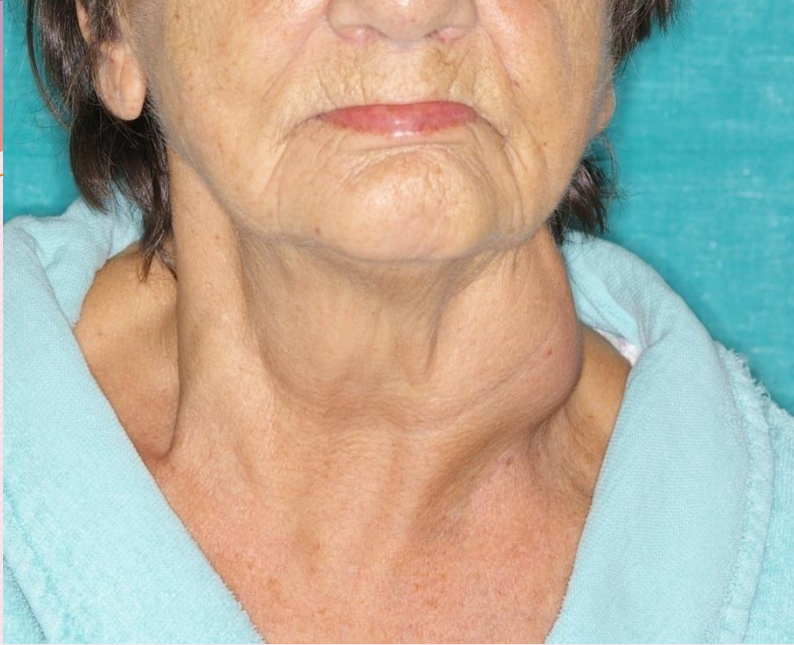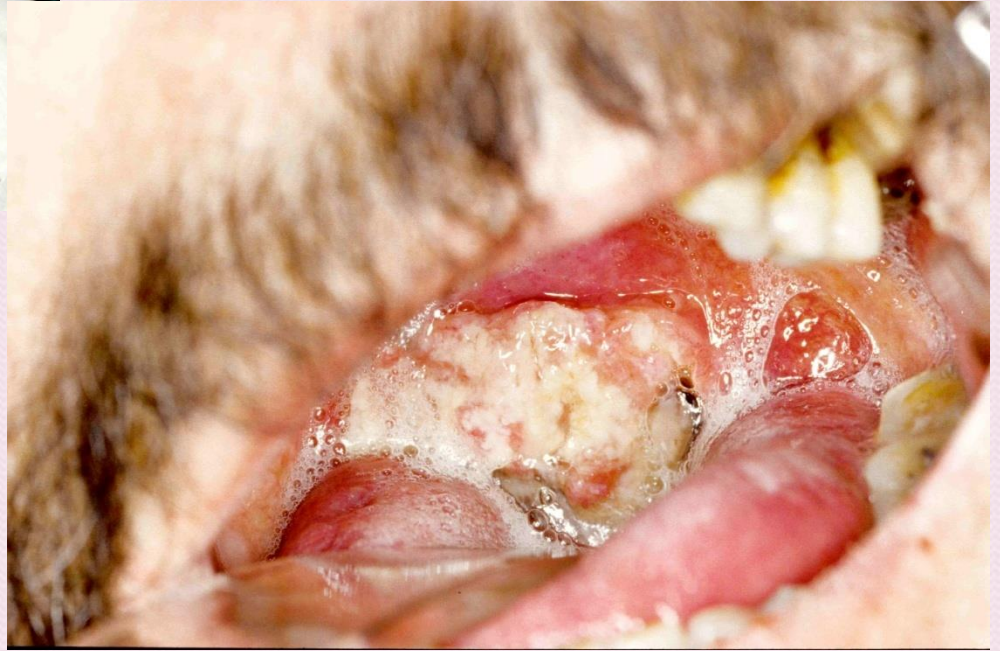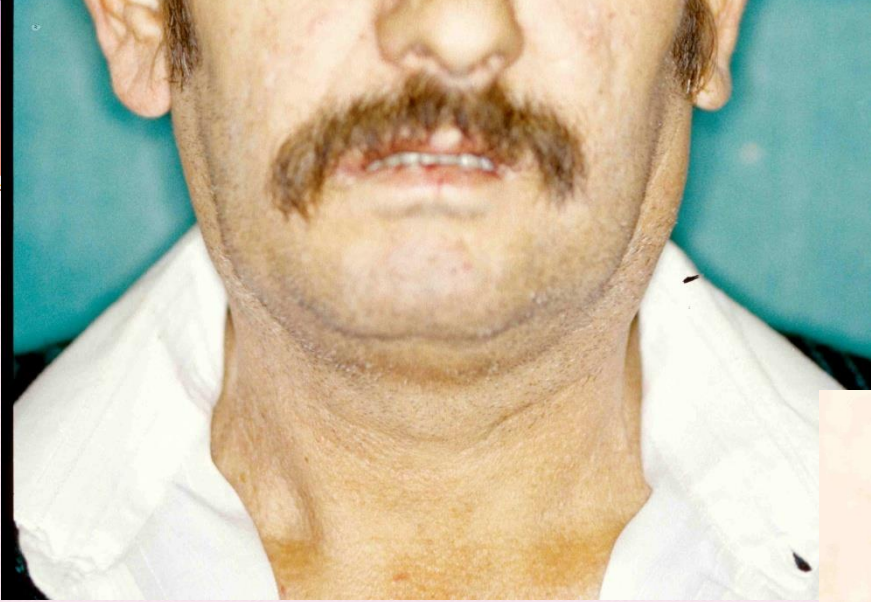




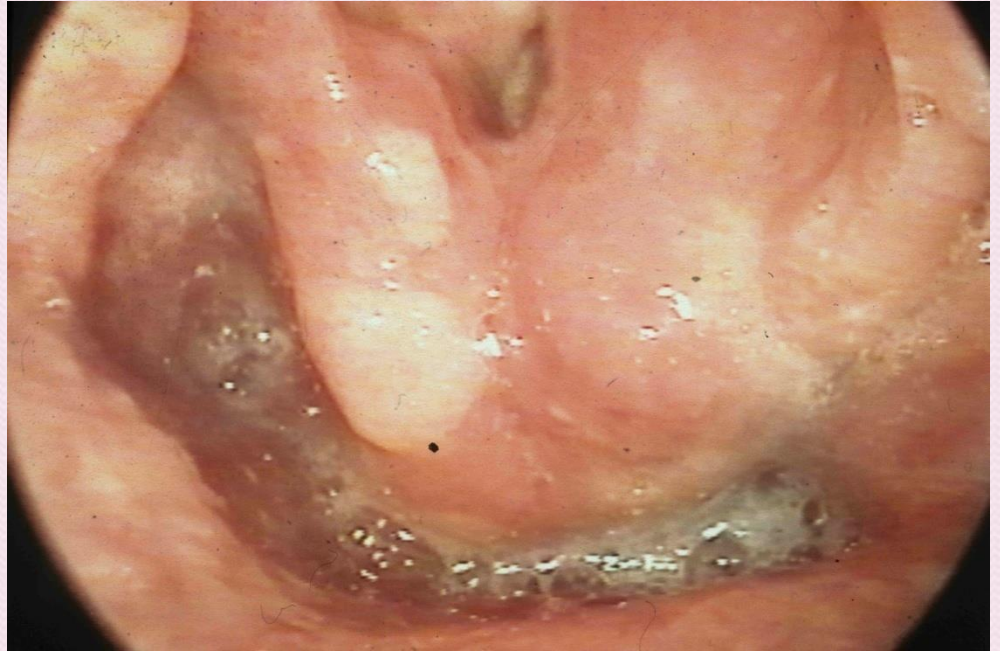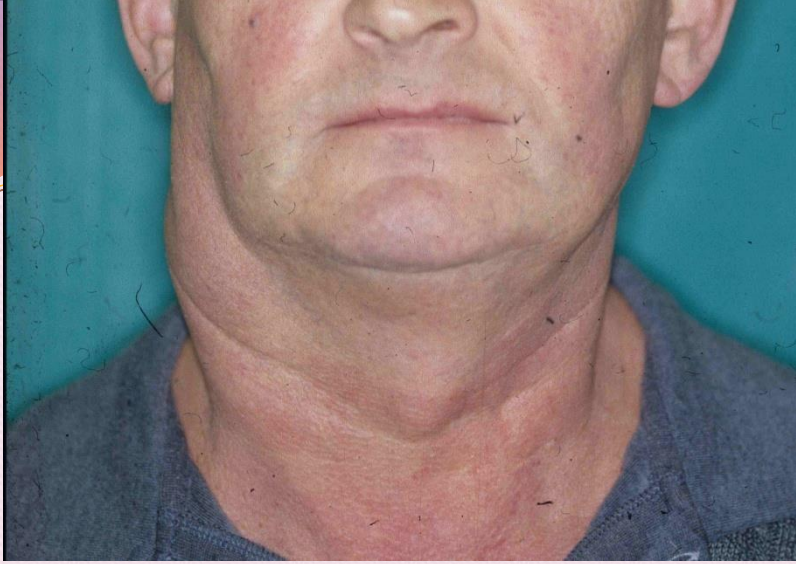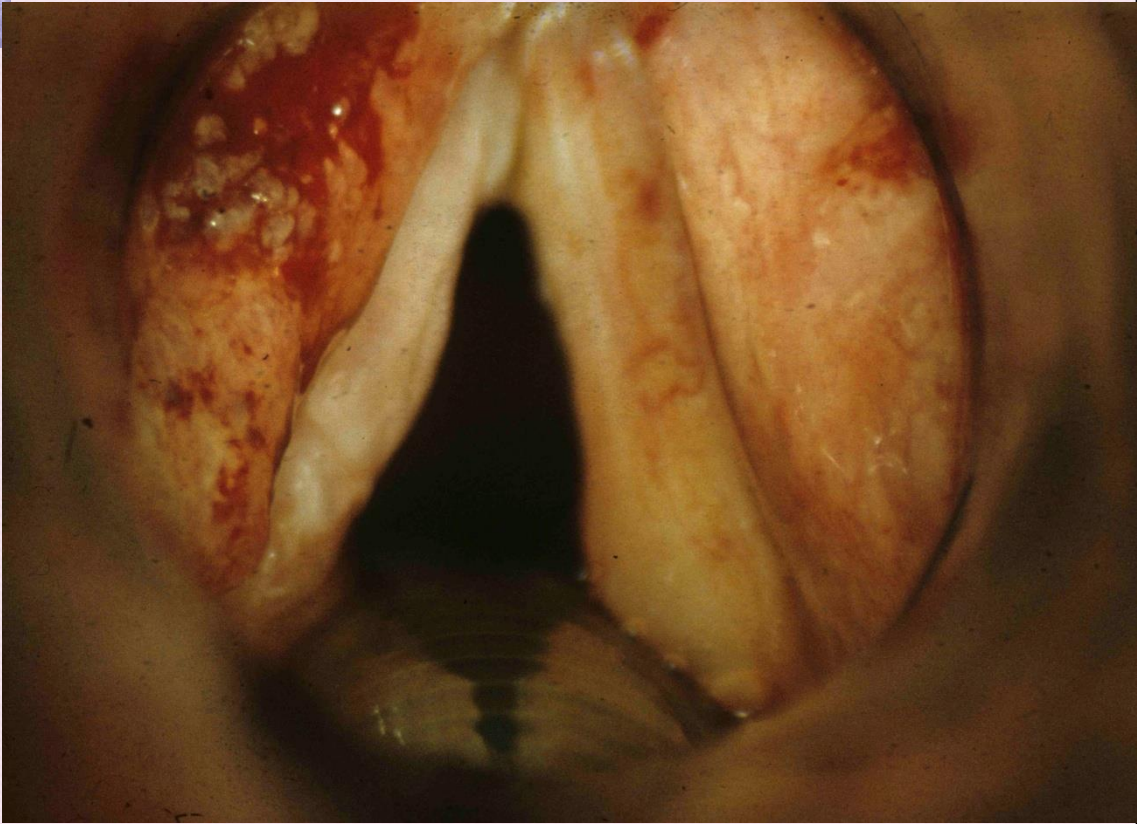
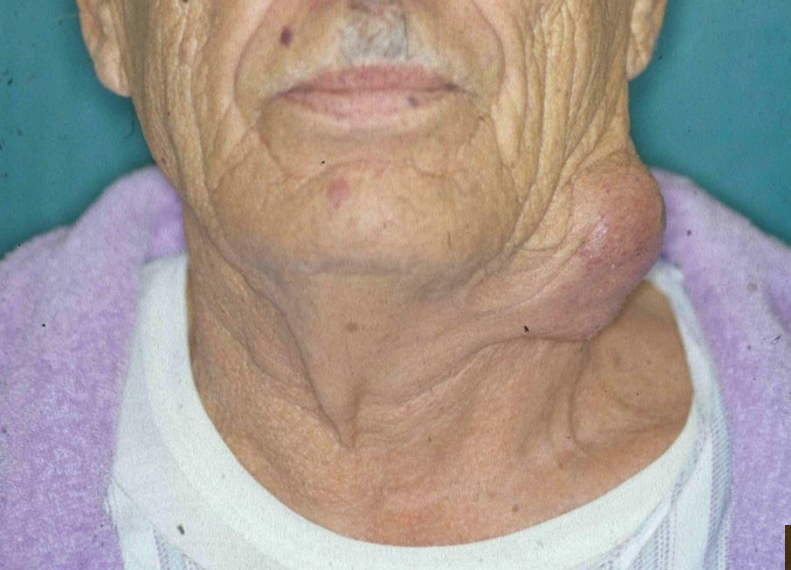
Metastases

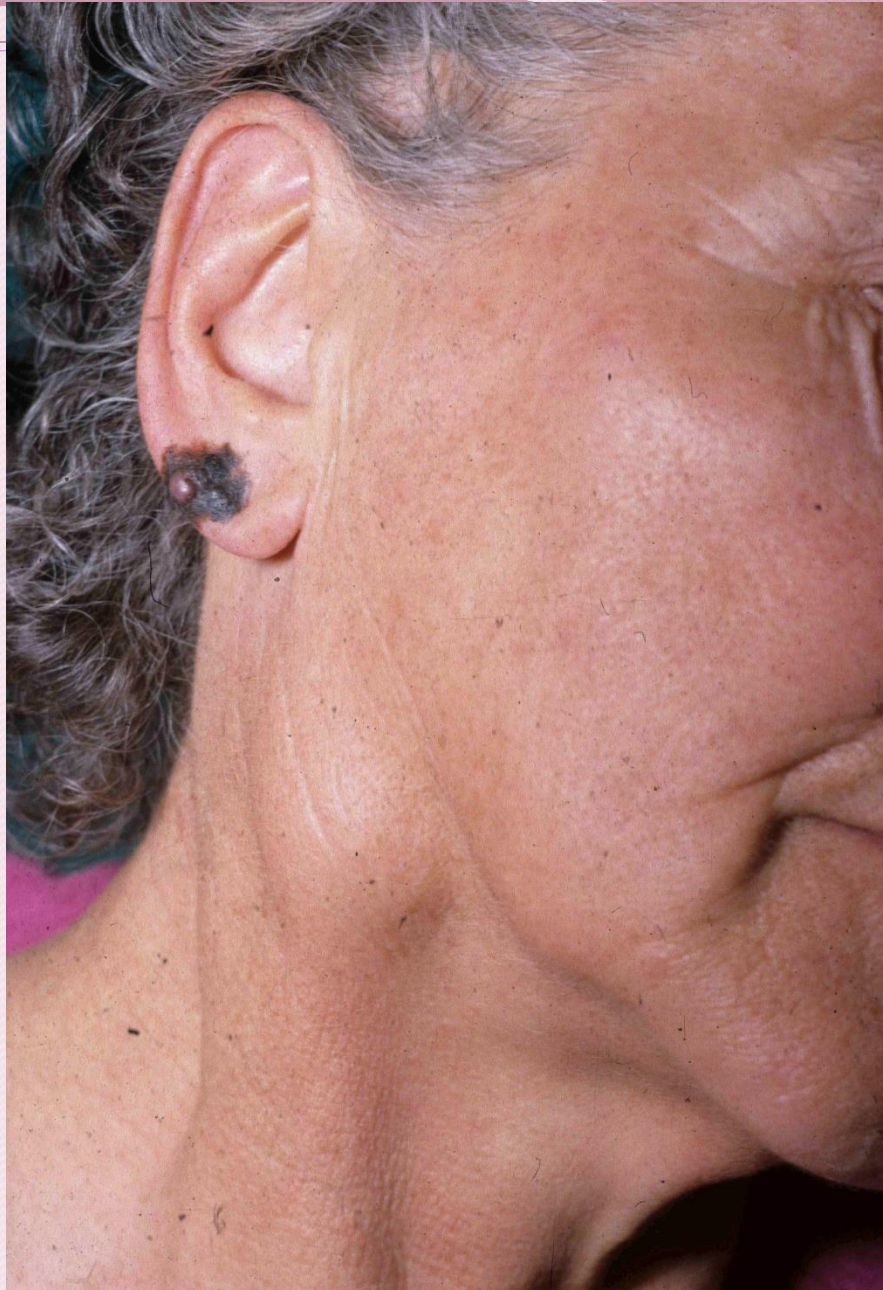

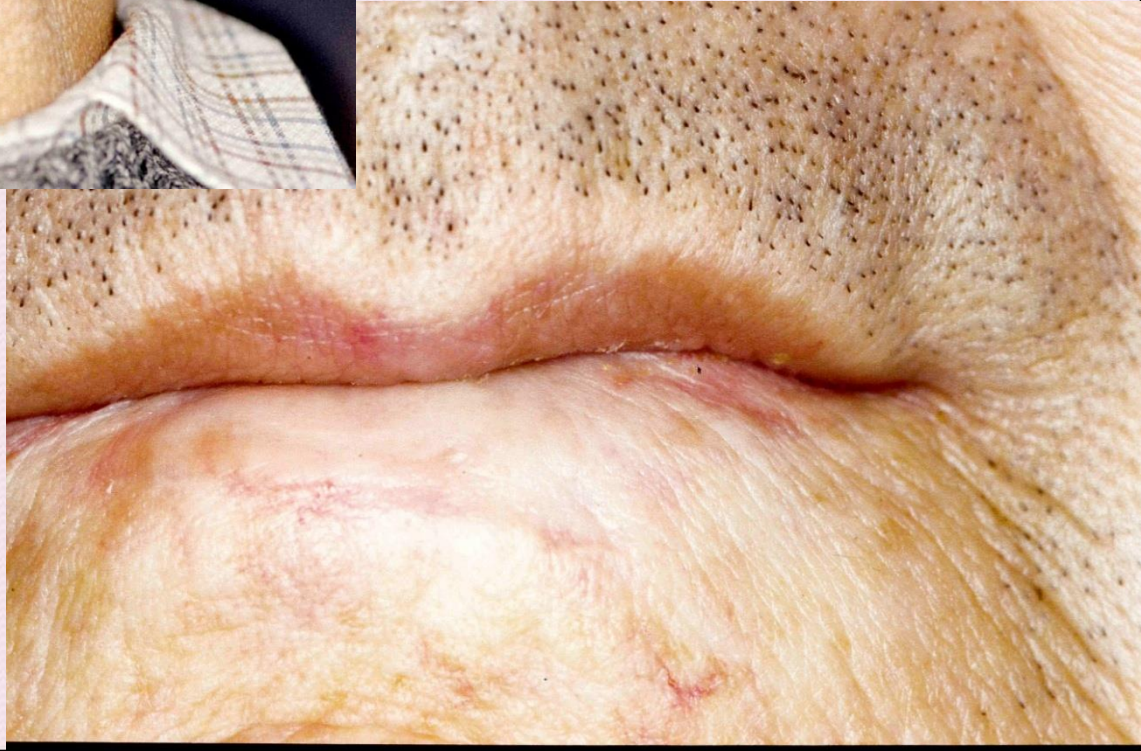

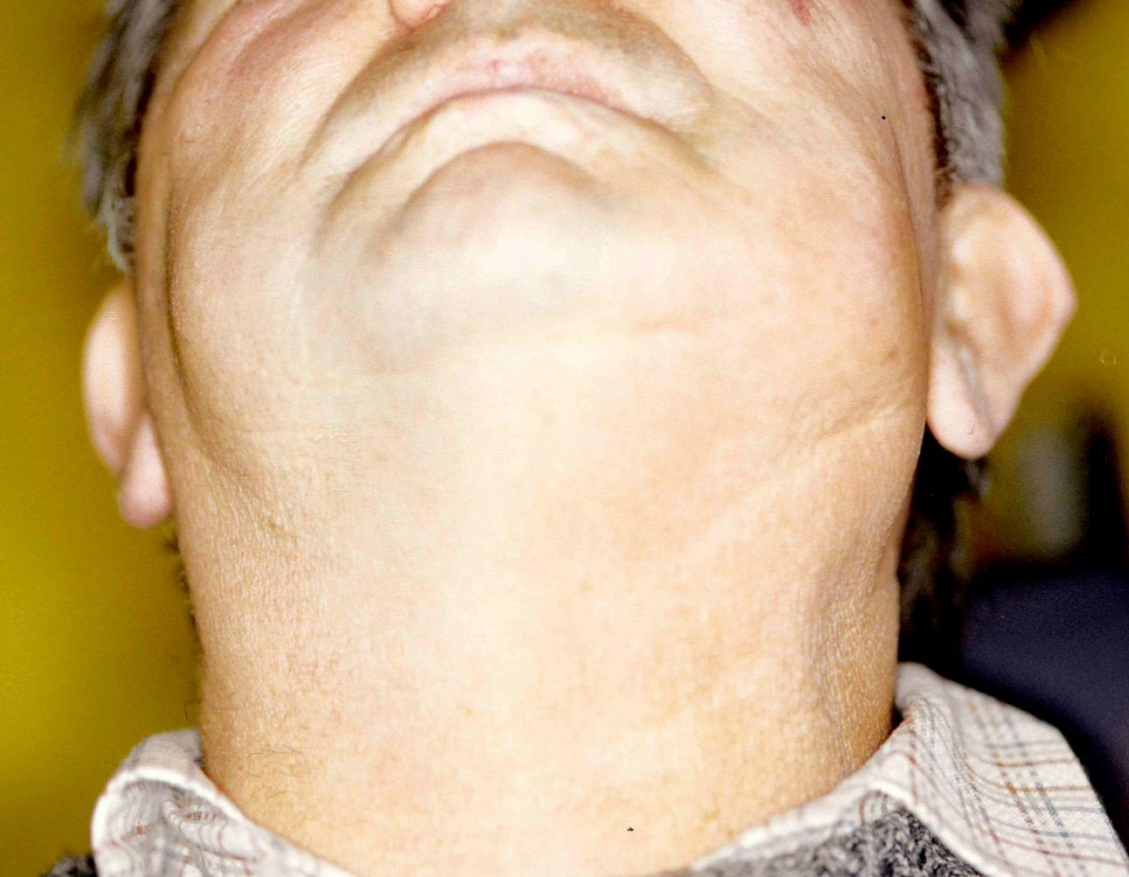


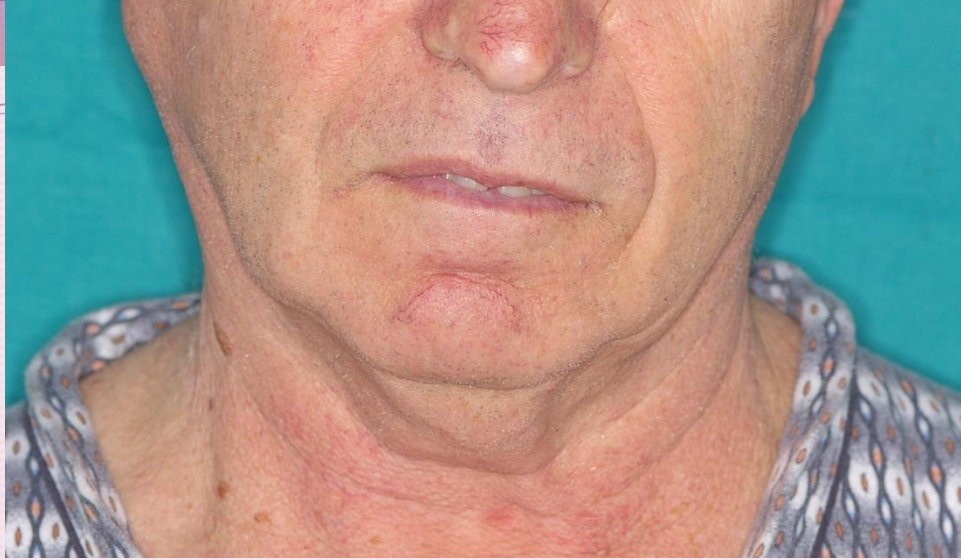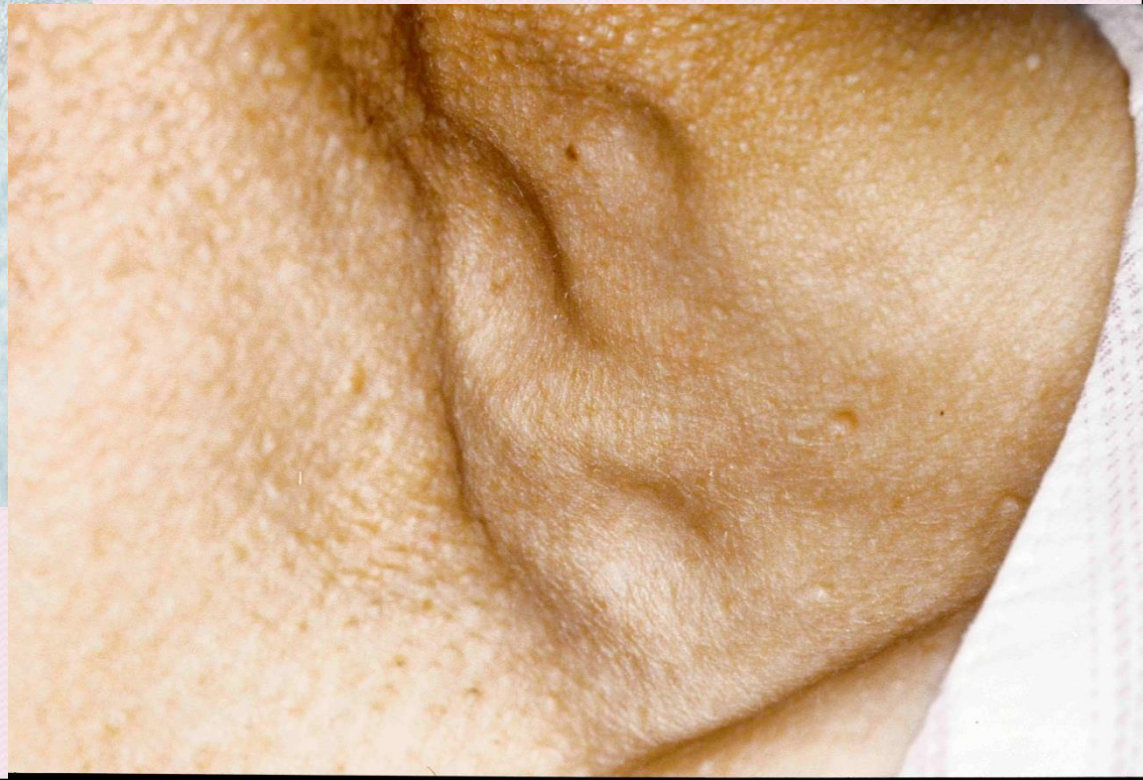



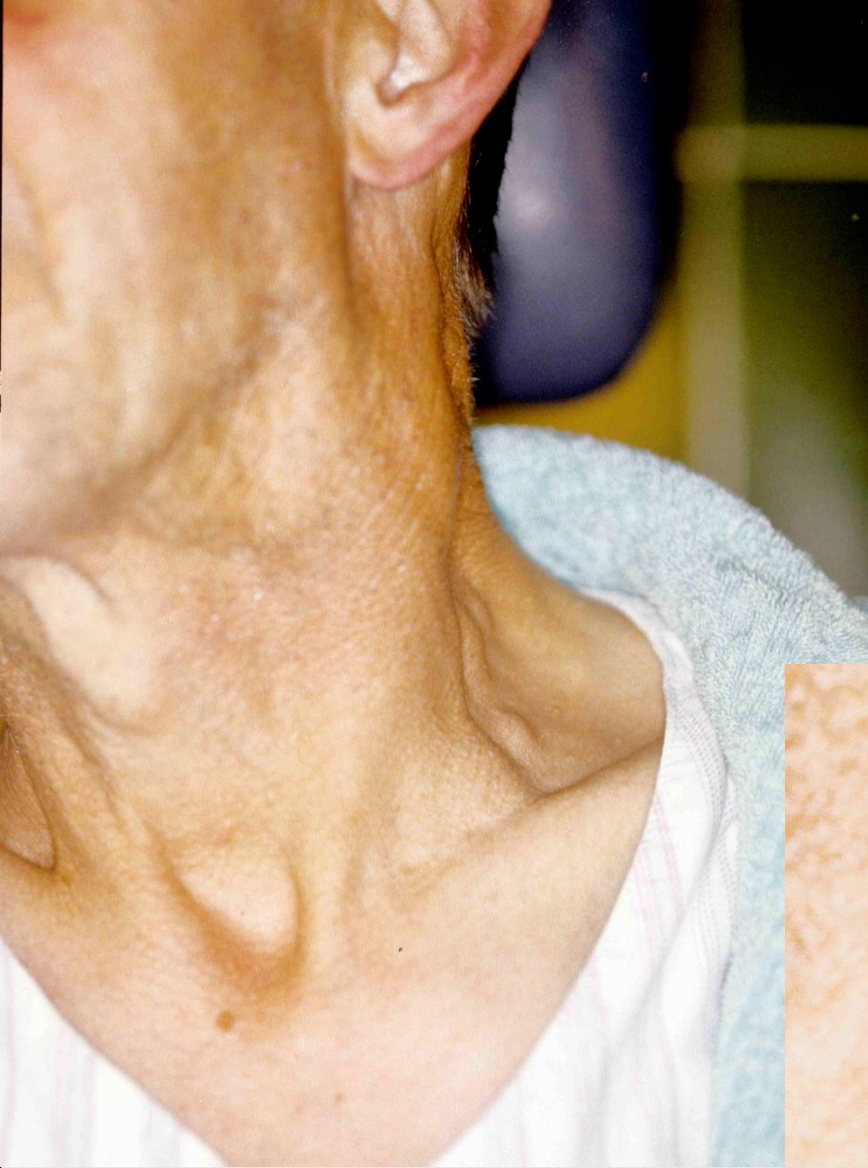


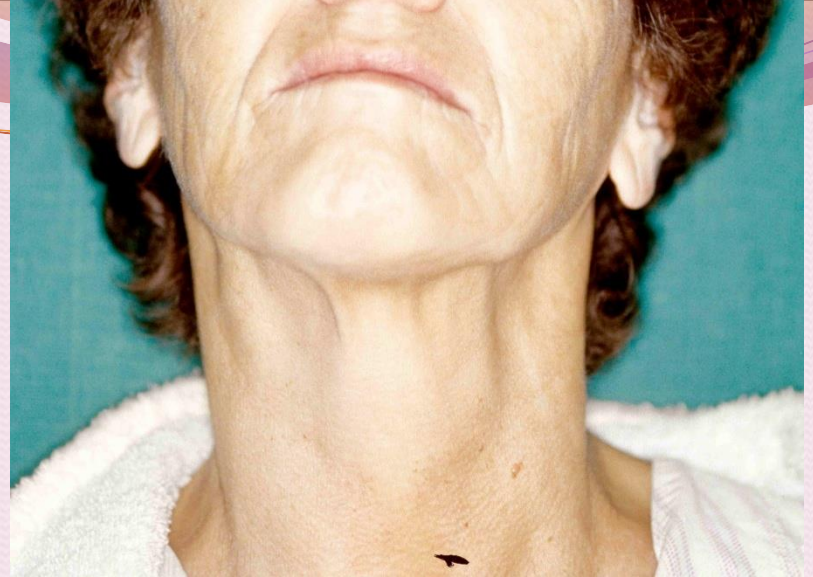
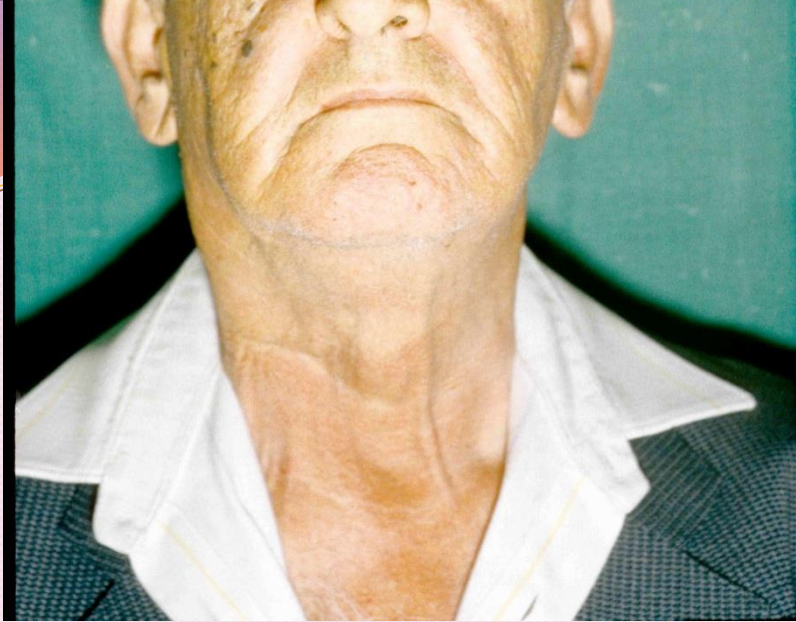


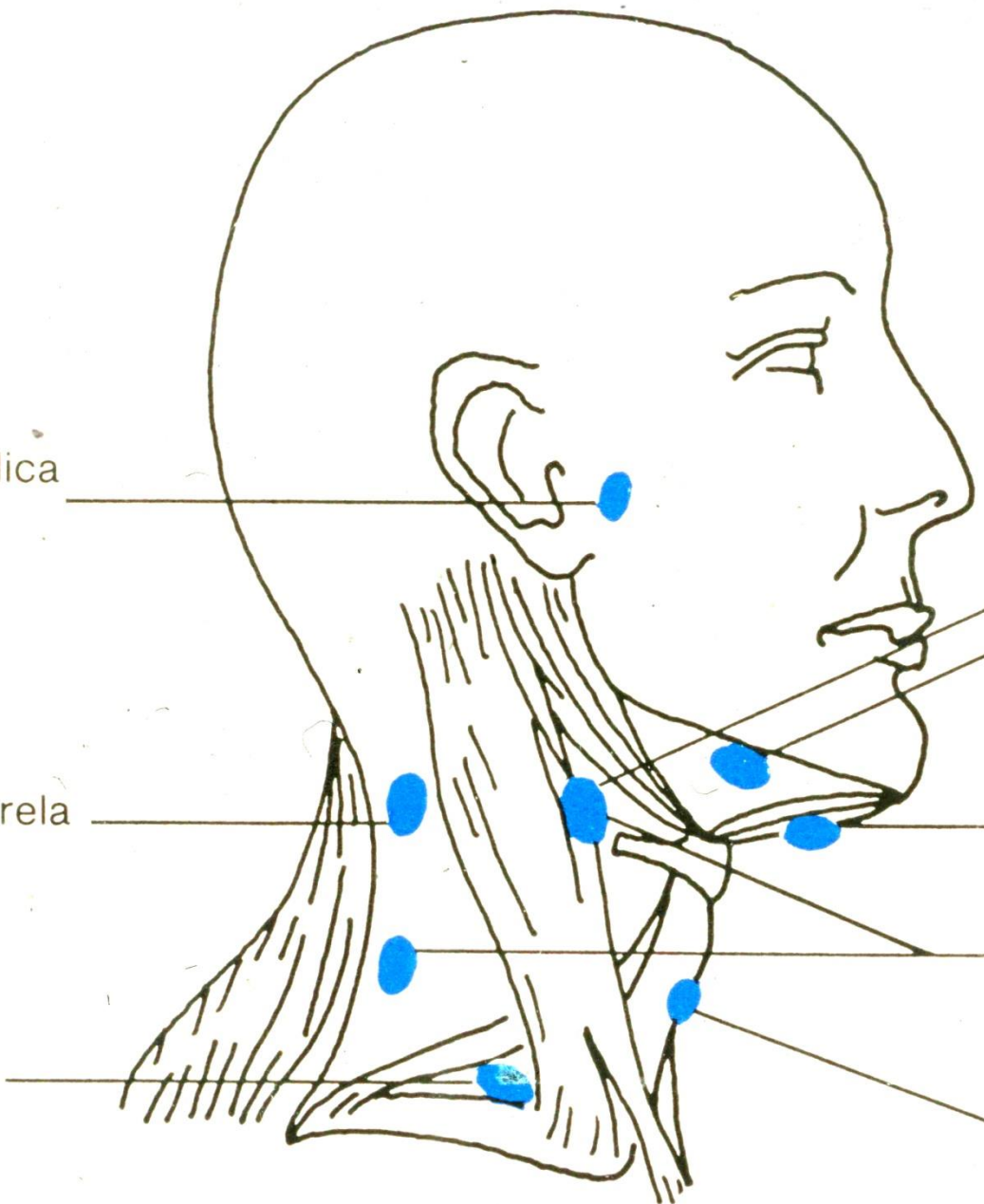




koža čela, lica
lasišče

nosni del žrela

ščitnica

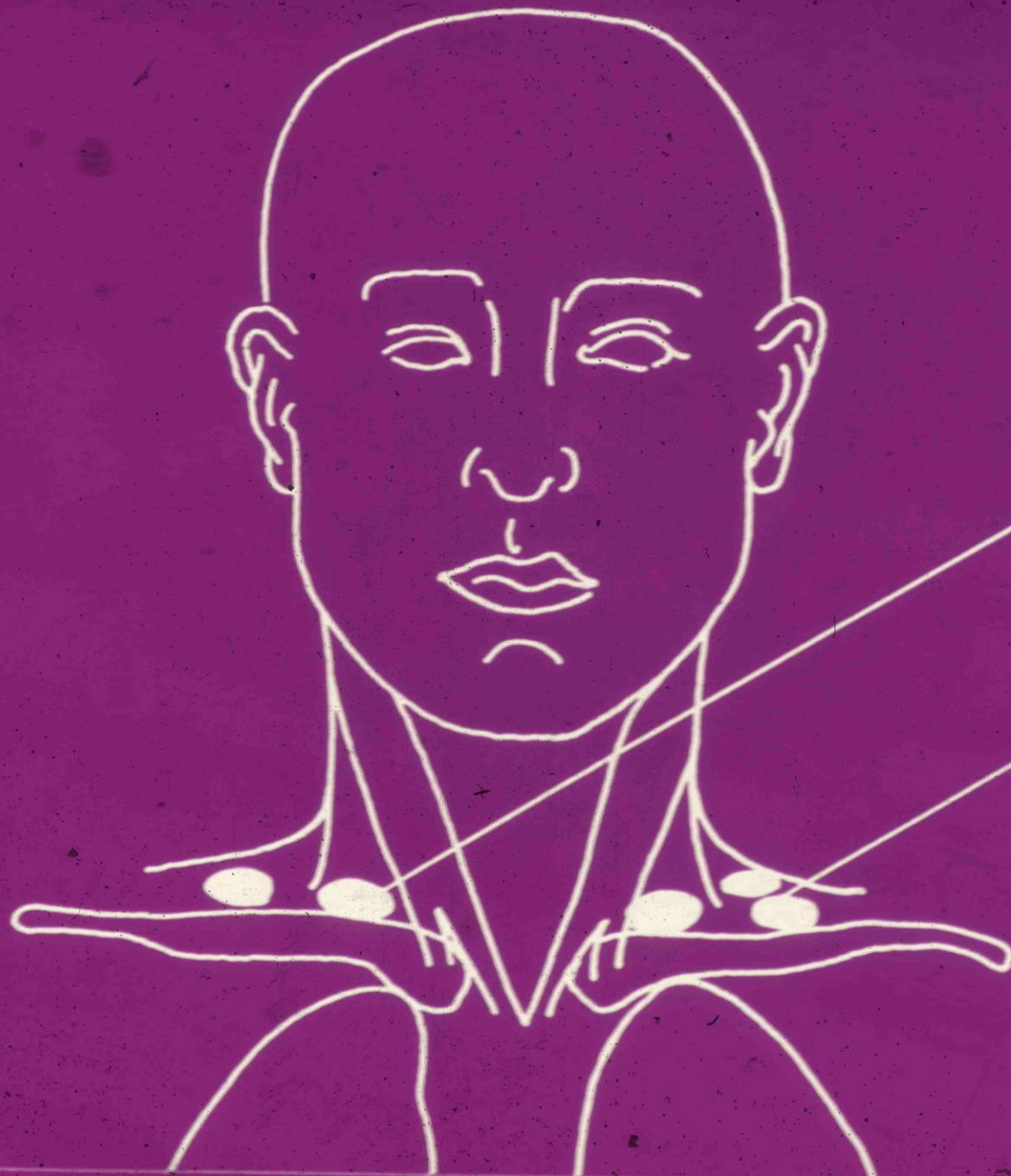


obnosne votline
ustno dno
ustnici
jezik

ustnica

srednji in
spodnji del
žrela
grlo

grlo
ščitnica



pljuča
dojka
želodec
prostata
debelo črevo
jajčnik
trebušna slinavka
maternica
modo

Patient with neck mass



General practitioner MD



history
examination
US of the neck
RTG of the lungs
laboratory



unclear
diagnosis



otorhinolaryngologist
Maxillofacial surgeon
oncologist
infectologist
plastic surgeon
dermatologist



Thin needle aspiration biopsy
Us guided aspiration biopsy
Surgical biopsy (excision)
US of the abdomen
CT and/or MRI of the neck
serology



Clear
diagnosis



treatment

observation



Clear
diagnosis

unclear
diagnosis



treatment

observation

Repeat the
examinations