

# Novosti v kardiologiji

Peter Radšel, KOIIM

Oktober 2019

**VSAKA IMA Sun  
mix**




**Sun  
mix SVOJ FAKTOR**

preventivna kardiologija  
akutna kardiologija  
nepredovalo srčno popuščanje  
valvularne bolezni  
kongenitalne bolezni  
žilne bolezni  
aritmologija  
elektrostimulacija  
intervencijska kardiologija  
arterijska hipertenzija  
ehokardiografija  
“kardio imaging”


Janez Nesreča, 40 let



**3 dni občasno bolečina v prsih**

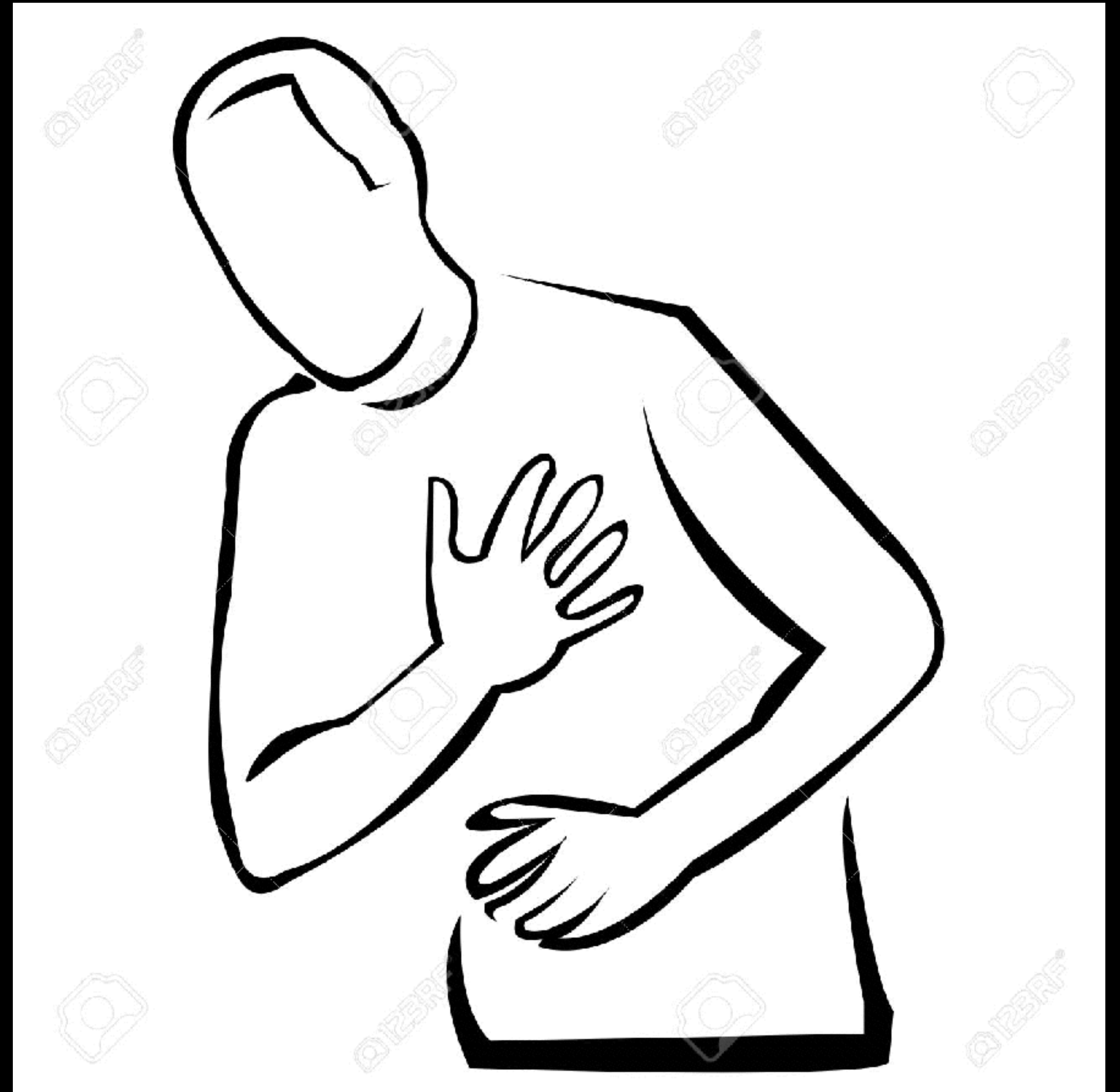


**IPP - NSTE AKS**



**KO za kardiologijo**

**predviden za koronarografijo naslednji dop**





**ESC**

European Society  
of Cardiology

European Heart Journal (2018) **00**, 1–33


doi:10.1093/eurheartj/ehy462

**EXPERT CONSENSUS DOCUMENT**


---

# **Fourth universal definition of myocardial infarction (2018)**

POŠKODBA MIOKARDA ≠ MIOKARDNI INFARKT ≠ AKUTNI KORONARNI SINDROM




cTn nad 99 percentilo



znaki ishemije:

- simptomi
- EKG spremembe
- spremembe pri slikovni diagnostiki



koronarna tromboza

tip 1

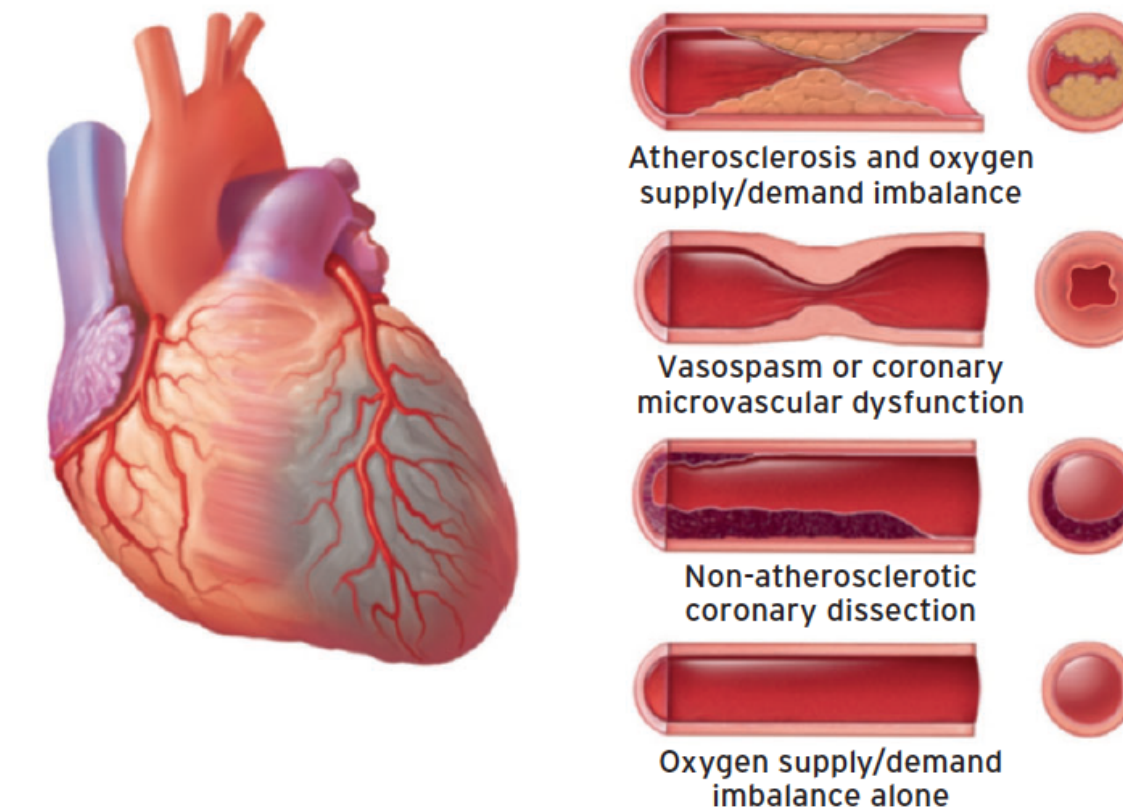
AKS

STEMI  
NSTE - AKS

tip 2

poraba O<sub>2</sub> > dobave

Myocardial Infarction Type 2



tip 3

nenadna smrt

tip 4

a – nativna kor.  
b – stent tr.  
c – stent rest.

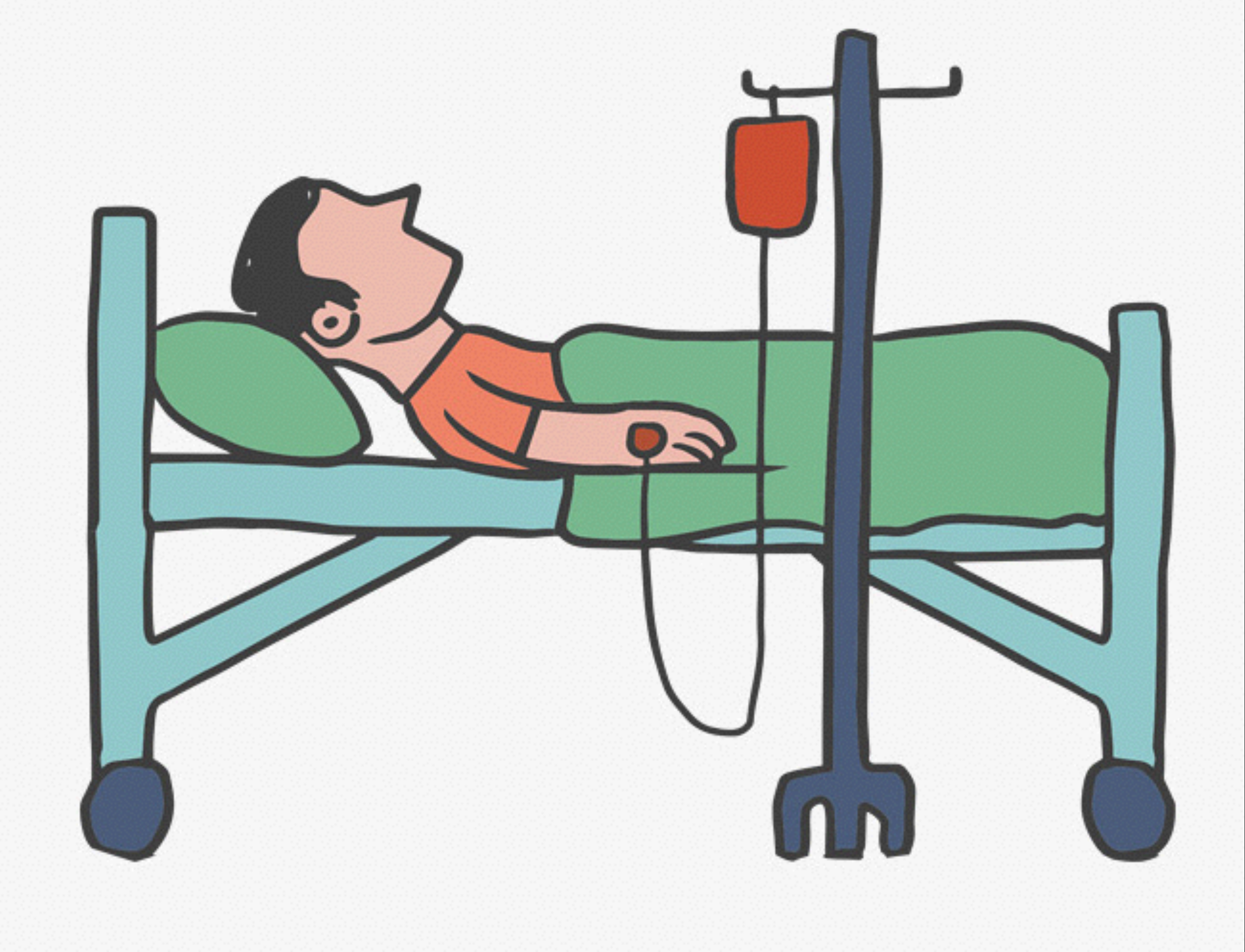
s PCI povezan

> 5 x zg. meja (>20% porast)  
+ EKG, slikovne spr.

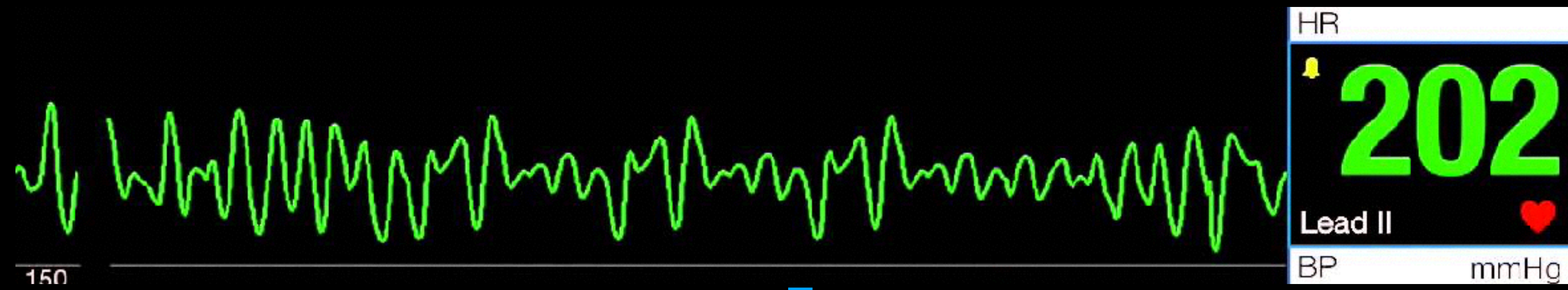
tip 5

s CABG povezan,  
TAVI,...

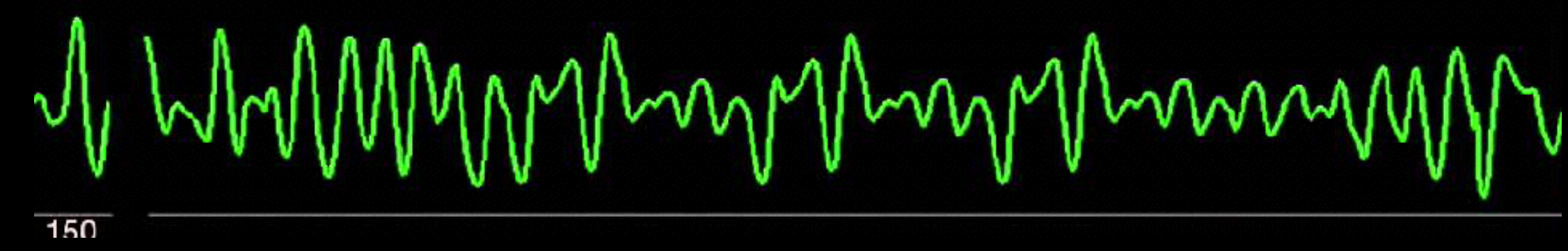
> 10 x zg. meja (>20% porast)



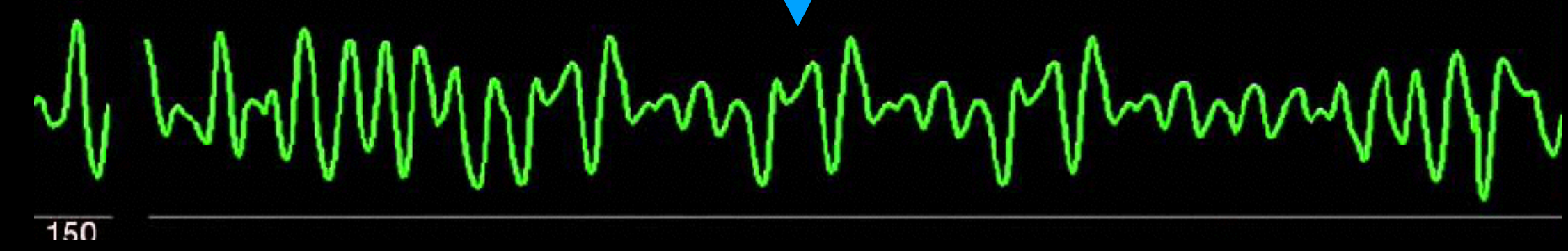




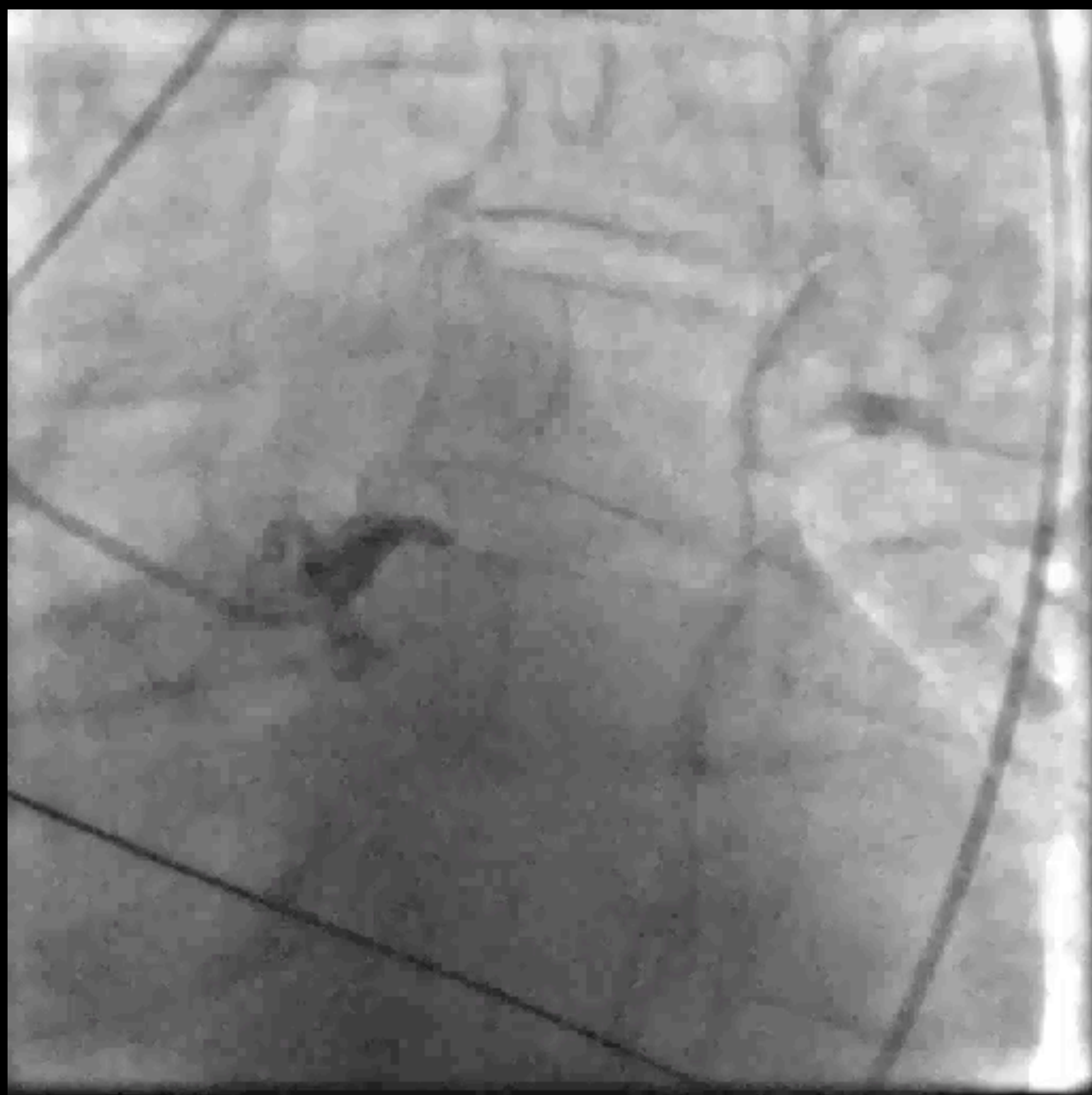**3 x defib**



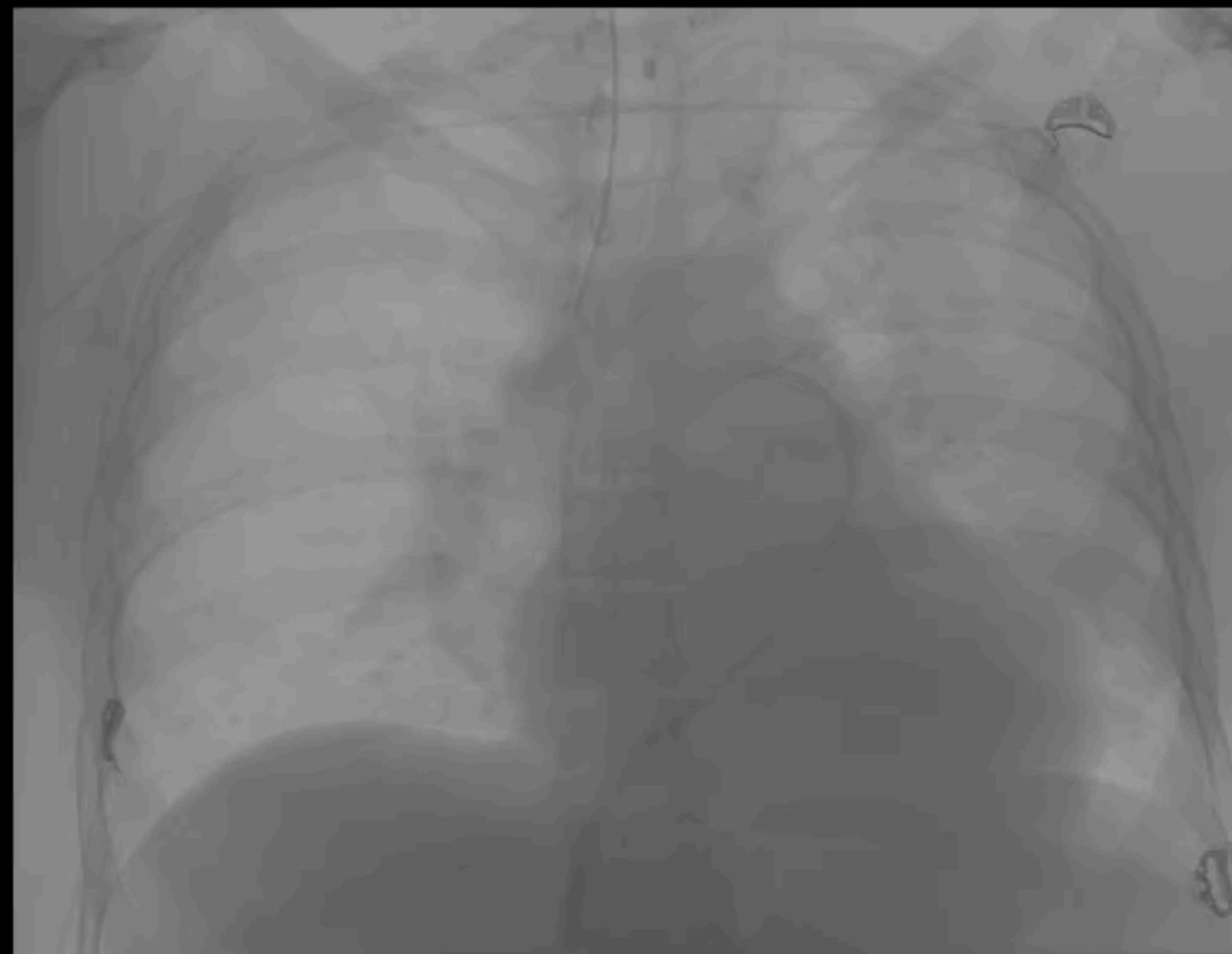**ALS 10 min**



# Kaj je v ozadju?

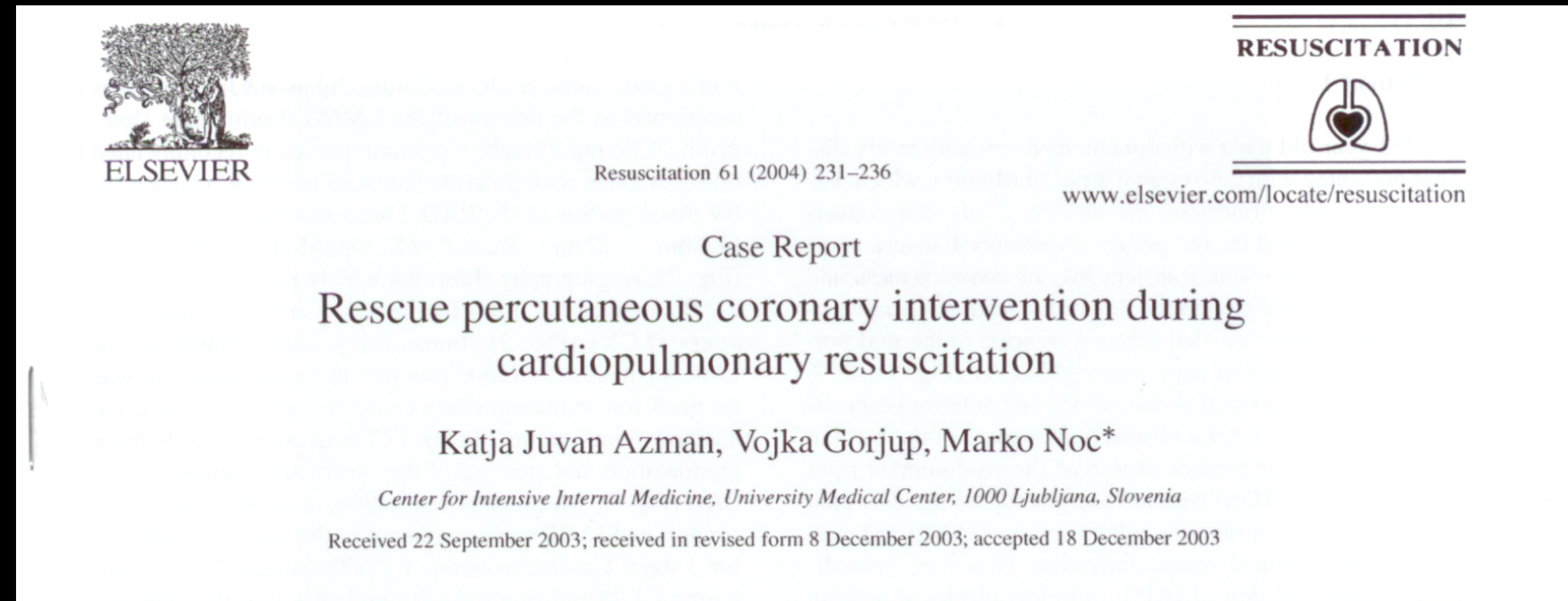


AKS



Pljučna embolija

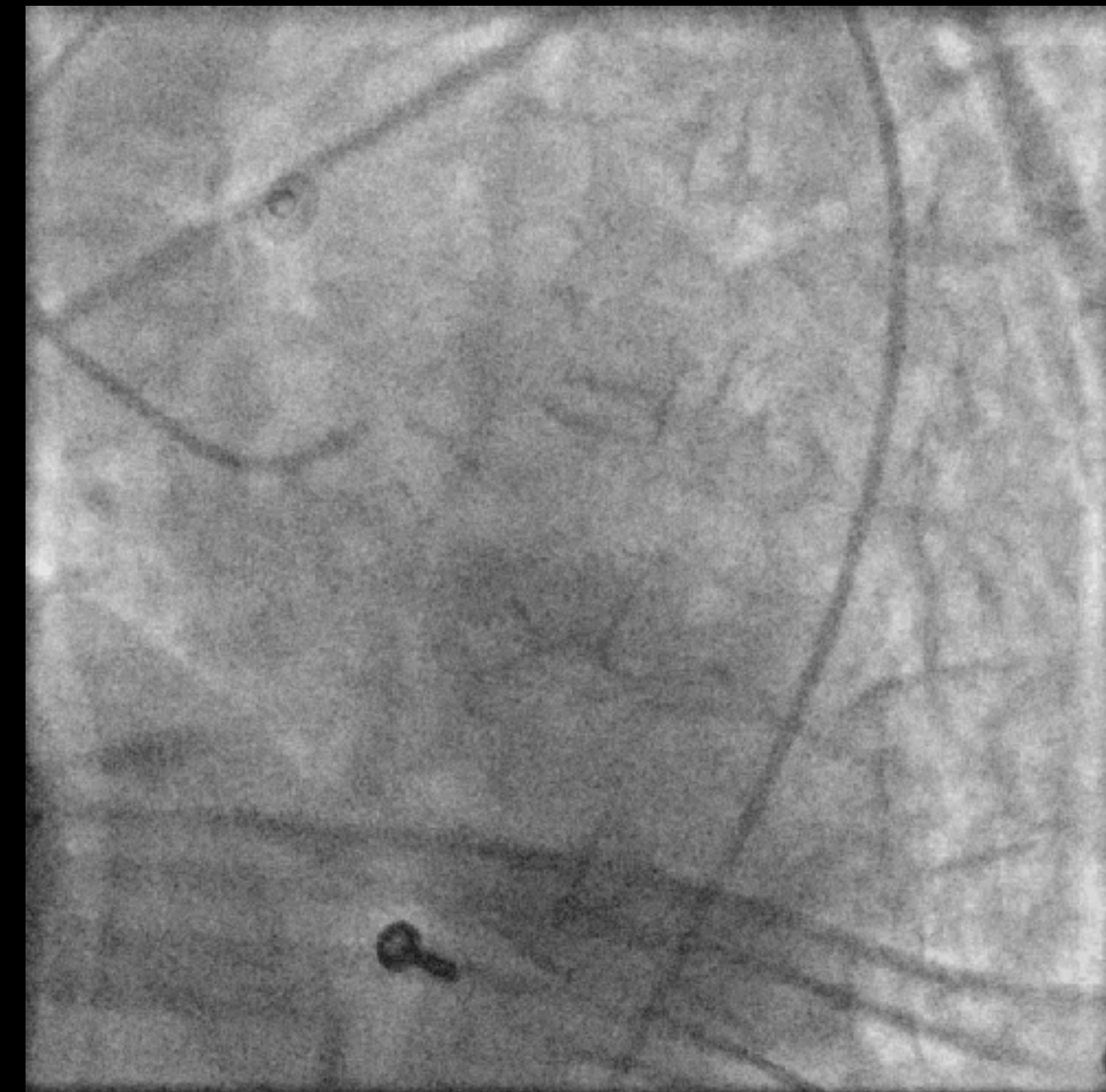# Preteklost



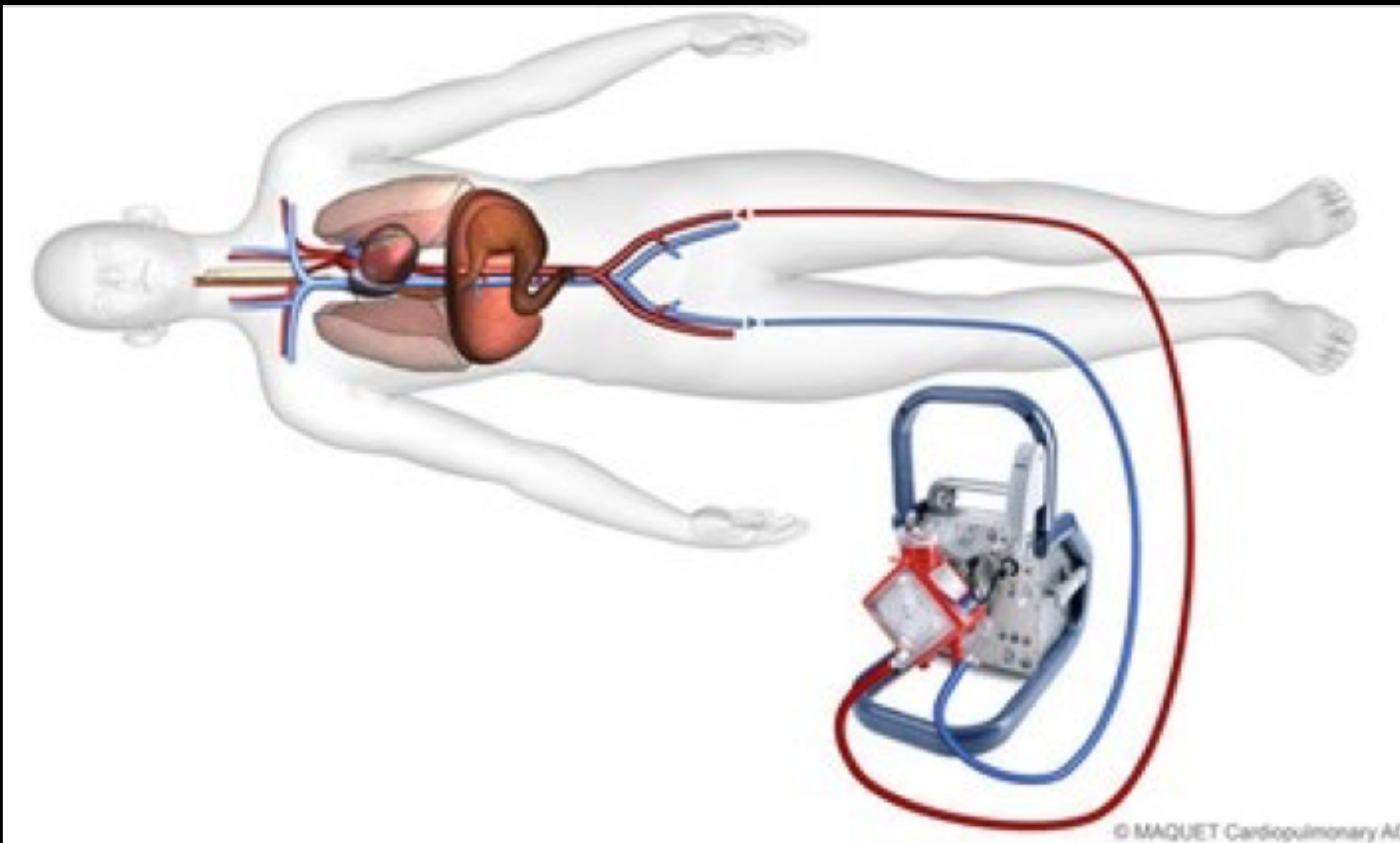
**43 bolnikov, pri 77% uspešna PCI,  
26% preživetje s CPC 1-2**

**Wagner H, et al. Resuscitation 2010;81:383-7**

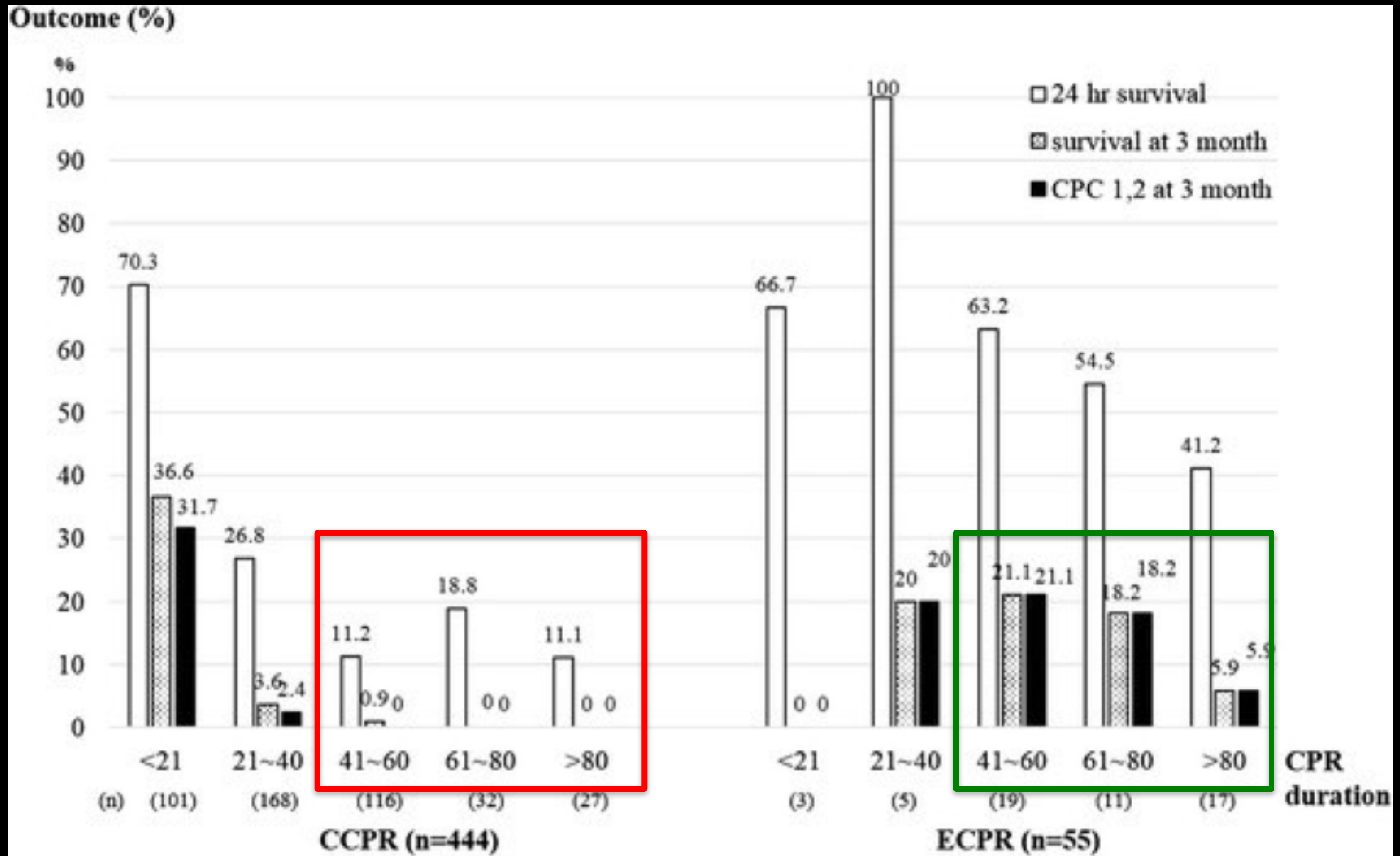
**V literaturi opisani samo uspešni primeri;  
pogosto brez ROSC tudi po odprtju koronarne arterije!**



## E-CPR

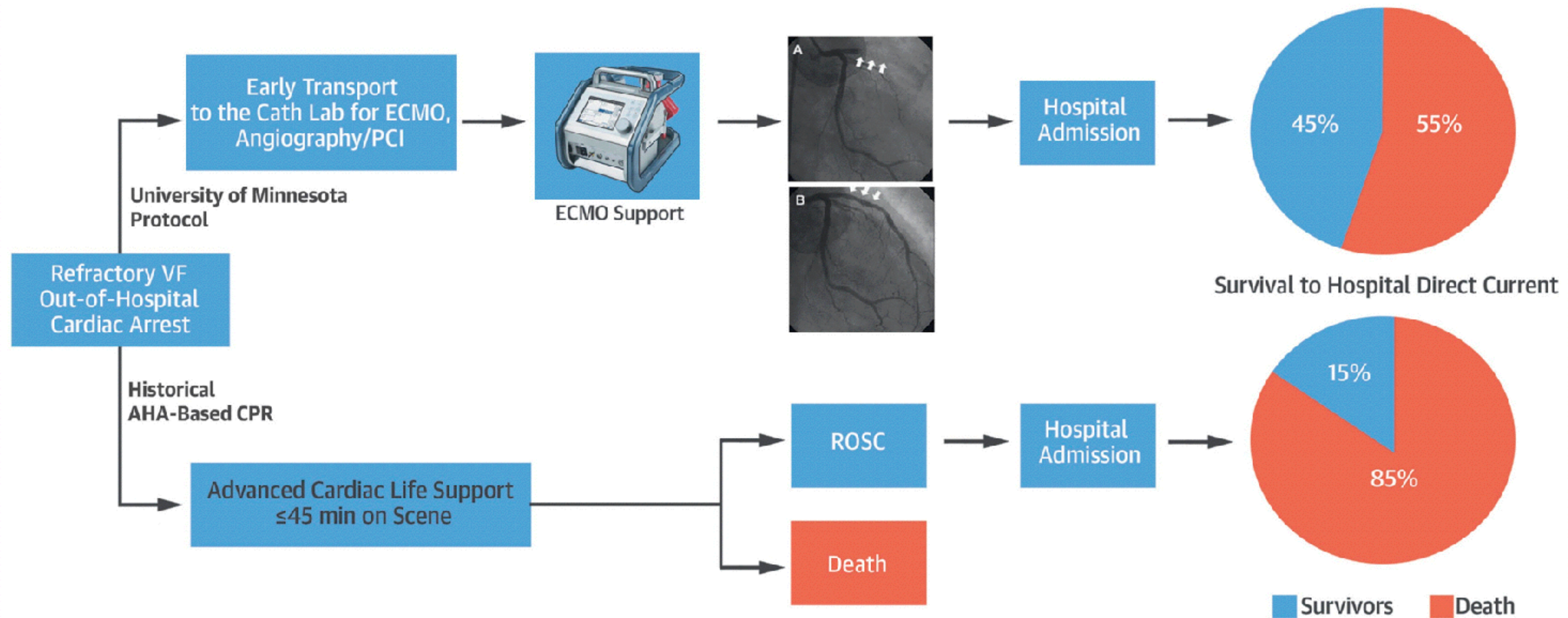


# ECPR - podatki o preživetju





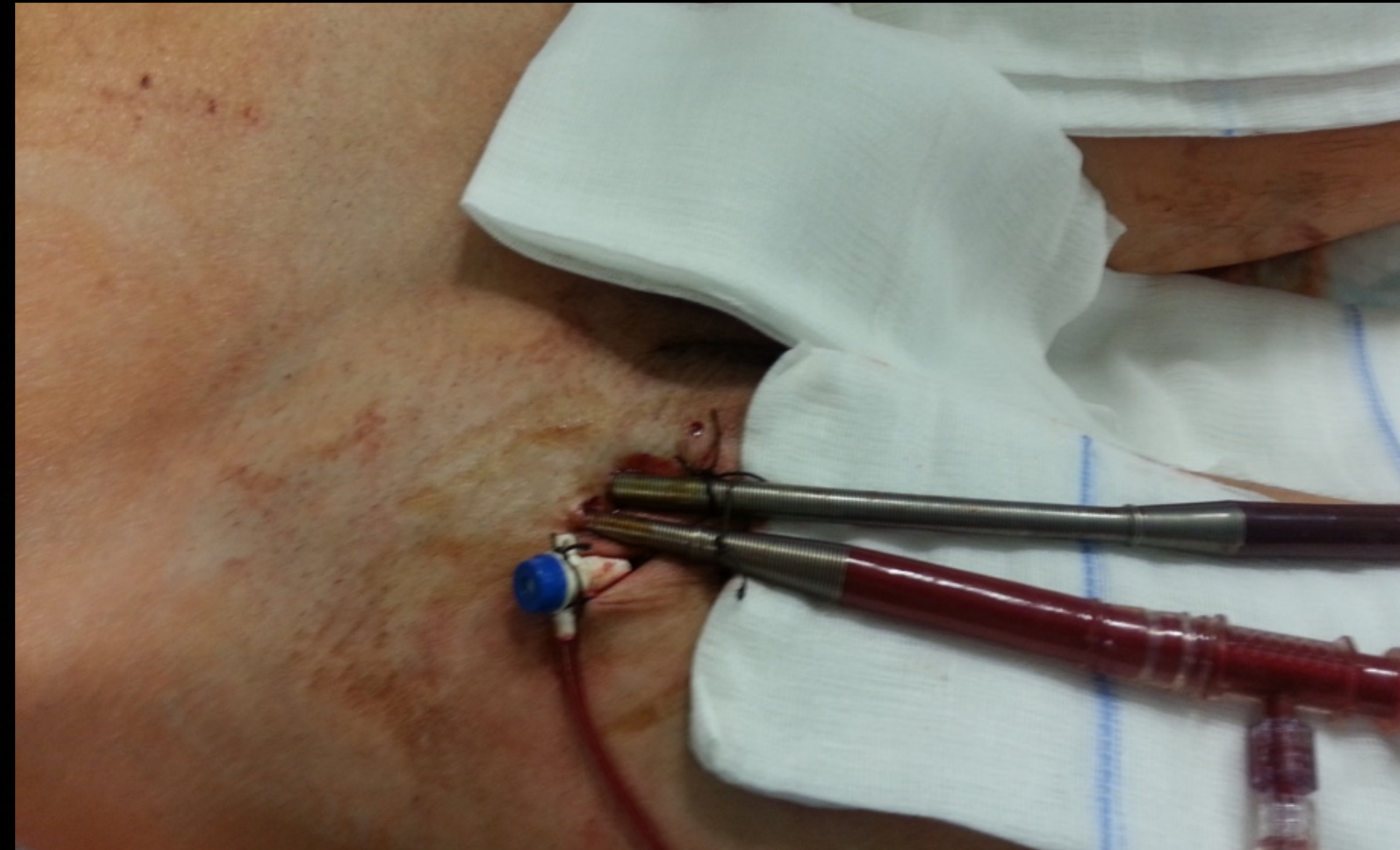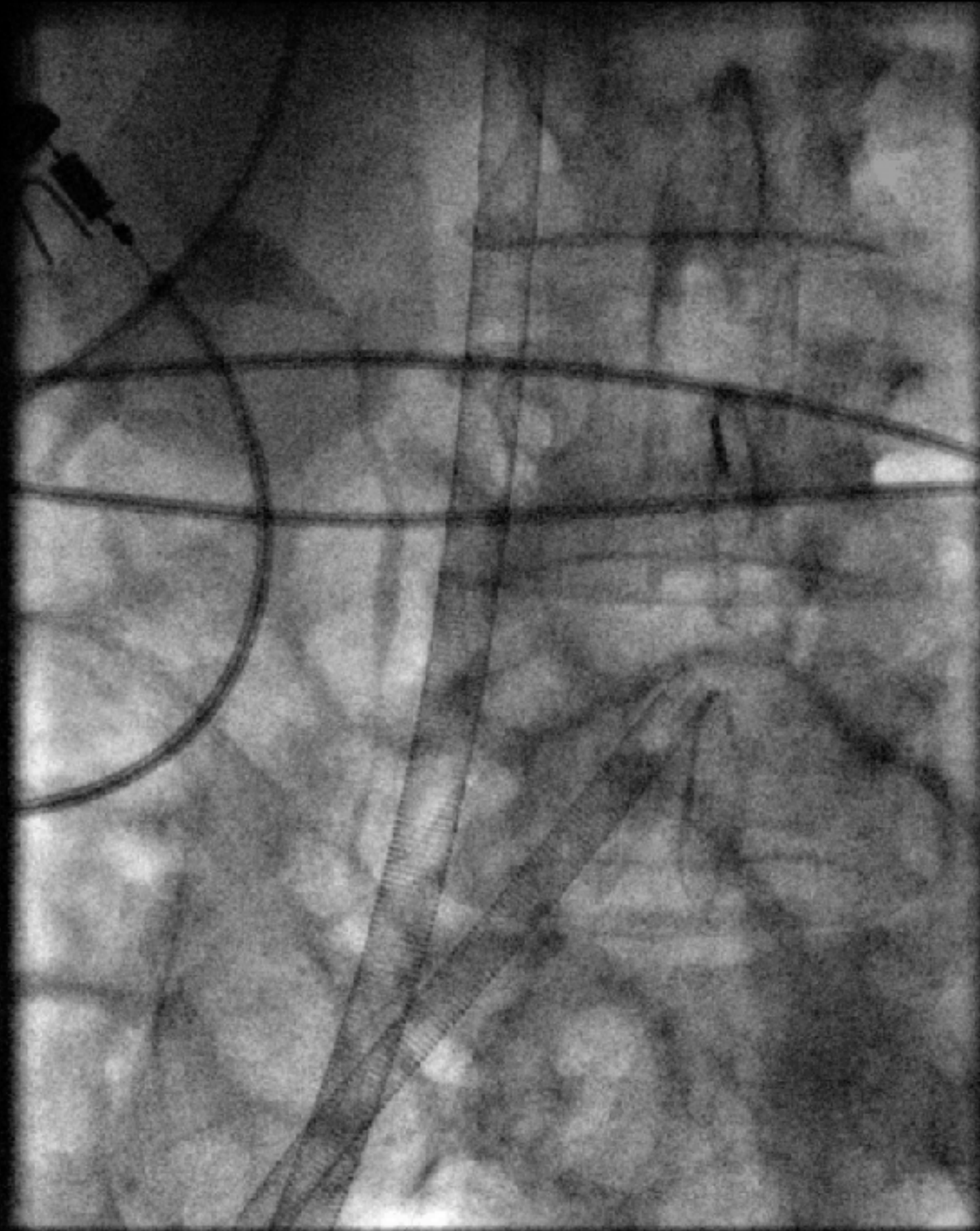
## CENTRAL ILLUSTRATION: Refractory Cardiac Arrest Due to VF/VT and the University of Minnesota ECLS/PCI Protocol



Yannopoulos, D. et al. J Am Coll Cardiol. 2017;70(9):1109-17.



# Perkutana vstavitev VA - ECMO

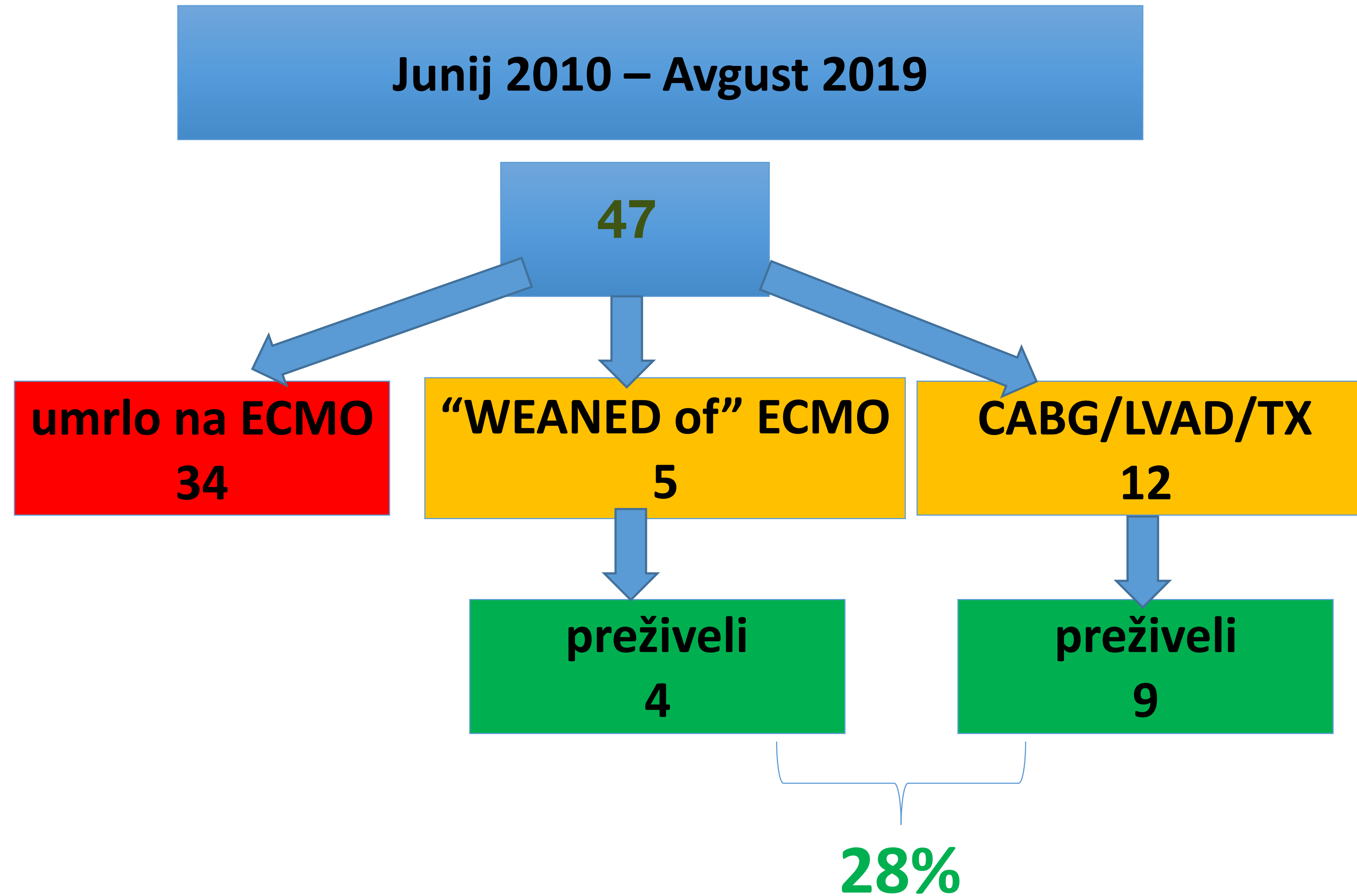


Goslar T, Knafelj R, Radsel P, Fister M, Golcnik A, Steblovnik K, Gorjup V, Noc M.

Emergency percutaneous implantation of veno-arterial extracorporeal membrane oxygenation in the catheterisation laboratory. *EuroIntervention*. 2016



# ECPR



- **Bolnik <65 let**
- Brez pomembnih bolezni
- Srčni zastoj pred pričami
- BLS
- Dostopni čas <10 min
- **VF/VT prvi ritem**

- Brez ROSC po **10 min ALS**
- Predviden dostopni čas do **UKC Lj <20 min**

Klic v KOIIM – **01/522 8952**

- Med prevozom **neprekinjen ALS**
- Svetovana uporaba mehničnega pripomočka za stiskanje prsnega koša
- Razmisli o uporabi pasivne insuflacije taheje s kisikom

Ponoven klic v primeru ROSC

- **Vstavitev V-A ECMO** v kateterizacijskem laboratoriju
- Nadaljna diagnostika

Image size: 512 x 512  
View size: 652 x 586  
WL: 124 WW: 205

4445/11 ( 65 y , 64 y )  
Coronaries - unnamed  
0  
1

+ stenoza RCA

• PPCI LAD + DES



# The NEW ENGLAND JOURNAL of MEDICINE

ESTABLISHED IN 1812

DECEMBER 21, 2017

VOL. 377 NO. 25

## PCI Strategies in Patients with Acute Myocardial Infarction and Cardiogenic Shock

H. Thiele, I. Akin, M. Sandri, G. Fuernau, S. de Waha, R. Meyer-Saraei, P. Nordbeck, T. Geisler, U. Landmesser, C. Skurk, A. Fach, H. Lapp, J.J. Piek, M. Noc, T. Goslar, S.B. Felix, L.S. Maier, J. Stepinska, K. Oldroyd, P. Serpytis, G. Montalescot, O. Barthelemy, K. Huber, S. Windecker, S. Savonitto, P. Torremante, C. Vrints, S. Schneider, S. Desch, and U. Zeymer, for the CULPRIT-SHOCK Investigators\*

Zoom: 128% Angle: 0

Im: 34/58

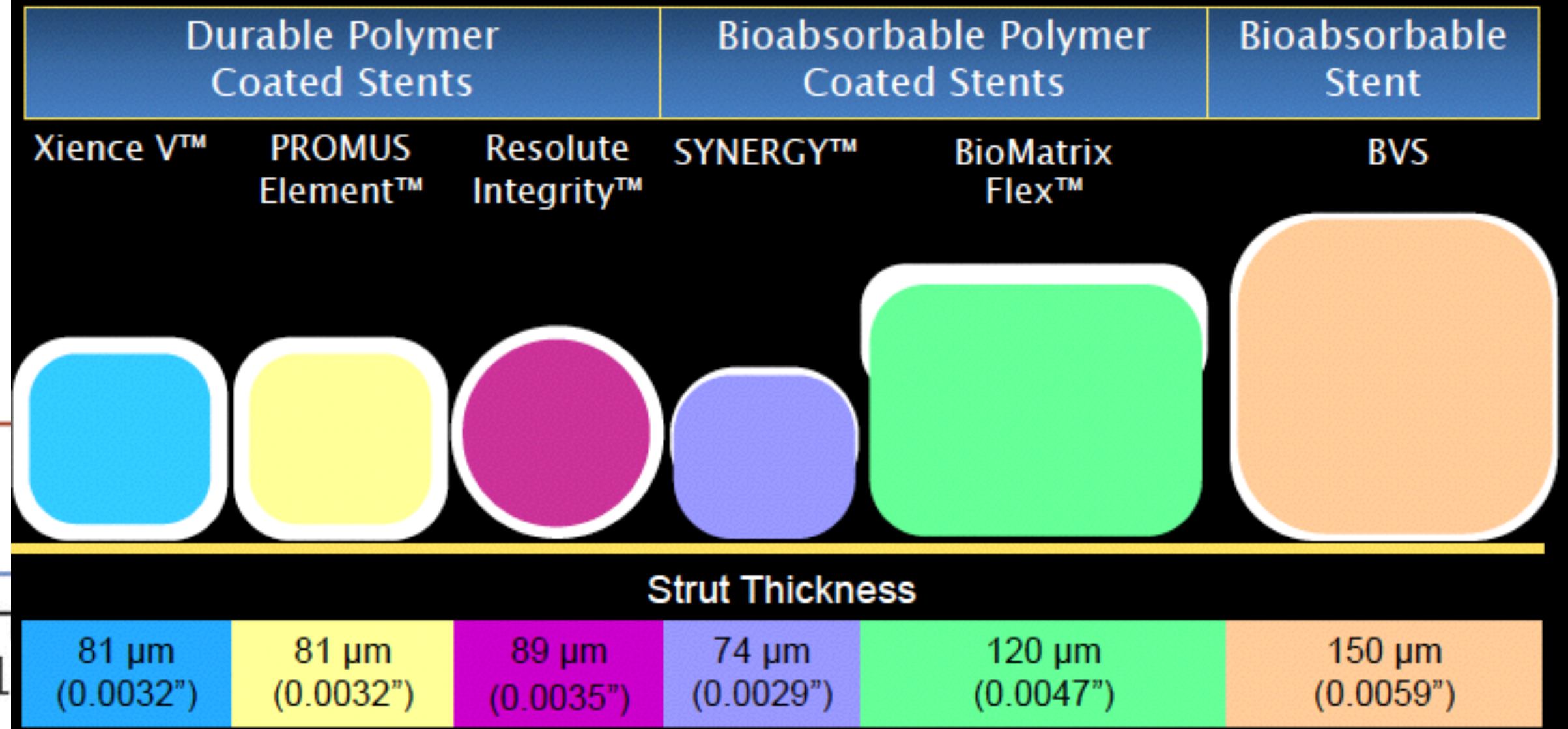
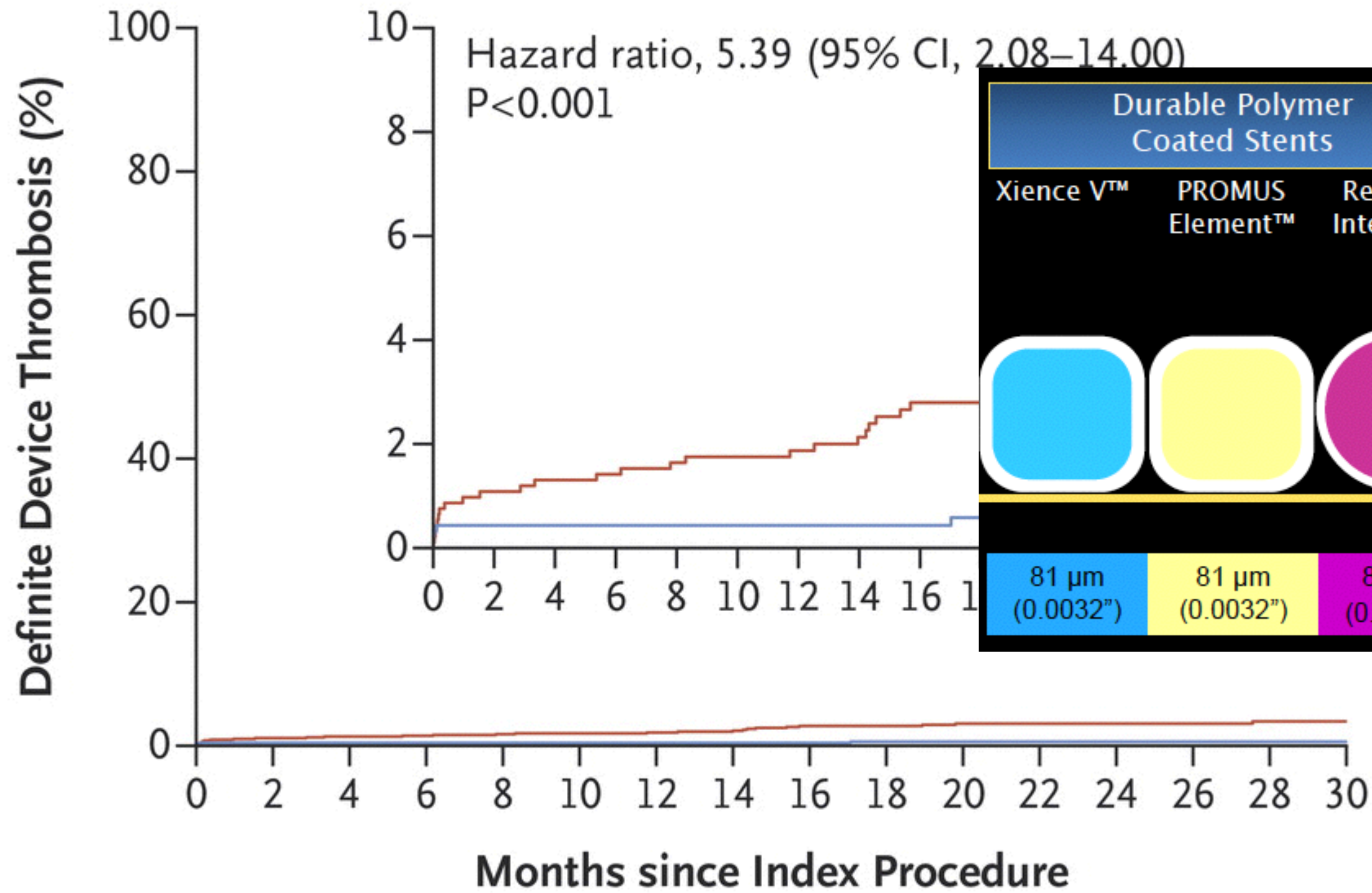
JPEGLossless:Non-hierarchical-1 stOrderPrediction

6/12/11 5:41:14

Made In Osirix

# Bioresorbable Scaffolds versus Metallic Stents in Routine PCI

A



Published Ahead of Print on May 10, 2017 as 10.1212/WNL.00000000000003966

SPECIAL ARTICLE



# Practice guideline summary: Reducing brain injury following cardiopulmonary resuscitation

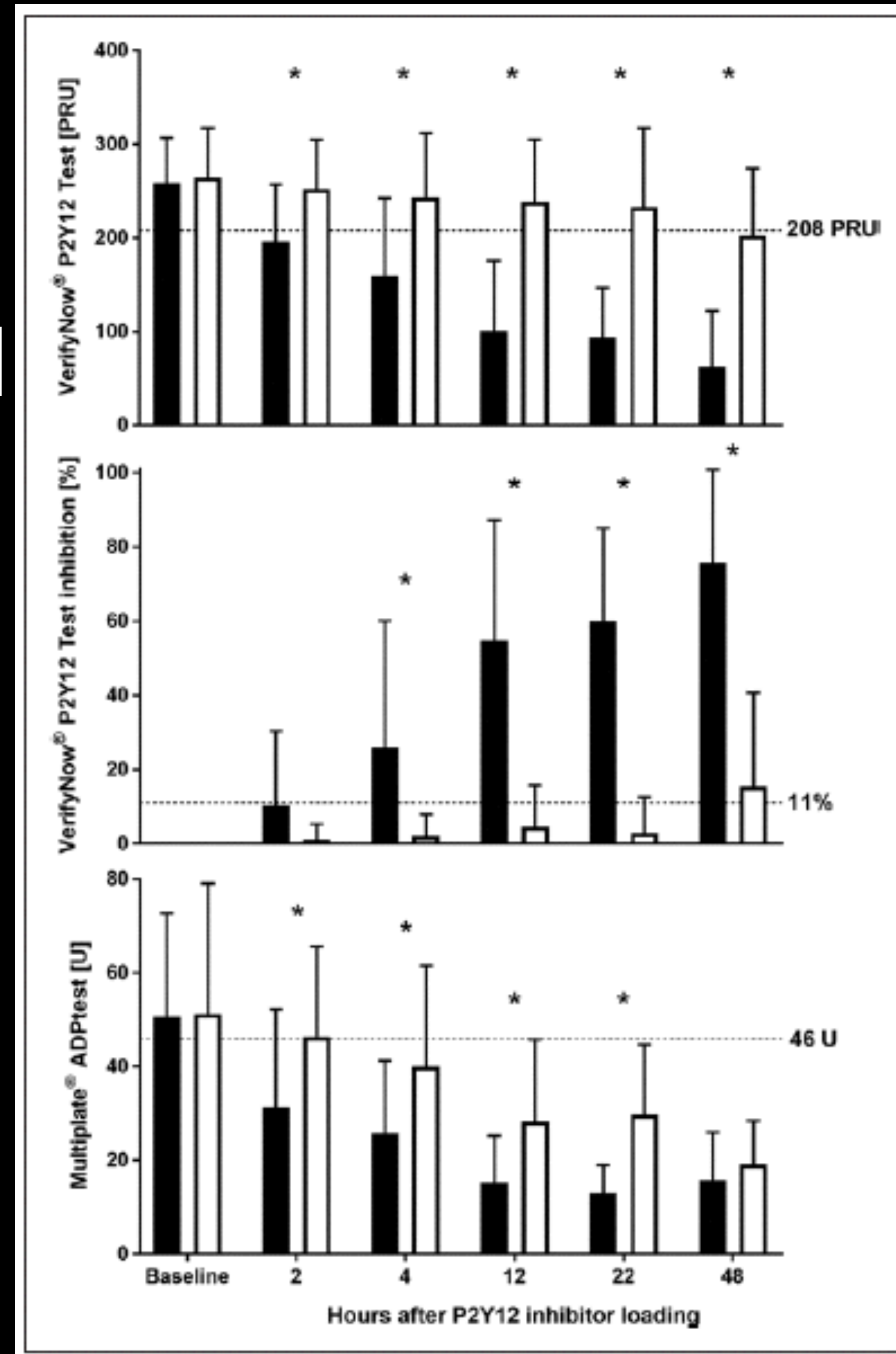
Report of the Guideline Development, Dissemination, and Implementation Subcommittee of the American Academy of Neurology



# Ticagrelor Versus Clopidogrel in Comatose Survivors of Out-of-Hospital Cardiac Arrest Undergoing Percutaneous Coronary Intervention and Hypothermia: A Randomized Study.

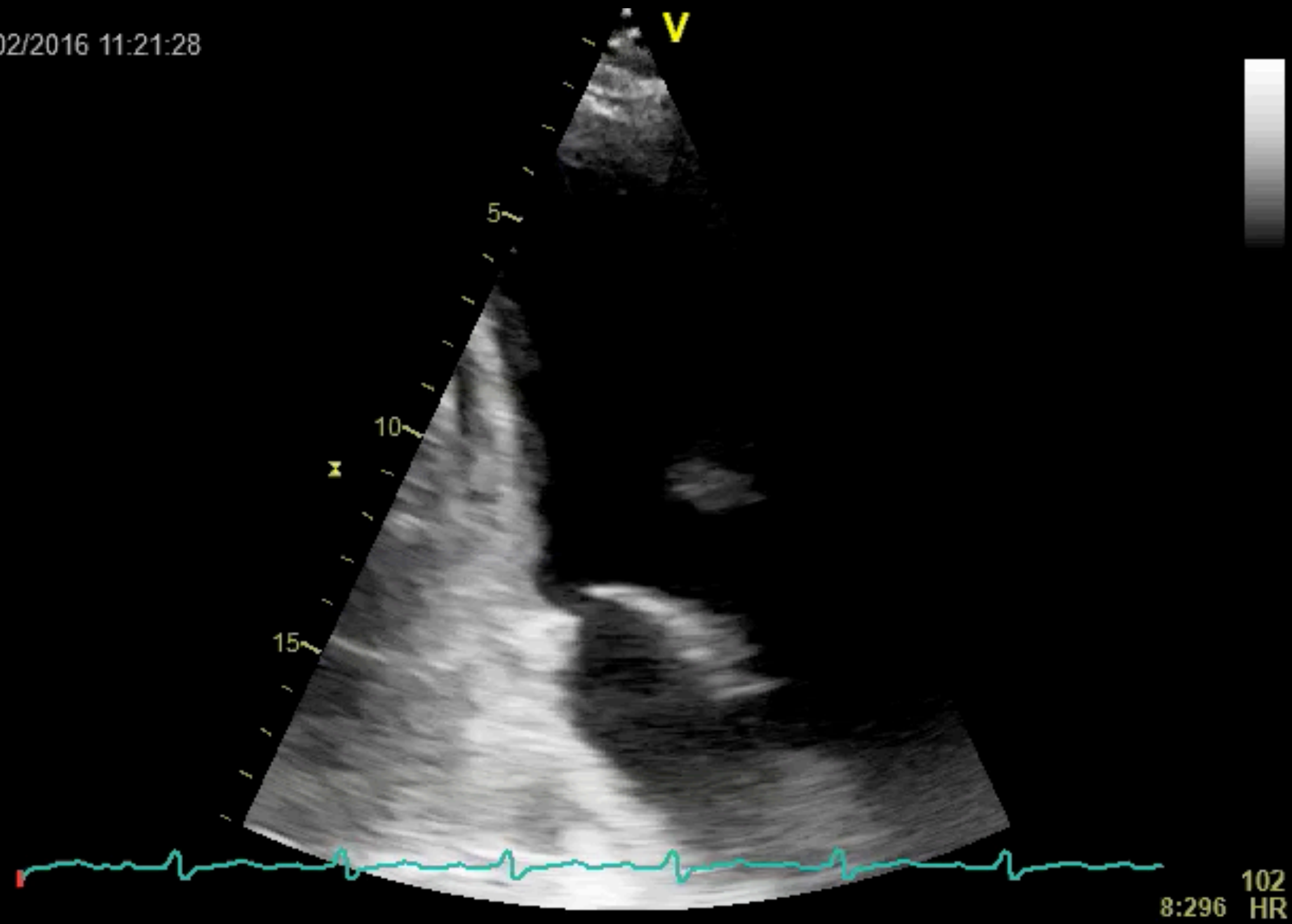
ASA i.v. + ticagrelor

Steblovnik K, Blinc A, Mijovski MB, Fister M, Mikuz U, Noc M. Ticagrelor Versus Clopidogrel in Comatose Survivors of Out-of-Hospital Cardiac Arrest Undergoing Percutaneous Coronary Intervention and Hypothermia: A Randomized Study. *Circulation*. 2016 Dec 20;134(25):2128-2130.



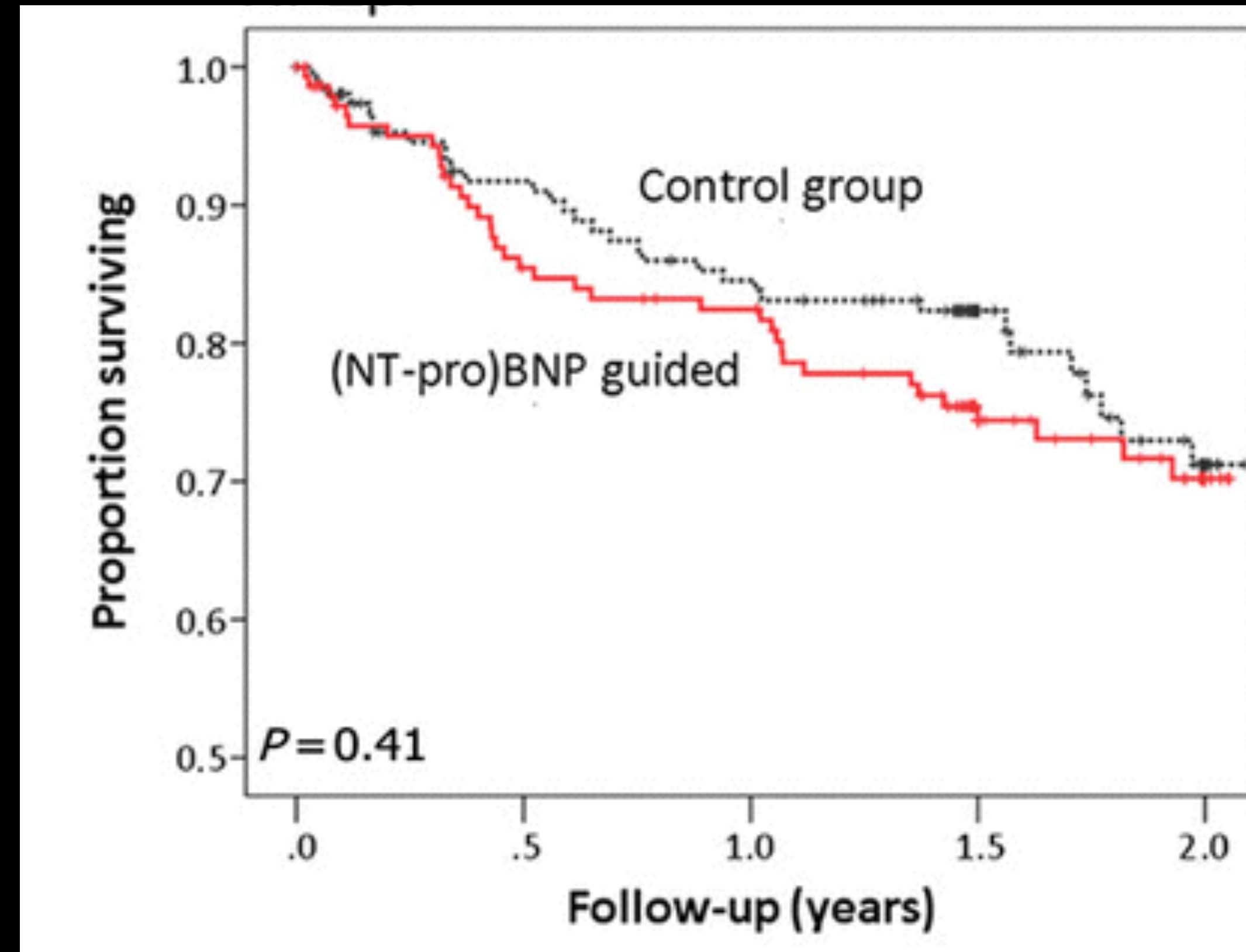
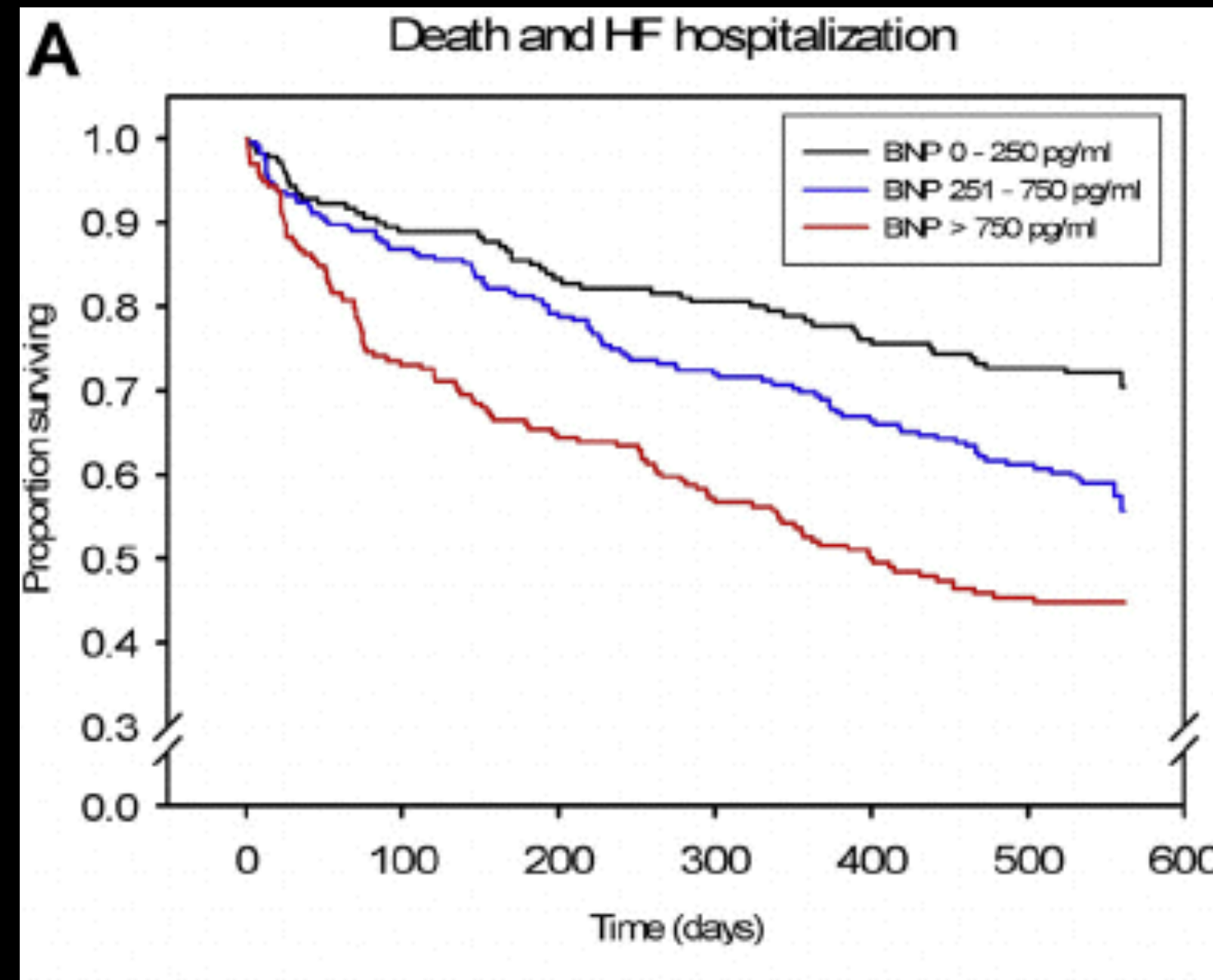
# ECMO odstranjen 5. dan

24/02/2016 11:21:28



NT pro BNP 15.000

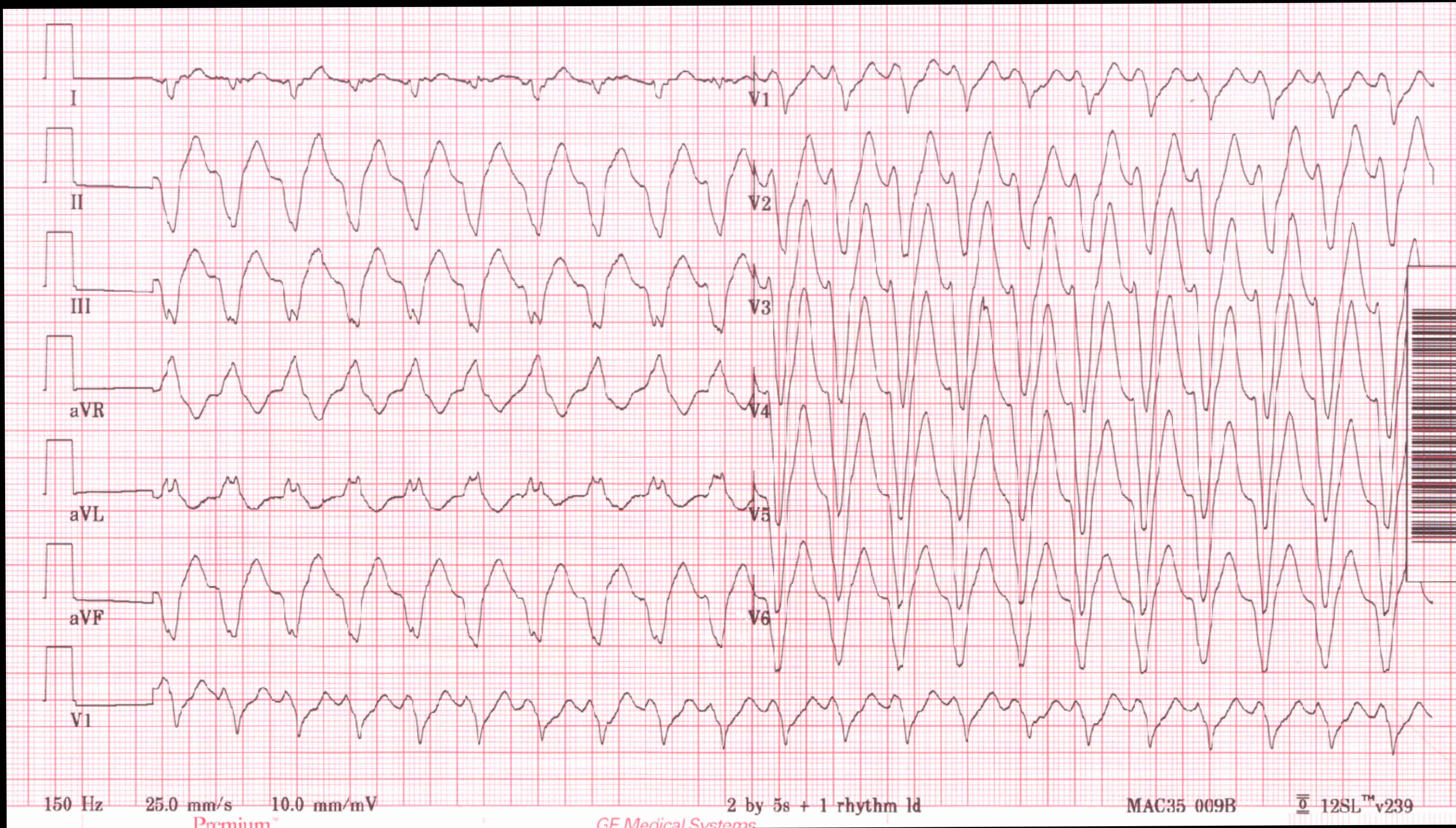
# N-terminal pro-B-type natriuretic peptide-guided therapy in patients hospitalized for acute heart failure

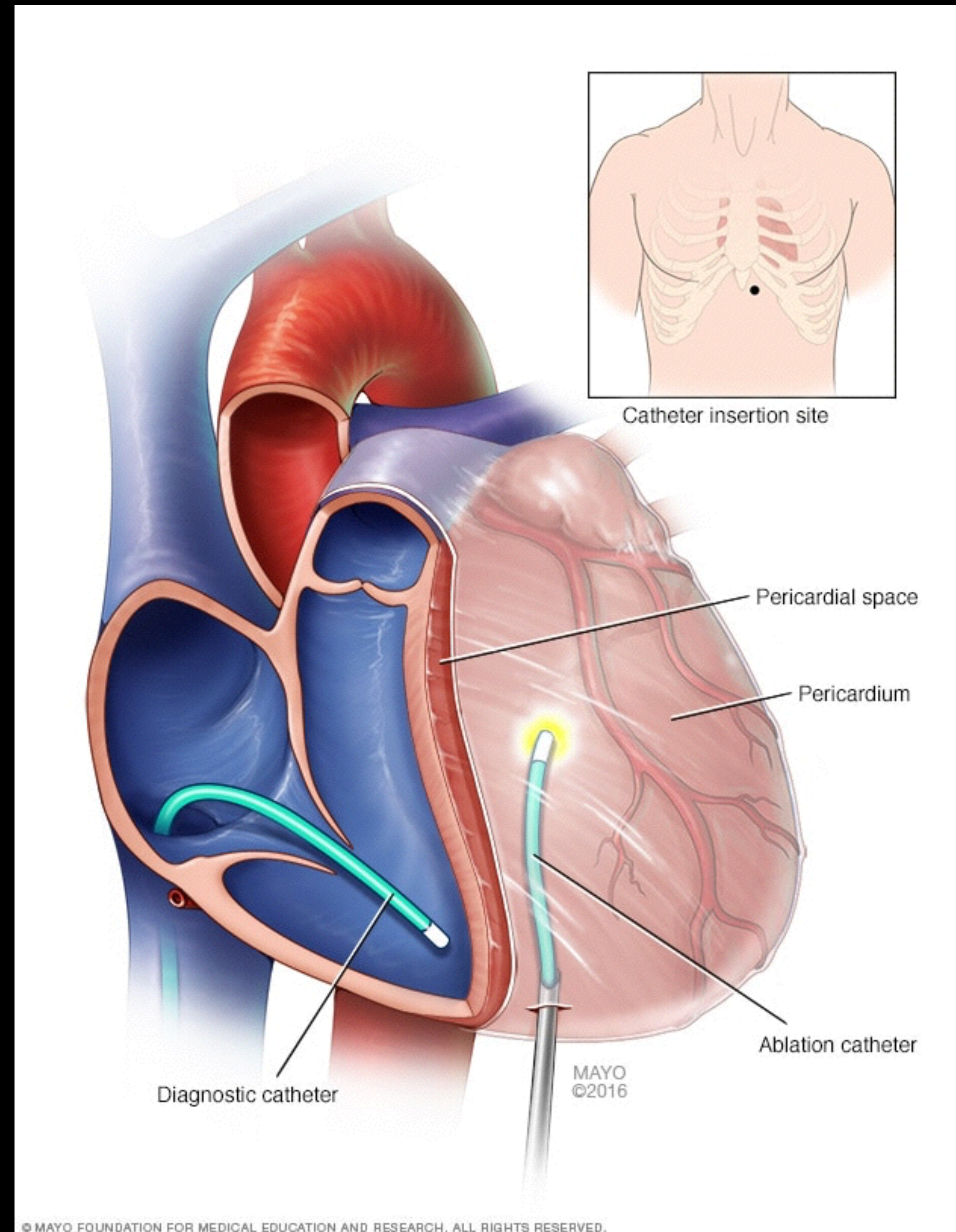


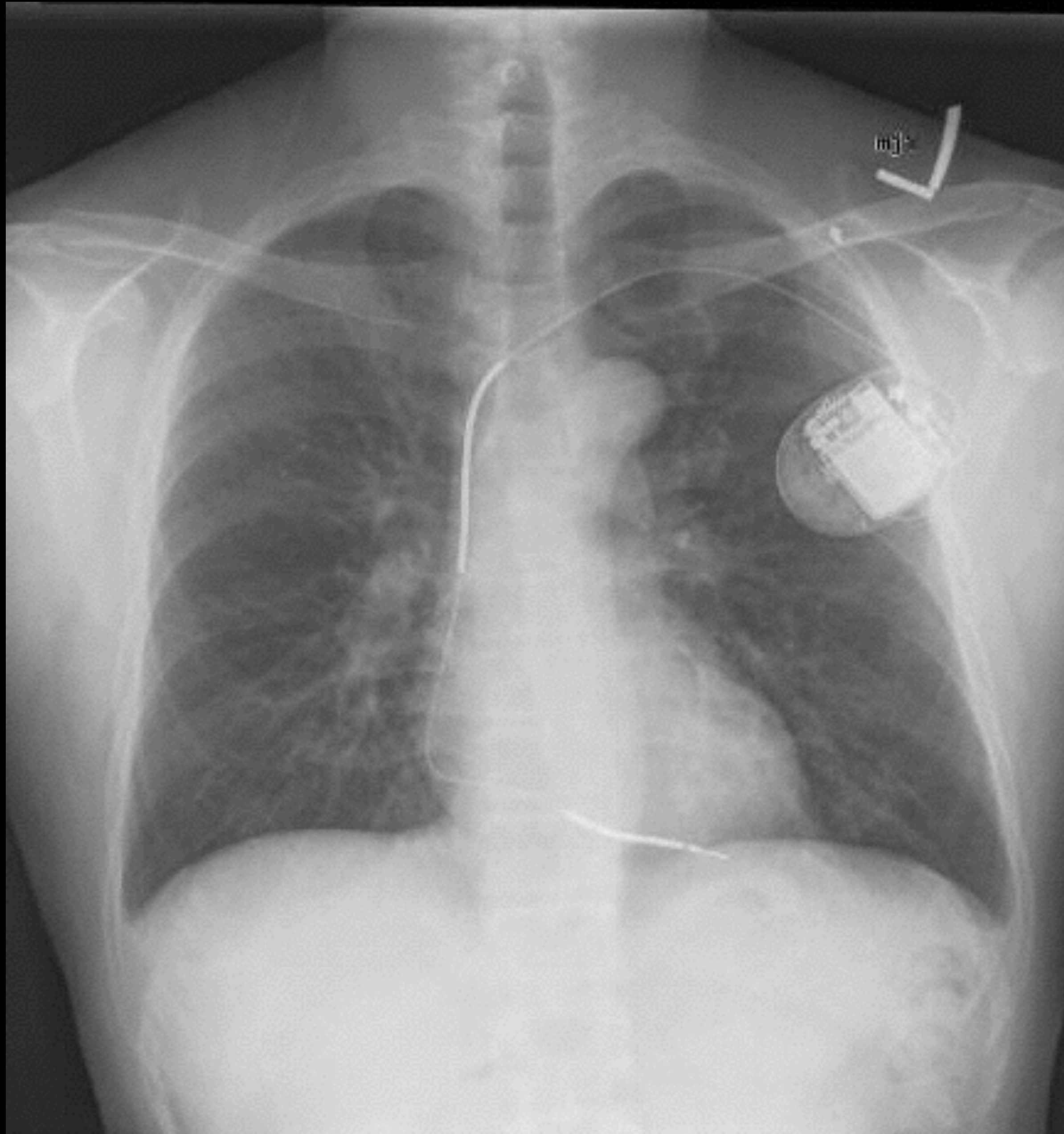
natriuretic peptide levels have prognostic value in patients with acute heart failure, but evidence does not support targeting lower levels as a means of improving outcomes



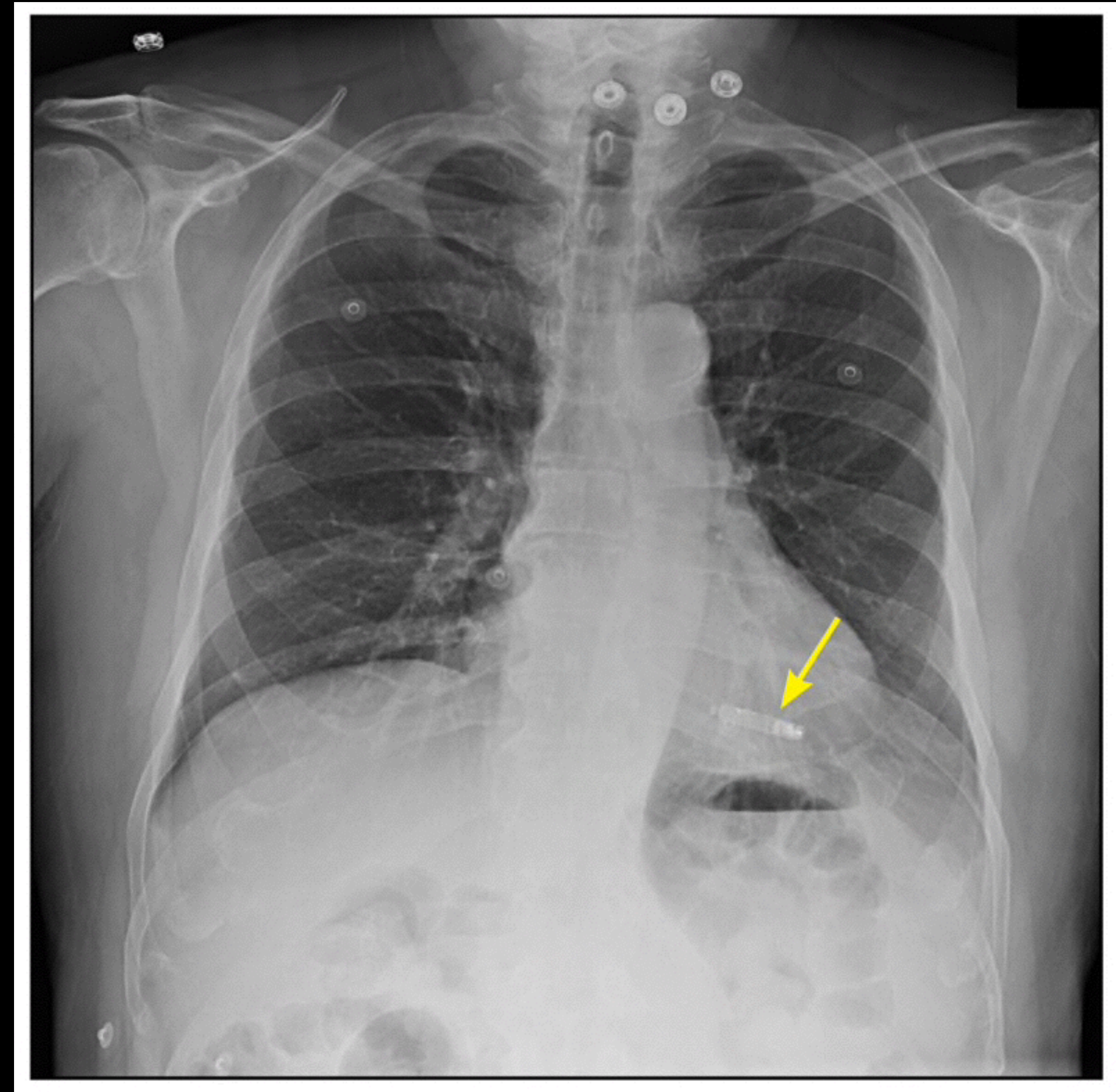
# 12. dan







**ICD**



**Safety of continued versus interrupted DOACs during transvenous CIED implantation (December 2018)**

# PODALJŠANJE TERAPIJE ZA ZMANJŠANJE ATEROTROMBOTIČNIH ZAPLETOV?

Raziskava	*PRODIGY	**DAPT	***PEGASUS	
Številka bolnikov	2012	2061	21162	
Početje DE	<b>Podaljšanje P2Y12 zmanjša pogostost ishemičnih dogodkov, a poveča verjetnost pomembne krvavitve</b>			
Trajanje P2Y12	24 vs 6 mesecev	12 vs 30 mesecev	0 vs 3 leta	
P2Y12	Klopi	Klopi/Prasu	Tika 60mg	Tika 90 mg
MACCE	NS	-1.6%	-1.3%	-1.2%
MI	NS	-2.0%	-0.7%	-0.9%
ST	NS	-1.0%	?	?
Velika krvavitev	+1%	+2.7%	+1.2%	+1.5%
Transfuzija	+1.3%	?	?	?
Dispnoe	-	-	+9.5%	+12.6%
Smrt	NS	+0.5%	NS	NS

\*Valgimigli M, et al. Circulation 2012;125:2015-26

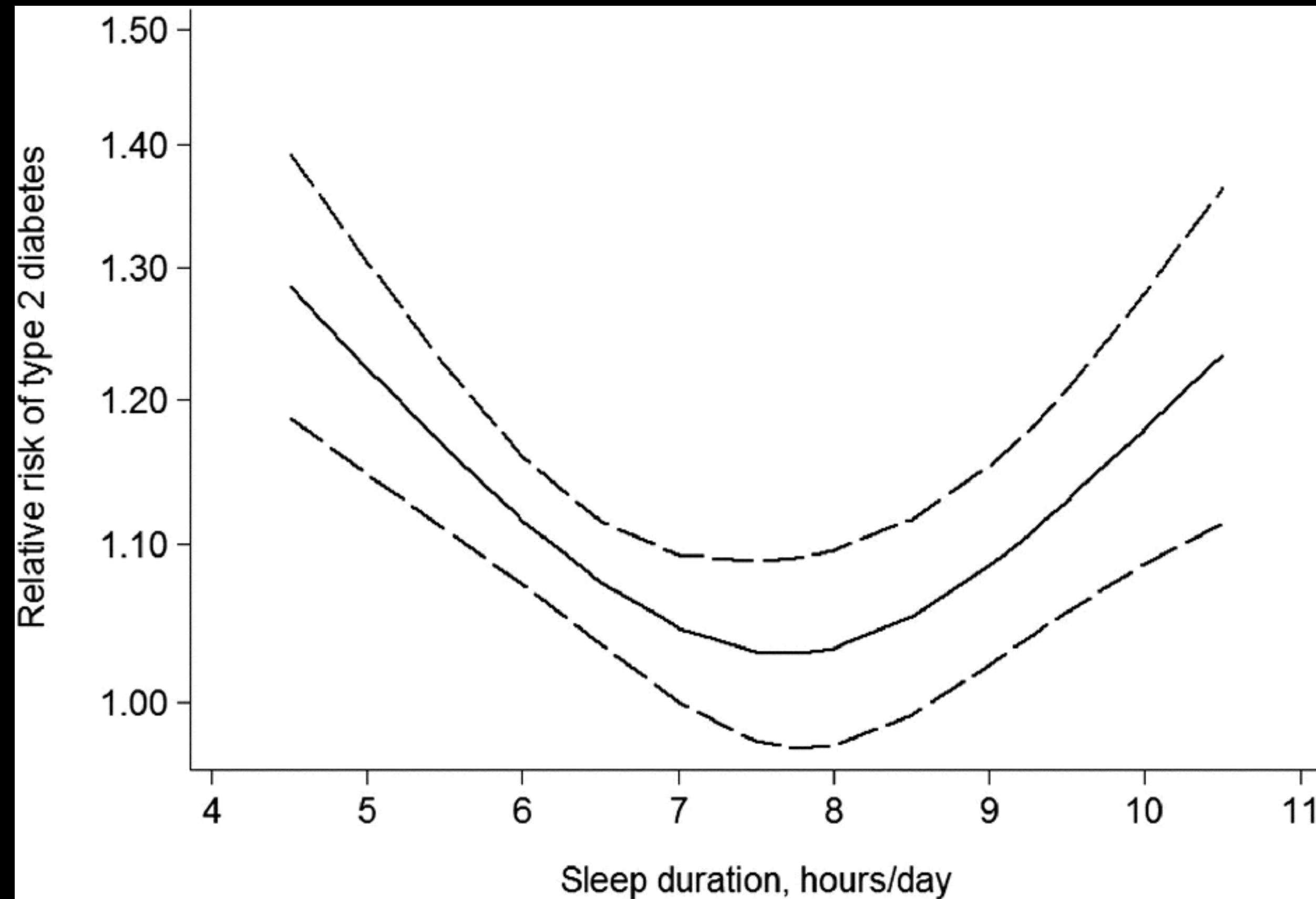
\*\*Mauri L, et al. NEJM 2014;371:2155-66

\*\*\*Bonaca MP, et al. NEJM 2015;372:1791-800



# Sleep Duration and Quality: Impact on Lifestyle Behaviors and Cardiometabolic Health: A Scientific Statement From the American Heart Association

A new scientific statement from the American Heart Association reviews data linking sleep restriction with adverse cardiometabolic outcomes and recommends that healthy sleep behavior be addressed in public health campaigns to promote ideal cardiac health, alongside blood pressure, cholesterol, diet, blood glucose, physical activity, weight, and smoking cessation



**VSAKA IMA Sun  
mix**



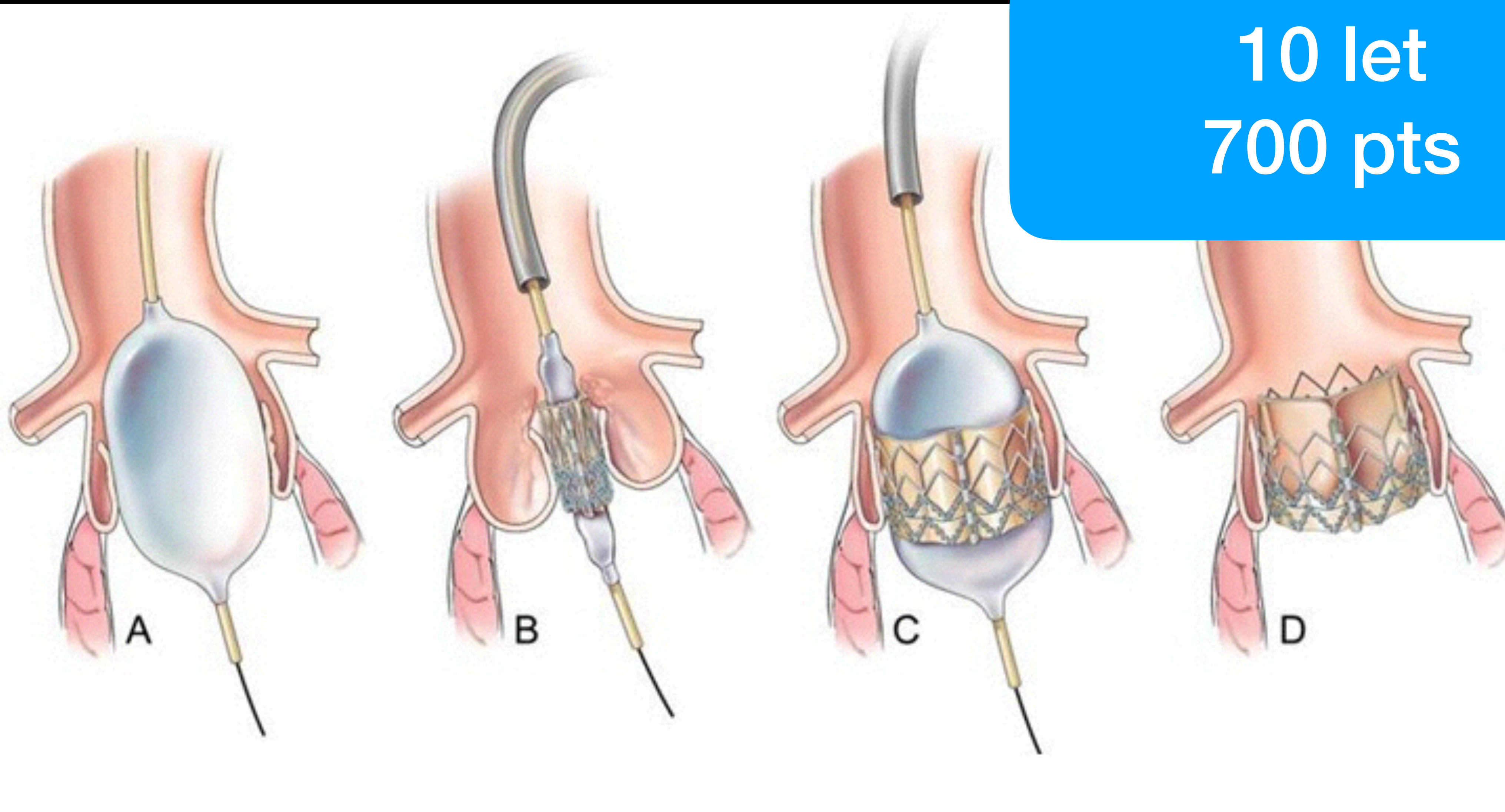
**Sun  
mix SVOJ FAKTOR**

© 2004 VOGUE ITALIA



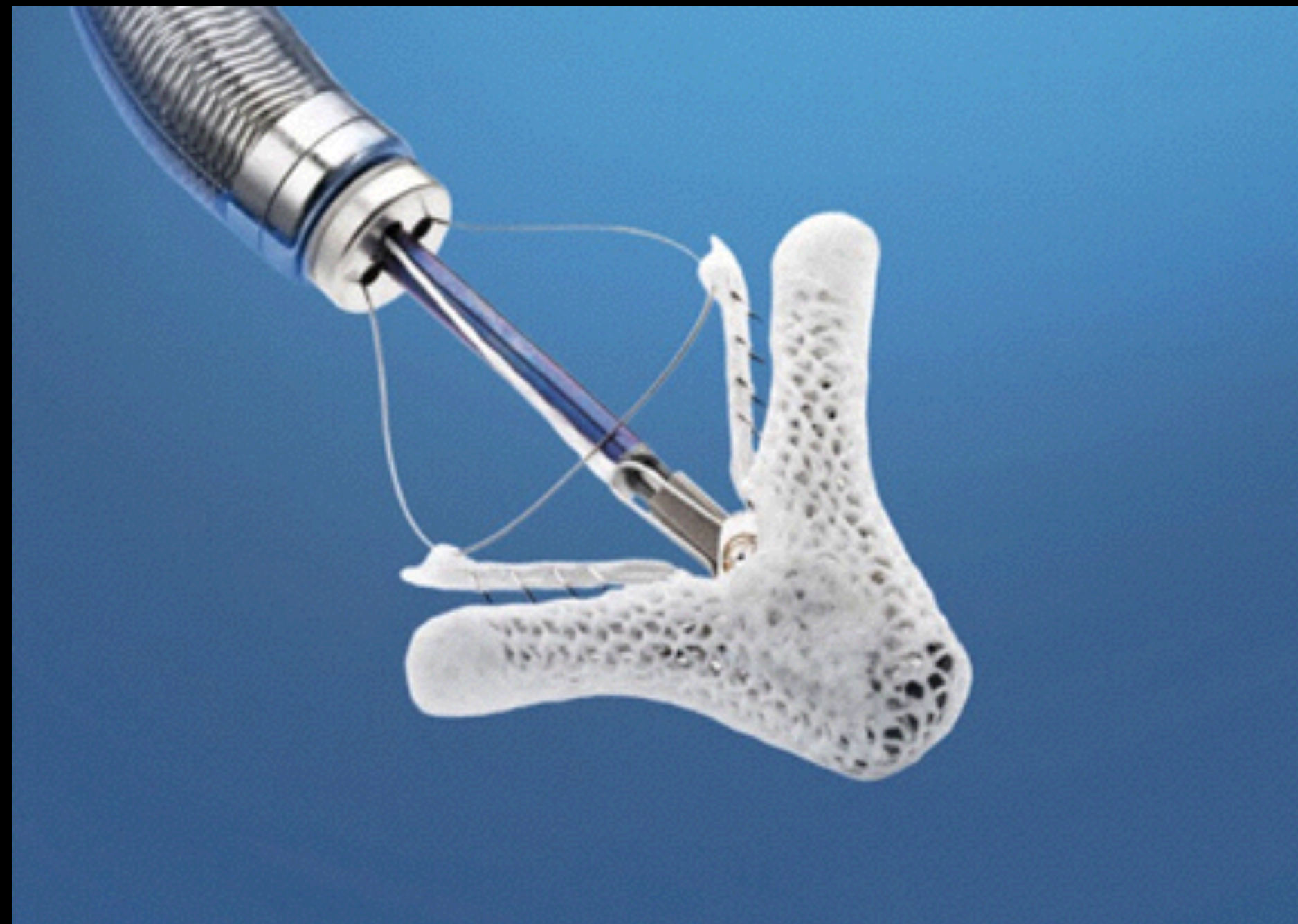
# TAVI

10 let  
700 pts

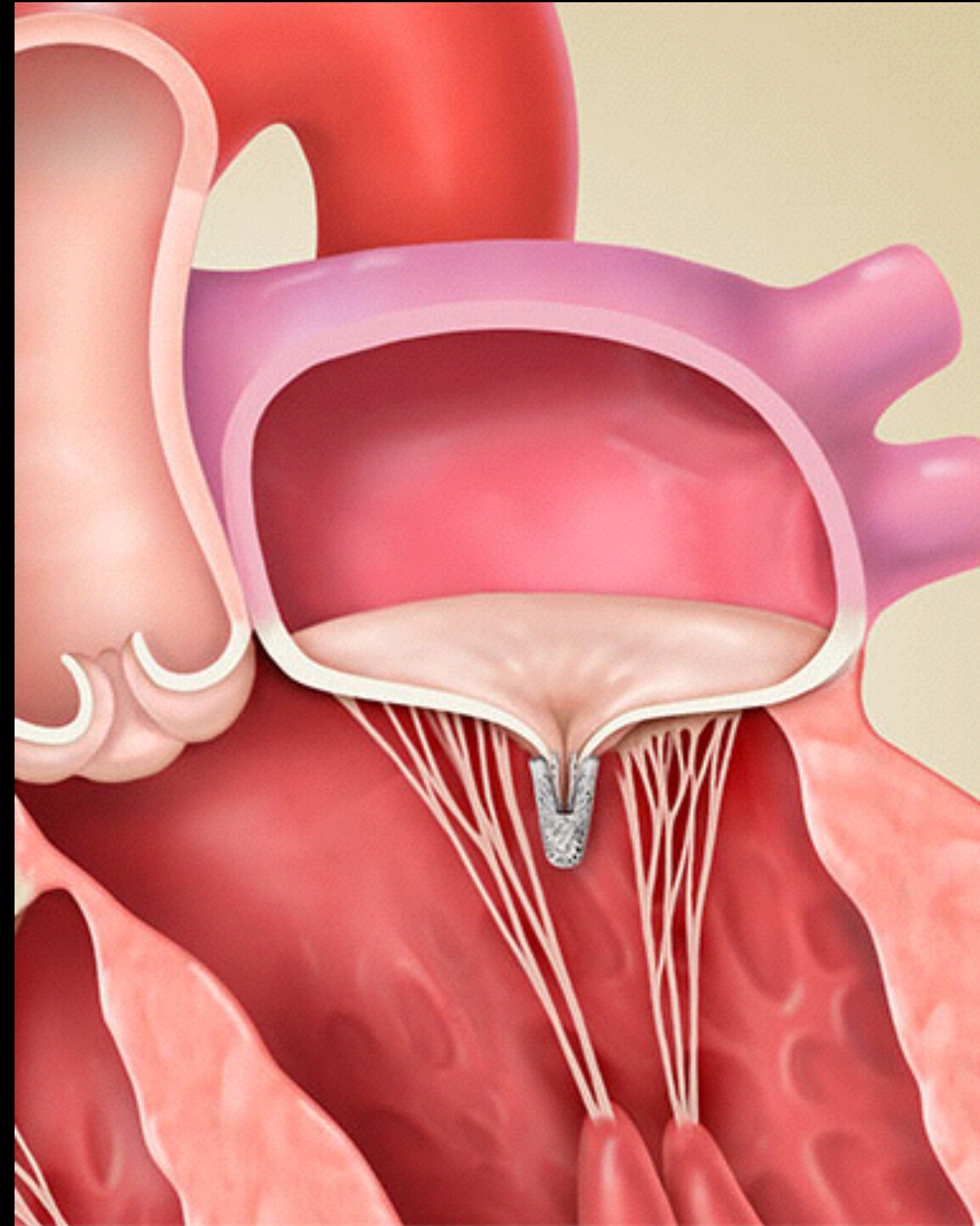


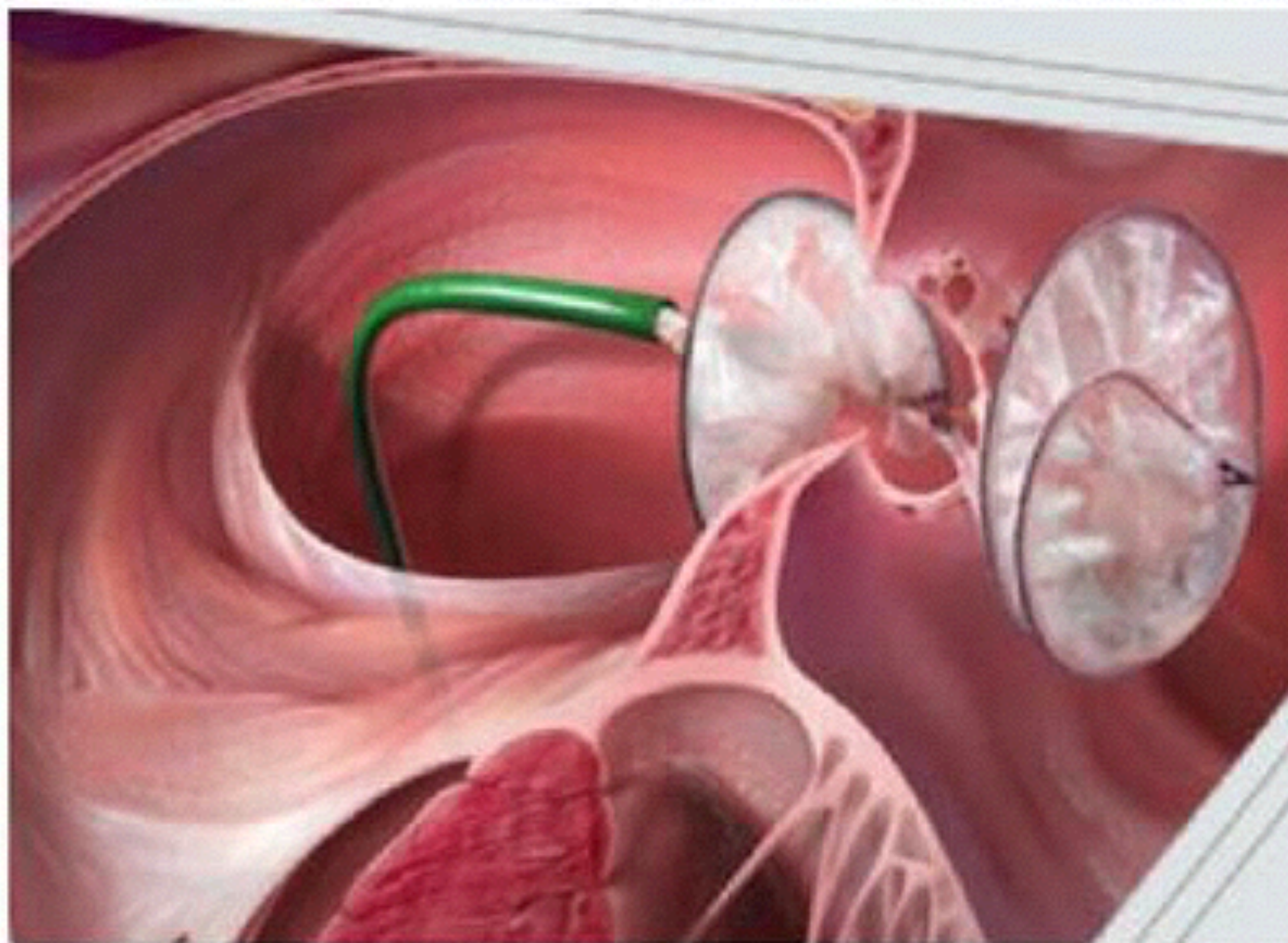
visoko tveganje + srednje tveganje za kirurgijo

# Mitraclip



samo ozko selekcionirani bolniki

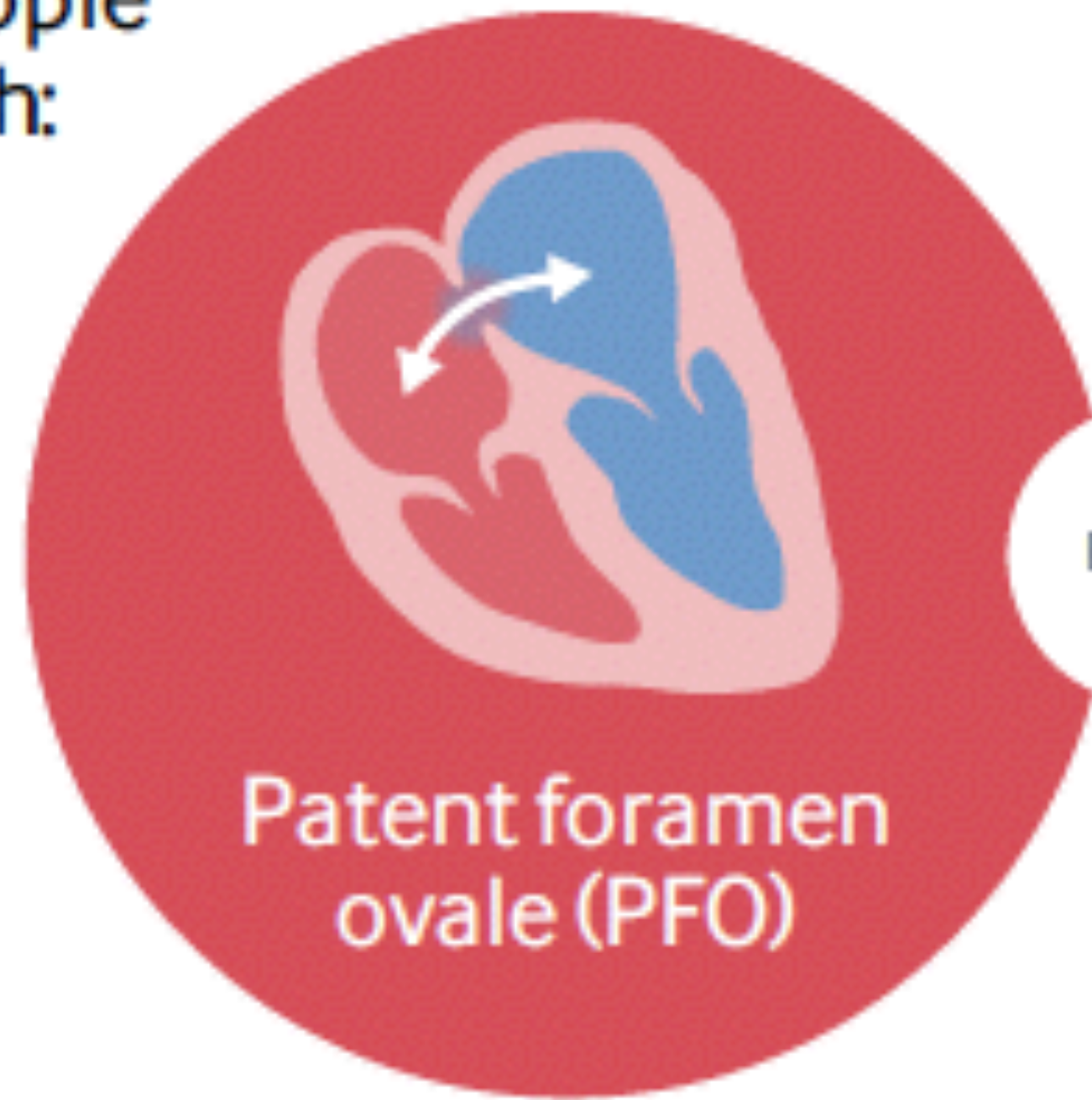




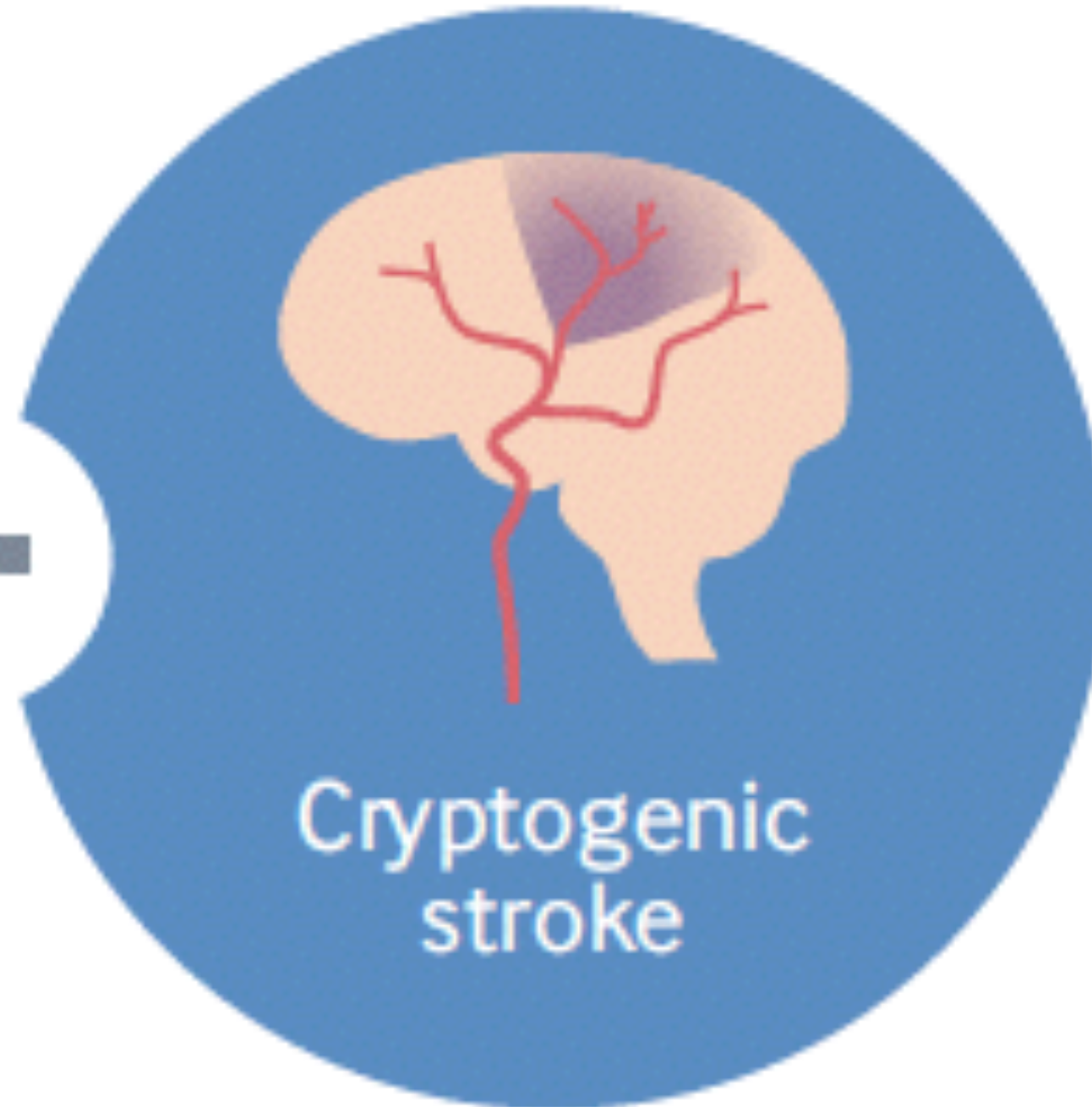
**PFO CLOSURE  
DEVICE**

# Population

People  
with:



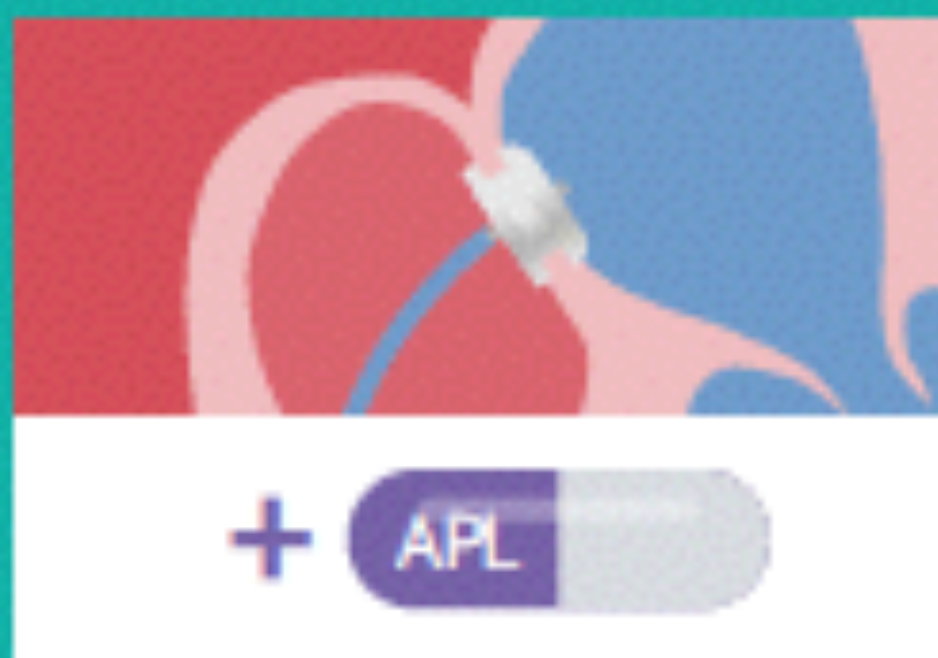+



- No atrial fibrillation
- No aortic disease
- No left sided heart disease
- No cerebrovascular disease

## PFO closure

Percutaneous closure of PFO followed by antiplatelet therapy



OR

## Anticoagulants

Anticoagulation therapy



**PFO closure**

**Anticoagulants**

Strong <sup>i</sup>

Weak <sup>i</sup>

Weak <sup>i</sup>

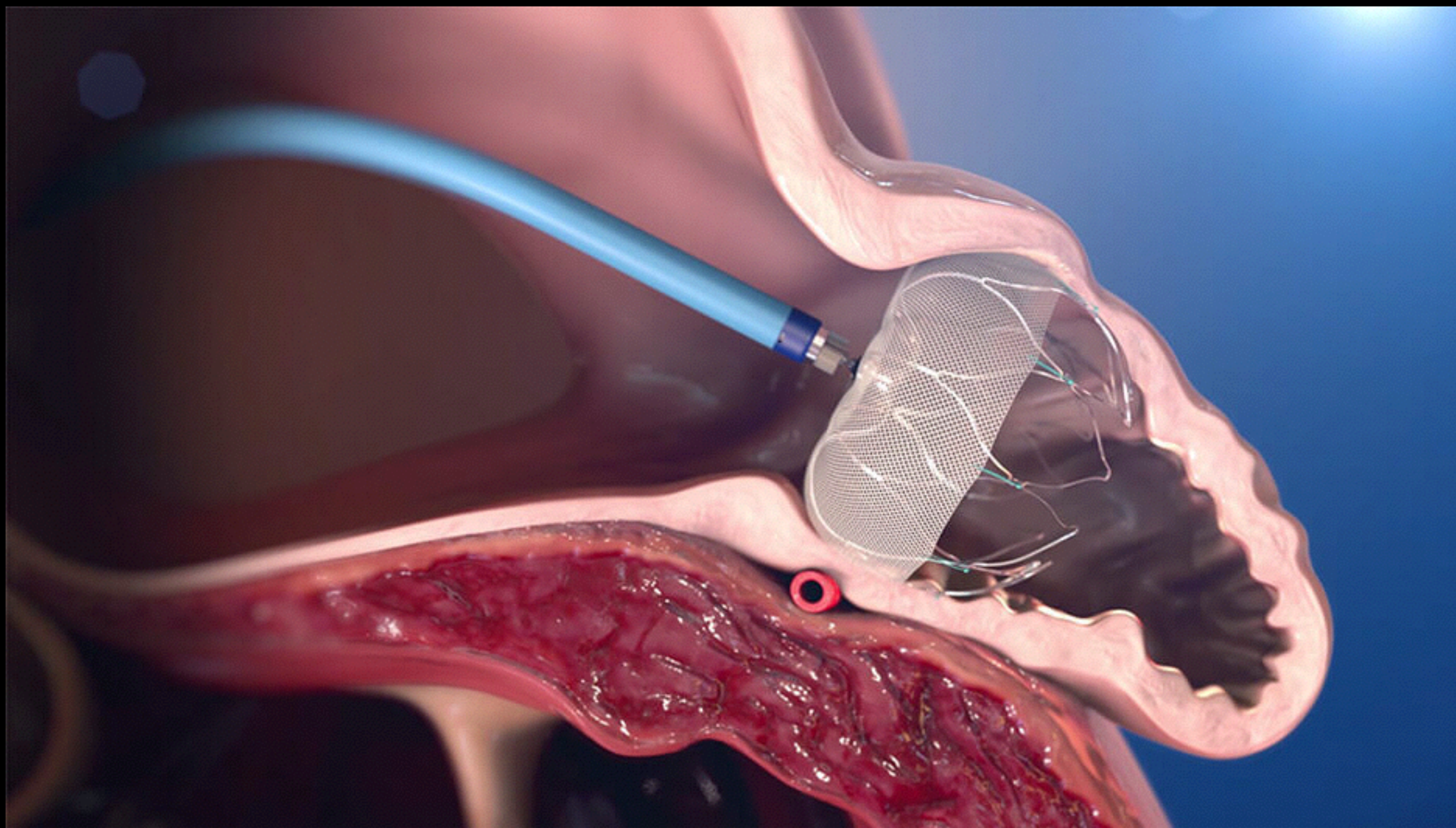
Strong <sup>i</sup>

More details

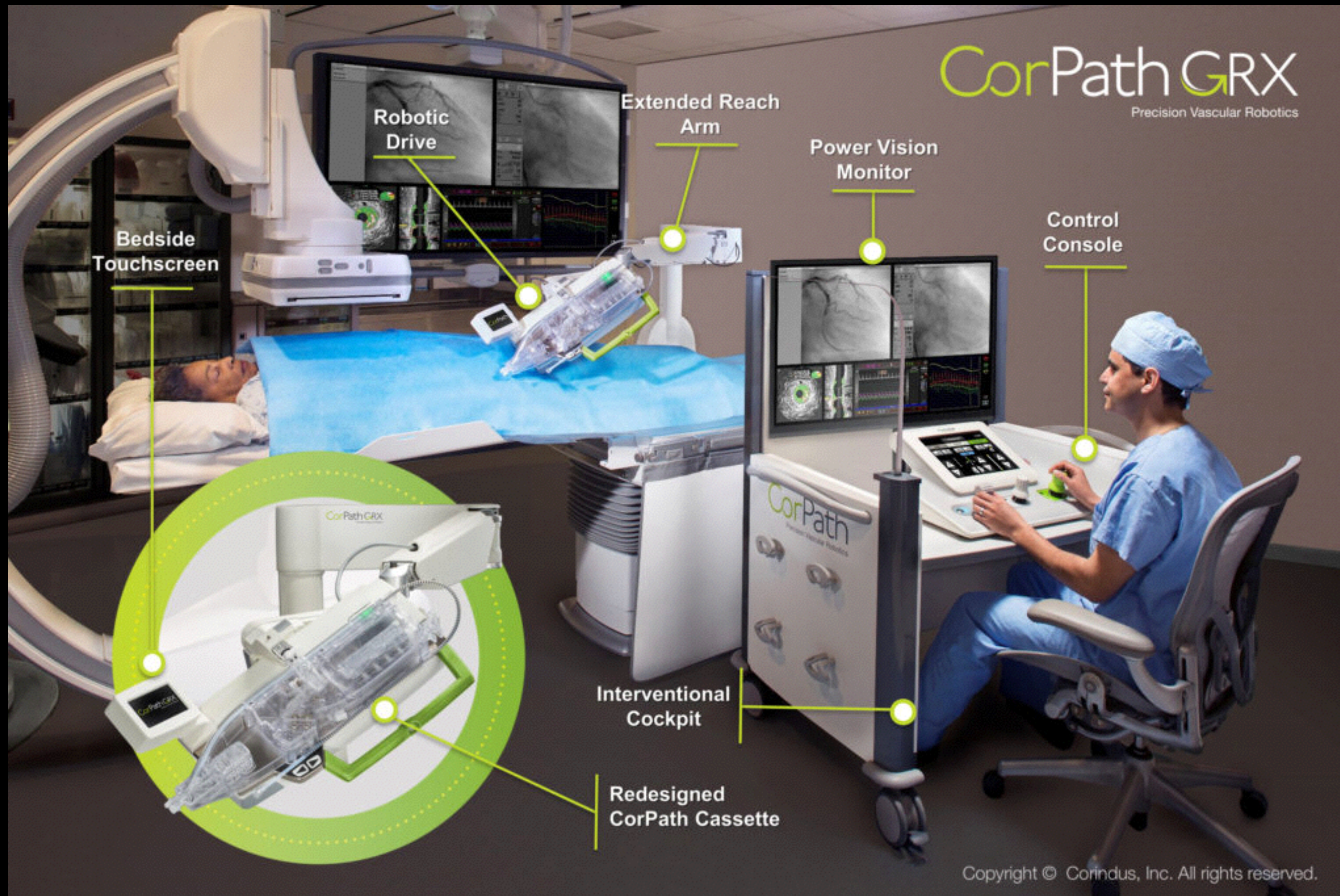


We suggest PFO closure followed by antiplatelet therapy over anticoagulation therapy. Discuss both options with each patient.

# Zapiranje avrikule levega preddvora



# Na daljavo vodena robotska PCI

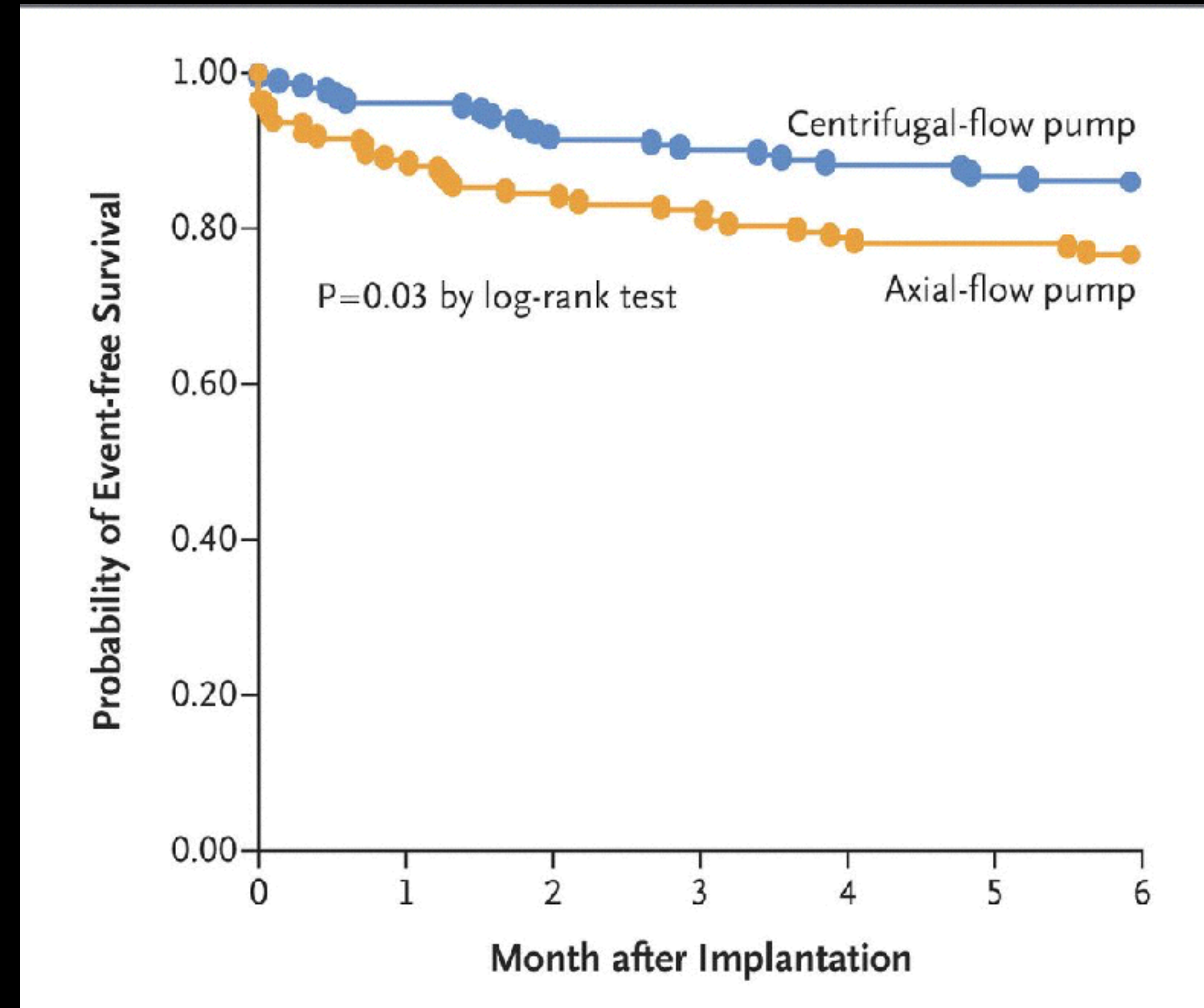
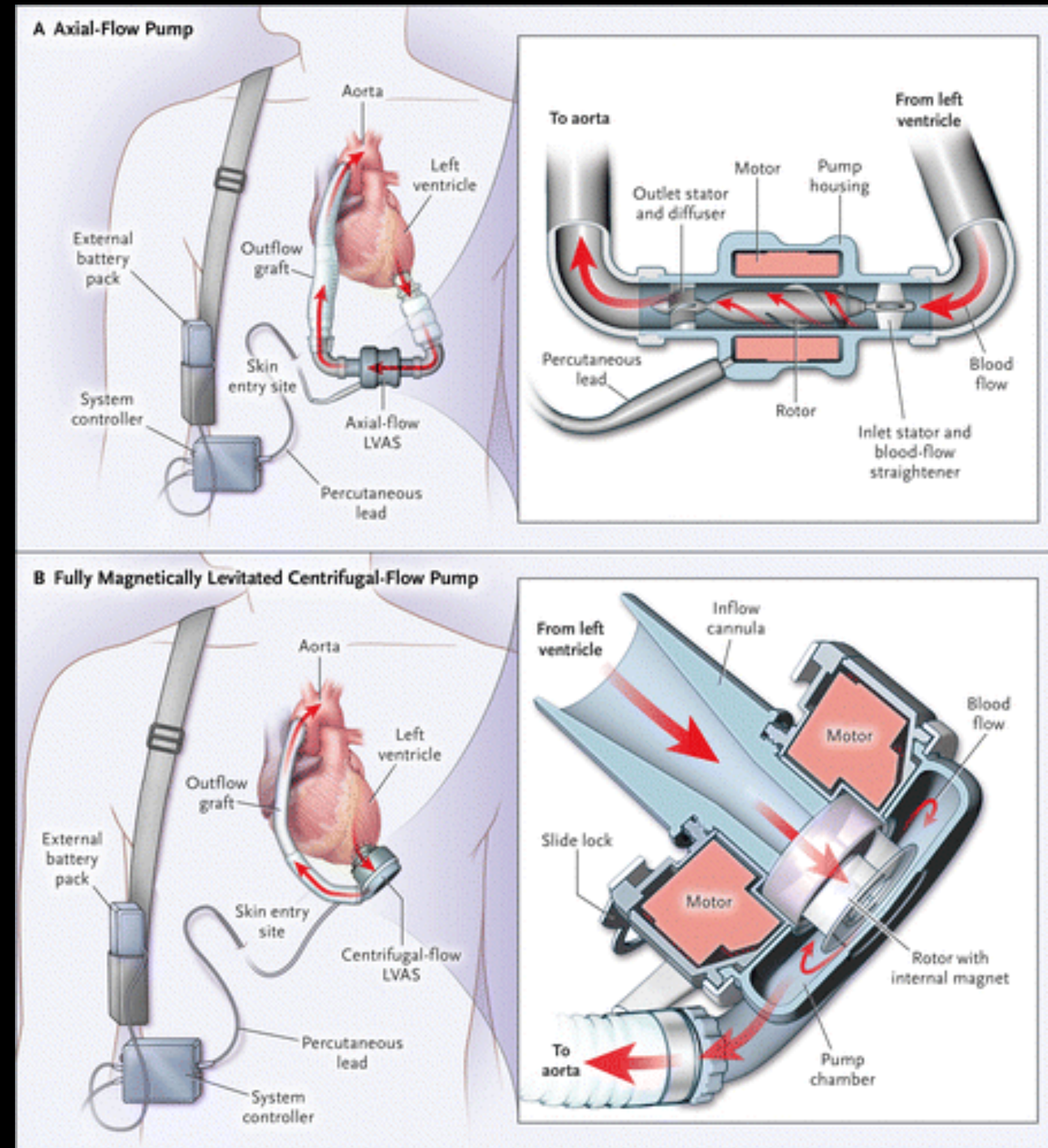


- nič / malo sevanja za operaterja
- manj poškodb hrbtenice
- delo na daljavo



- visoka cena
- 2 operaterja
- “haptičnost”
- zaupanje bolika

## A Fully Magnetically Levitated Circulatory Pump for Advanced Heart Failure



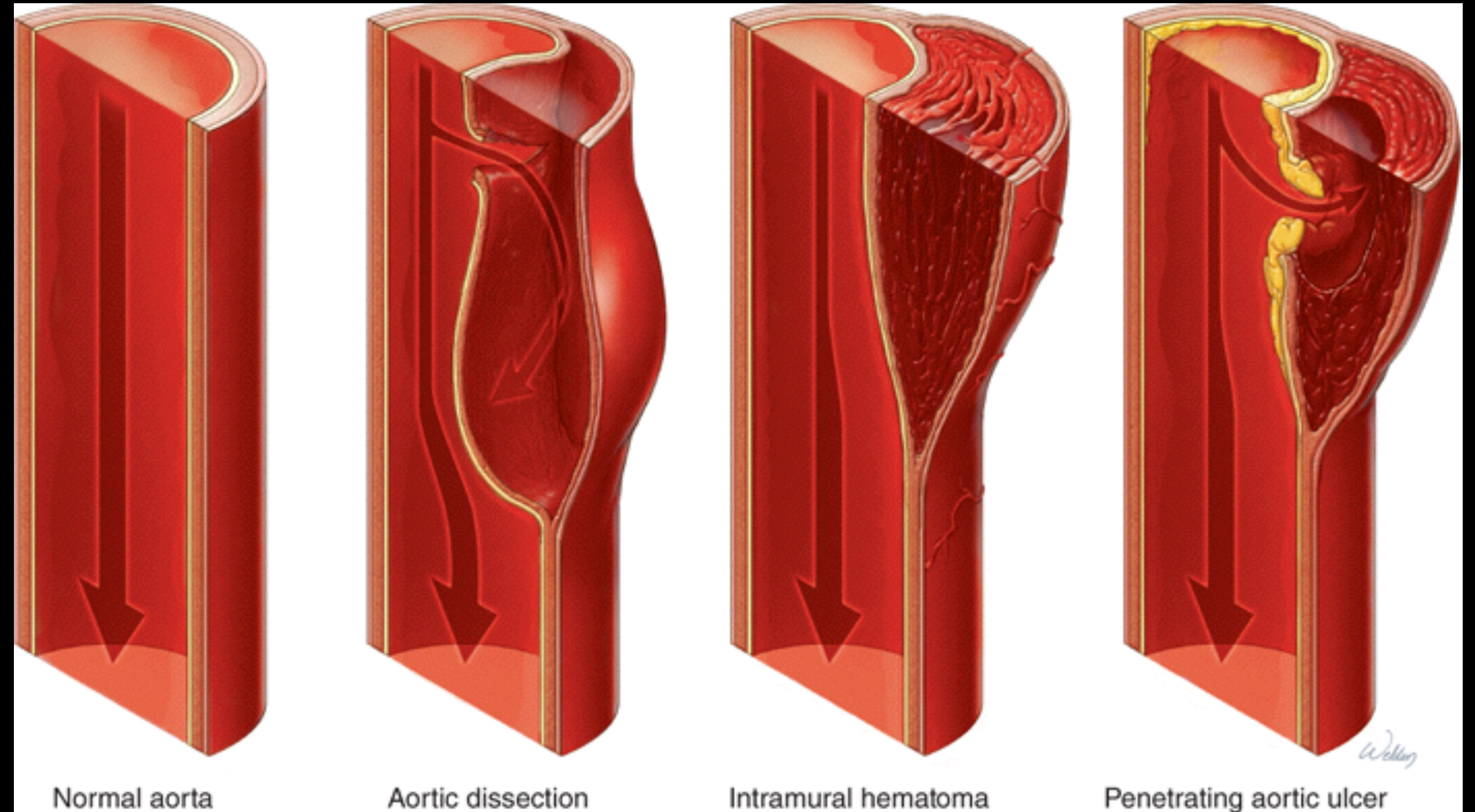
Among patients with advanced heart failure, implantation of a fully magnetically levitated centrifugal-flow pump was associated with better outcomes at 6 months than was implantation of an axial-flow pump, primarily because of the lower rate of reoperation for pump malfunction.



# florokinoloni !

## FDA Black Box Warning

A black box warning is the strongest warning issued by the FDA pertaining to particularly strong adverse effects caused by a pharmaceutical. A black box warning is the toughest step taken by the FDA short of removing a drug from the market.





# **AKUTNA KARDIOLOGIJA V SLOVENIJI**

**ZDRAVNIŠKA ZBORNICA, 3.4.2020**